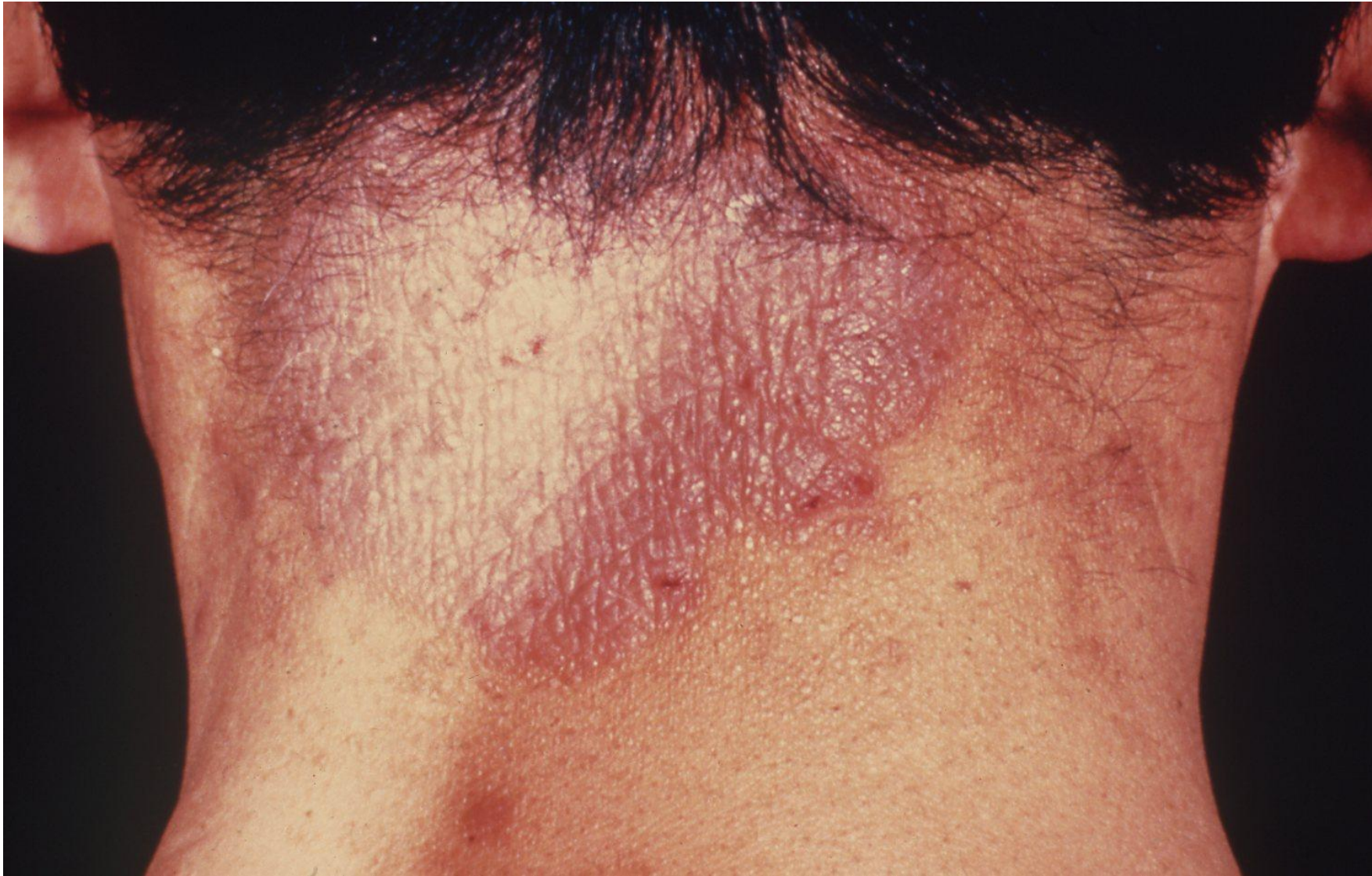


# Lichen Vidal (lichen simplex chronicus)

Lichen Vidal (lichen simplex chronicus) is a type of chronic eczema with intense itching and thickening of the skin. It presents as solitary, well-defined patches, red or grayish in color with or without scaly appearance. Verrucous appearance and melanin pigmentation may be associated.

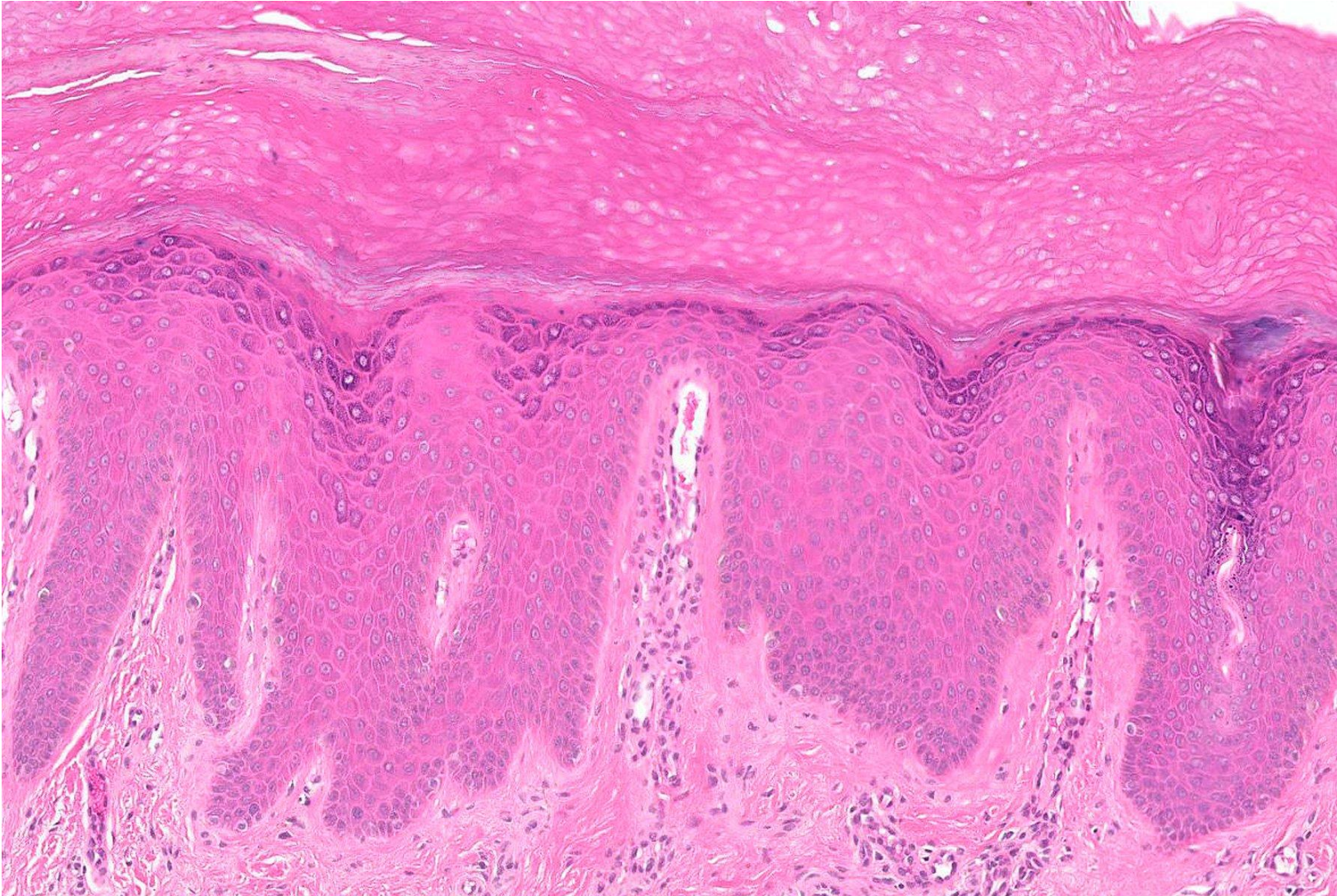
Lichen Vidal is most commonly seen in the neck, genital area and upper arms of middle-aged women. Treatments include topical corticosteroids and oral antihistamines to alleviate itching. The etiology may be related to psychological stress and environmental factors such as temperature extremes and exposure to irritants.

Ref.: Juarez MC, Kwatra SG. A systematic review of evidence-based treatments for lichen simplex chronicus. *J Dermatolog Treat* 2021; 32(7): 684-692. doi: 10.1080/09546634.2019.1708856



Lichen Vidal (lichen simplex chronicus) seen on the neck of a female patient aged 40's. It presents with a reddish-colored solitary, well-defined pruritic patch.





Lichen Vidal (lichen simplex chronicus) seen on the neck of a female patient aged 40's. Chronic eczematous reactions are seen, including acanthosis with elongation and widening of the rete ridges, hypergranulosis and hyperkeratosis. The papillary dermis reveals mild perivascular lymphocytic infiltration (H&E).