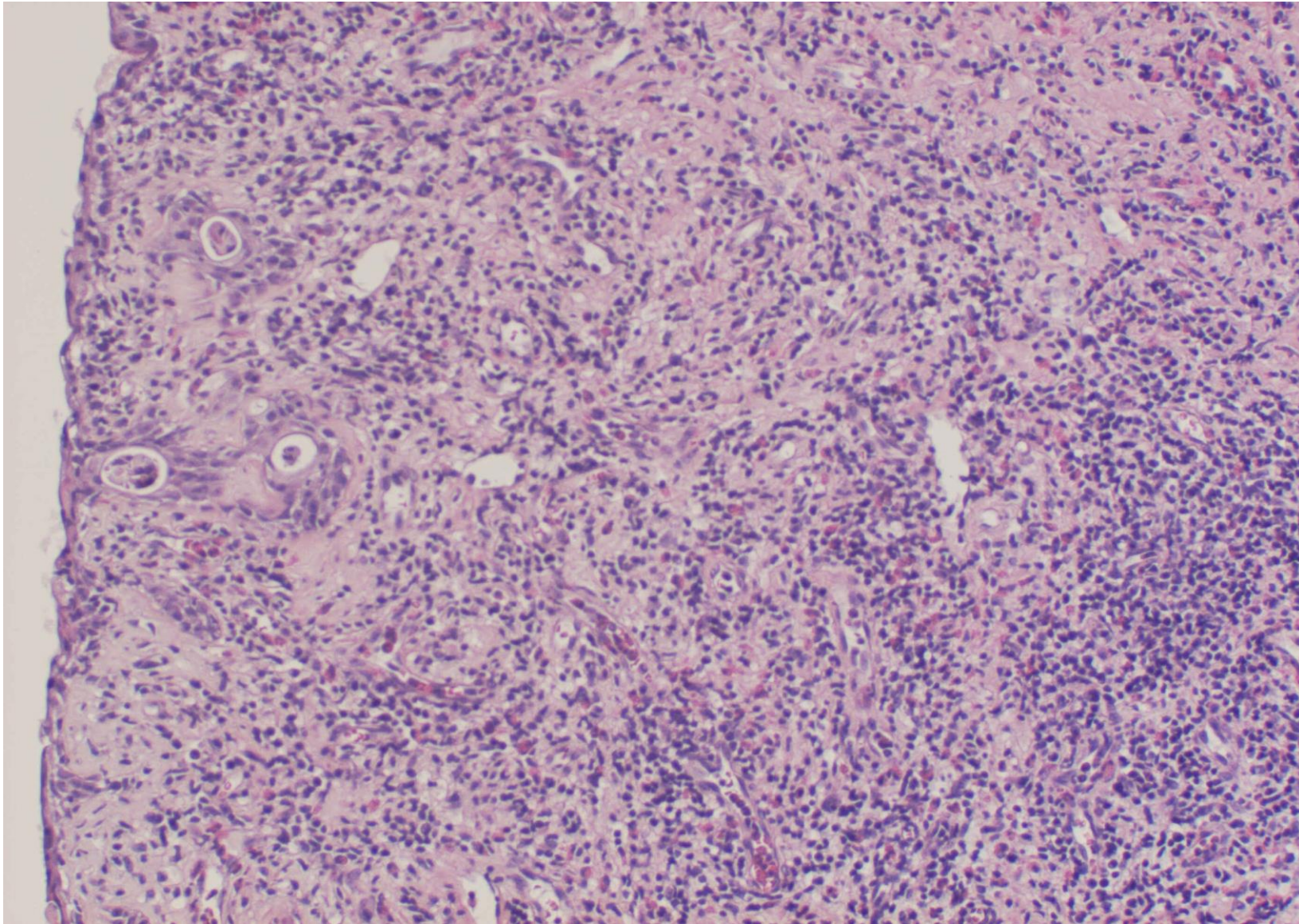
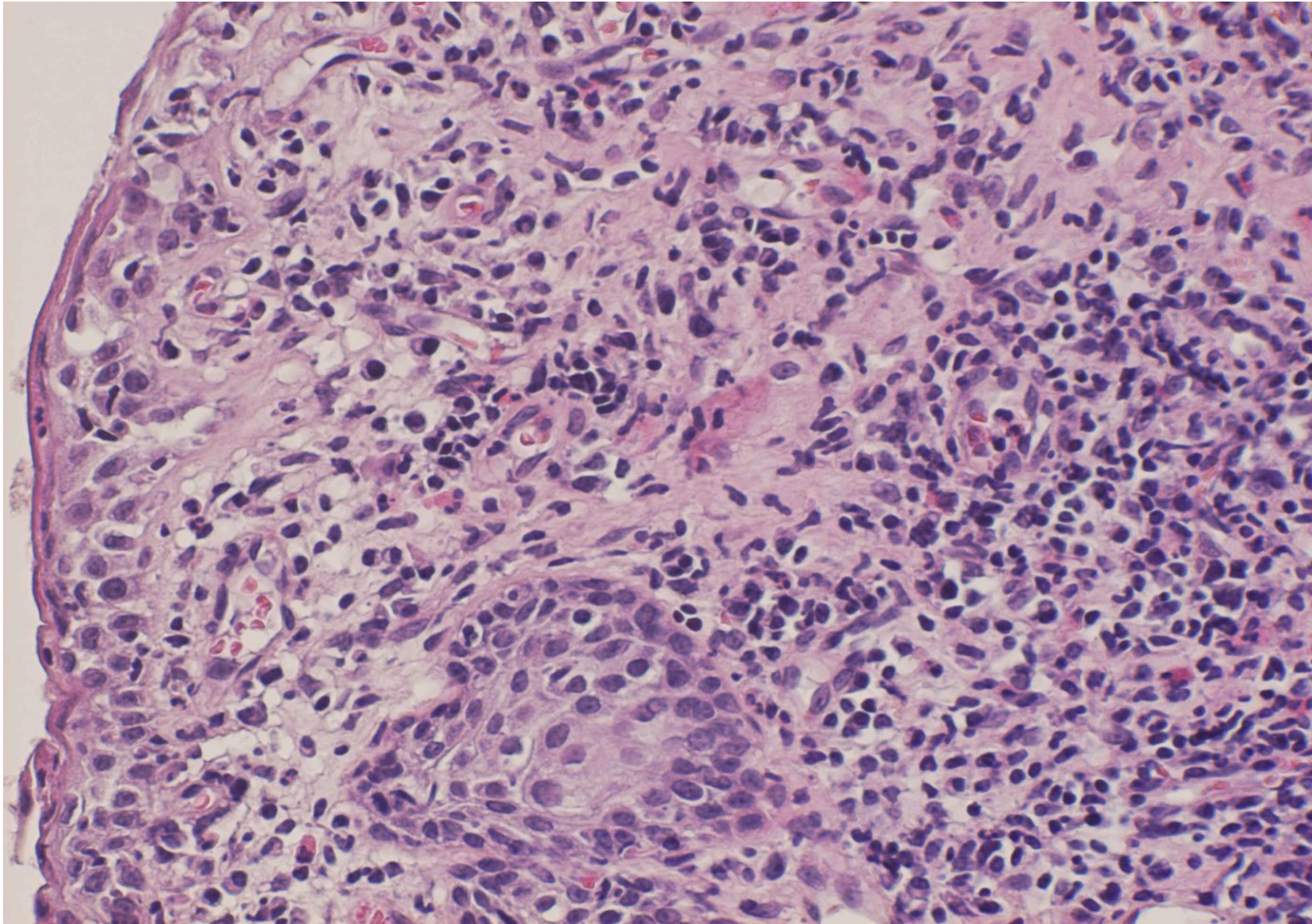


vernal conjunctivitis with eosinophilia (11M)

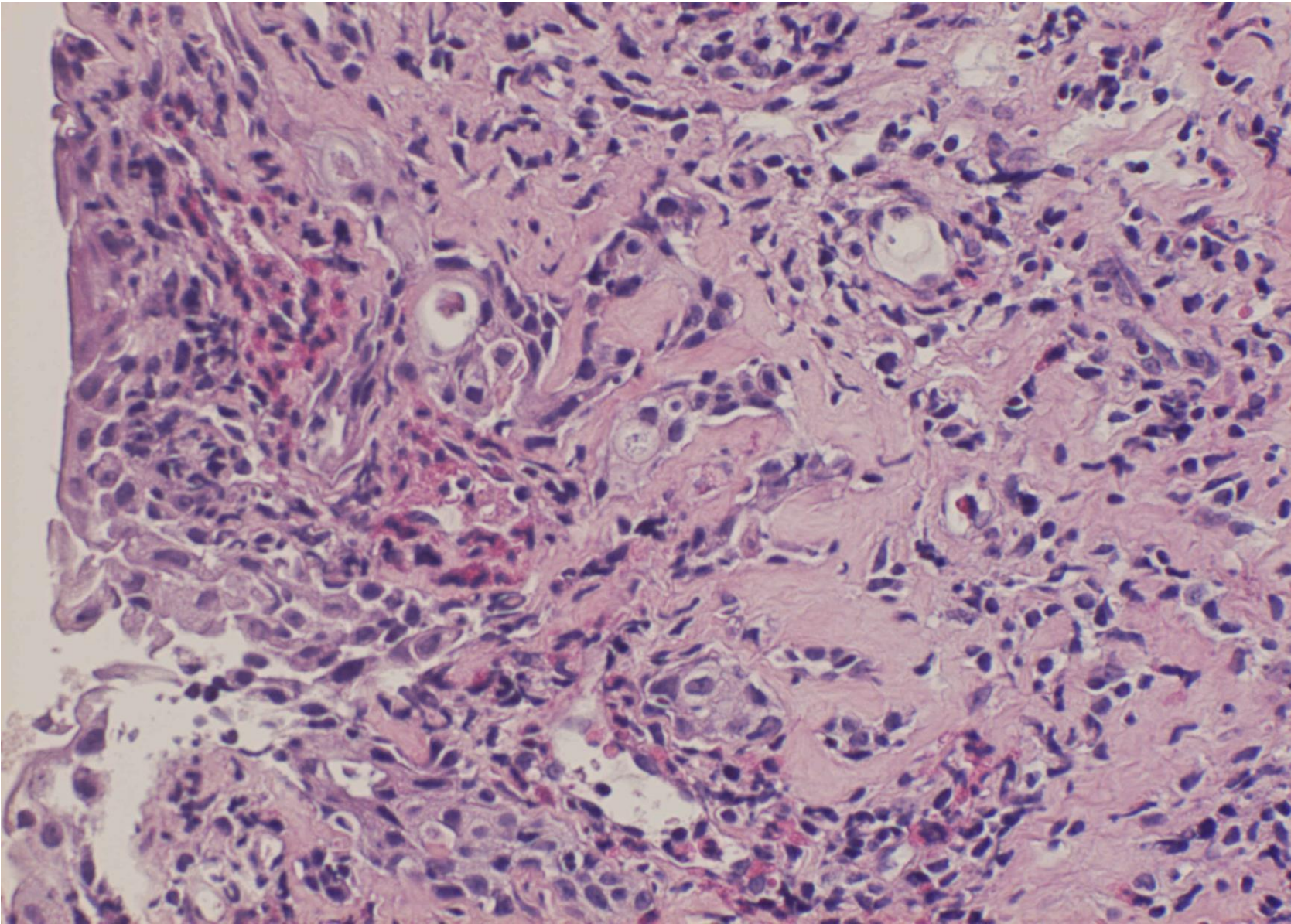
Vernal conjunctivitis is a severe form of allergic conjunctivitis often seen in boys aged around 10 years. The patient is allergic to house dust or pollen. Eosinophilic infiltration is evident. The condition is often associated with atopic dermatitis.



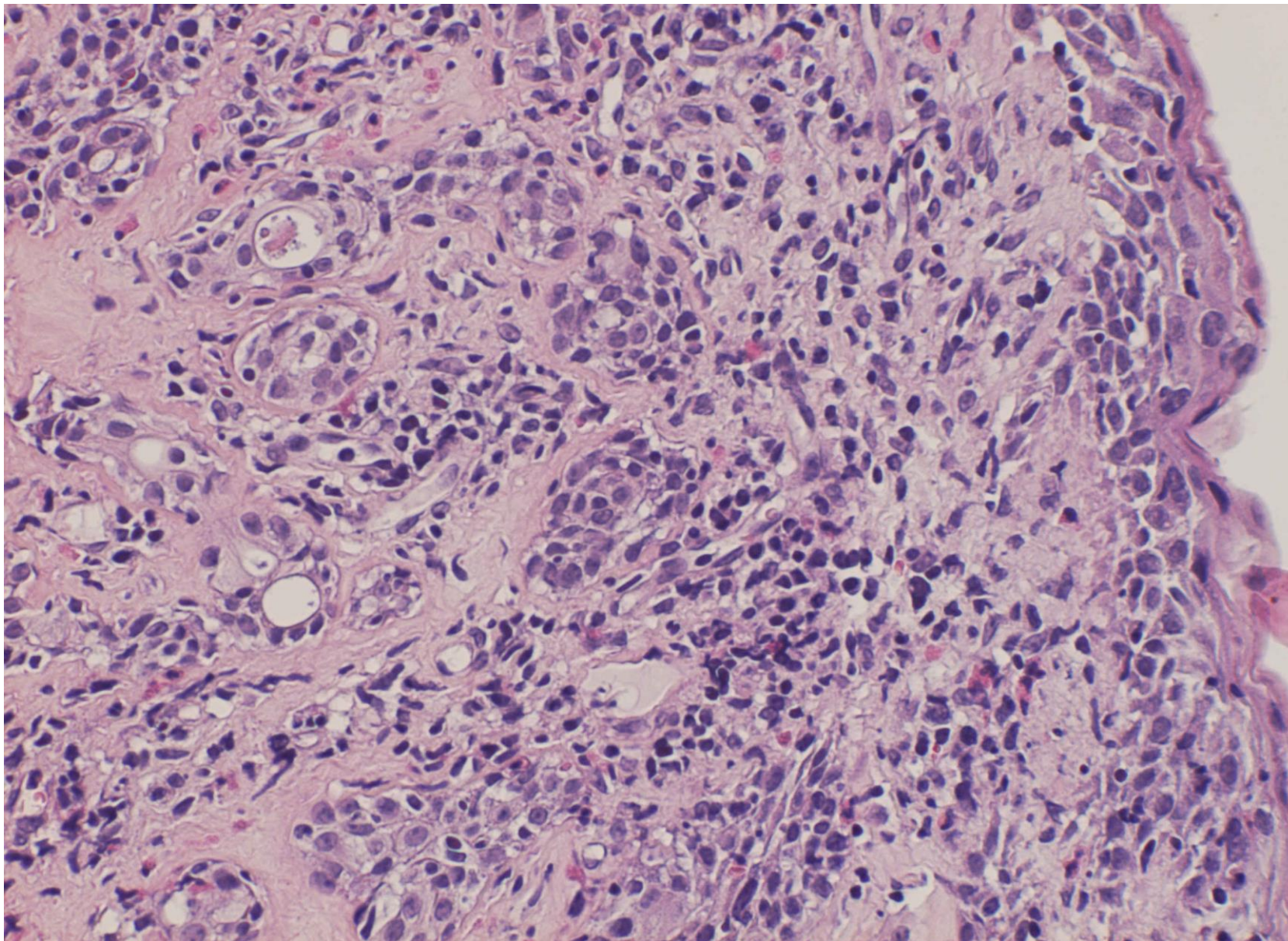
vernal conjunctivitis with eosinophilia (11M), HE-1



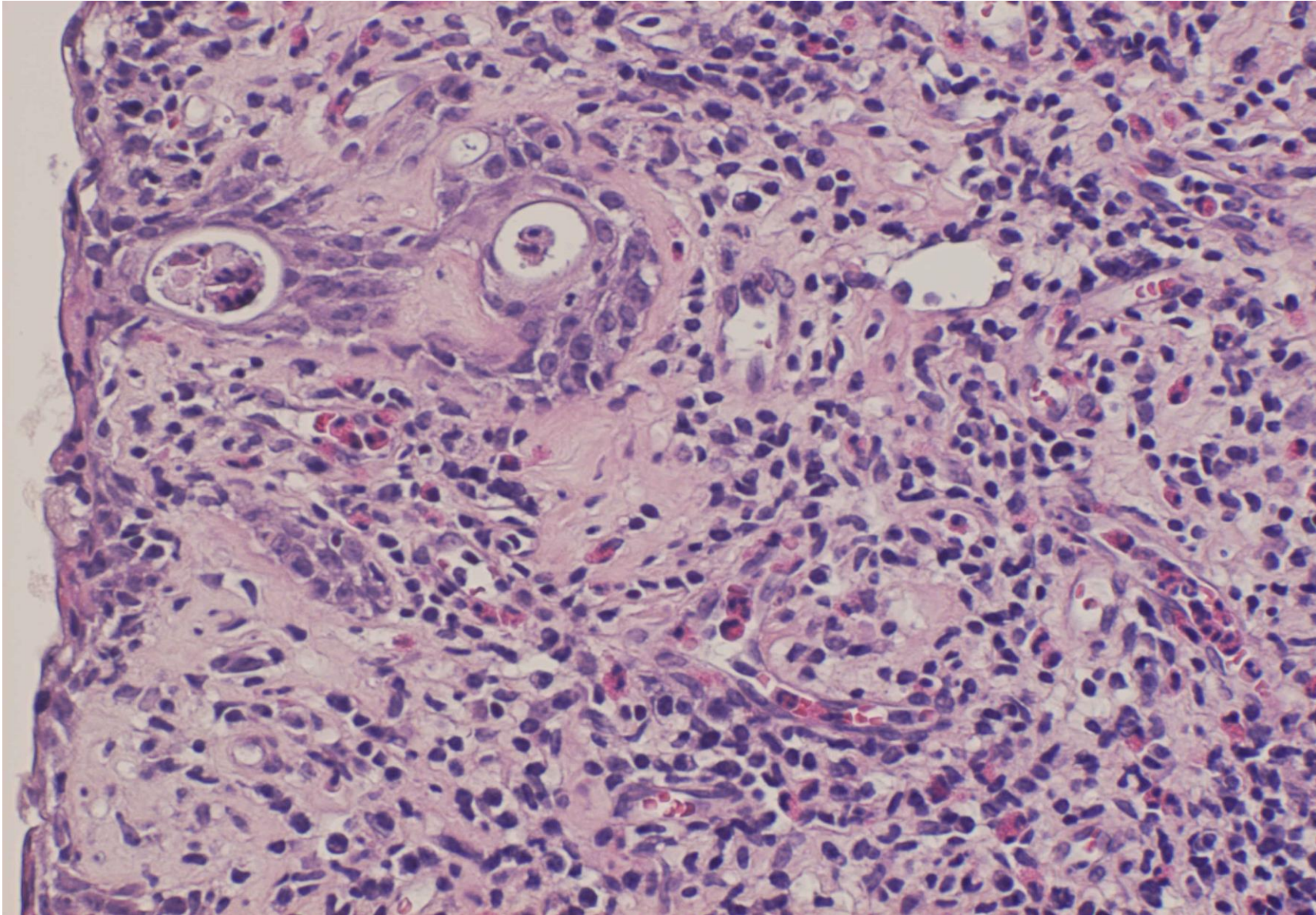
vernal conjunctivitis with eosinophilia (11M), HE-2



vernal conjunctivitis with eosinophilia (11M), HE-3



vernal conjunctivitis with eosinophilia (11M), HE-4



vernal conjunctivitis with eosinophilia (11M), HE-5