Electron micrographs of hematopoietic cells and their neoplasms

Fine structures of hematopoietic cells and their neoplasm are demonstrated below. Features of scanning EM and immunoelectron microscopy (pre-embedding method) are shown on demand. Enjoy the EM world.

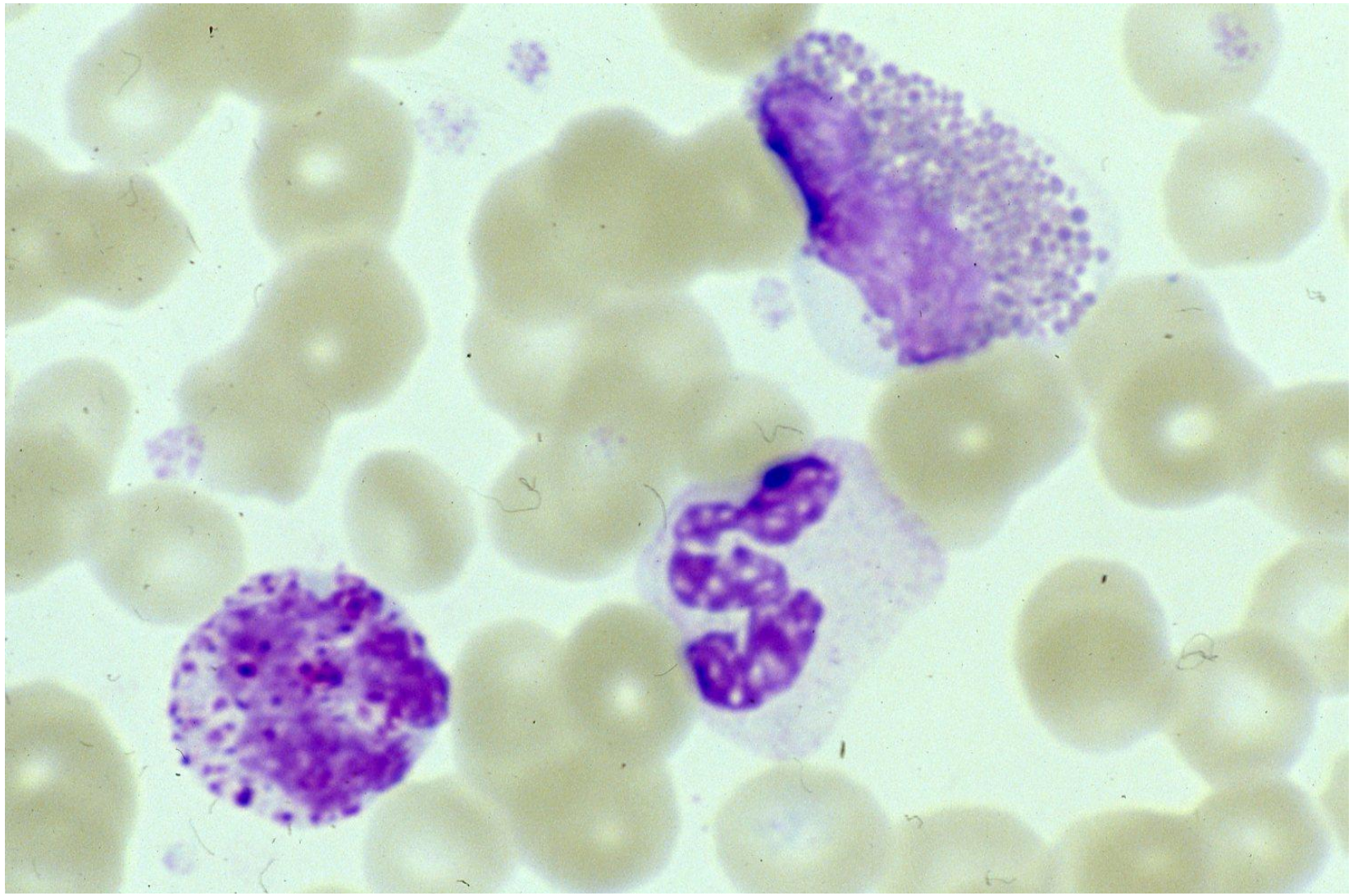

Three kinds of granulocytes in one slide (bone marrow smear, May-Giemsa).
Basophil (left), neutrophil (center) and eosinophil (right).

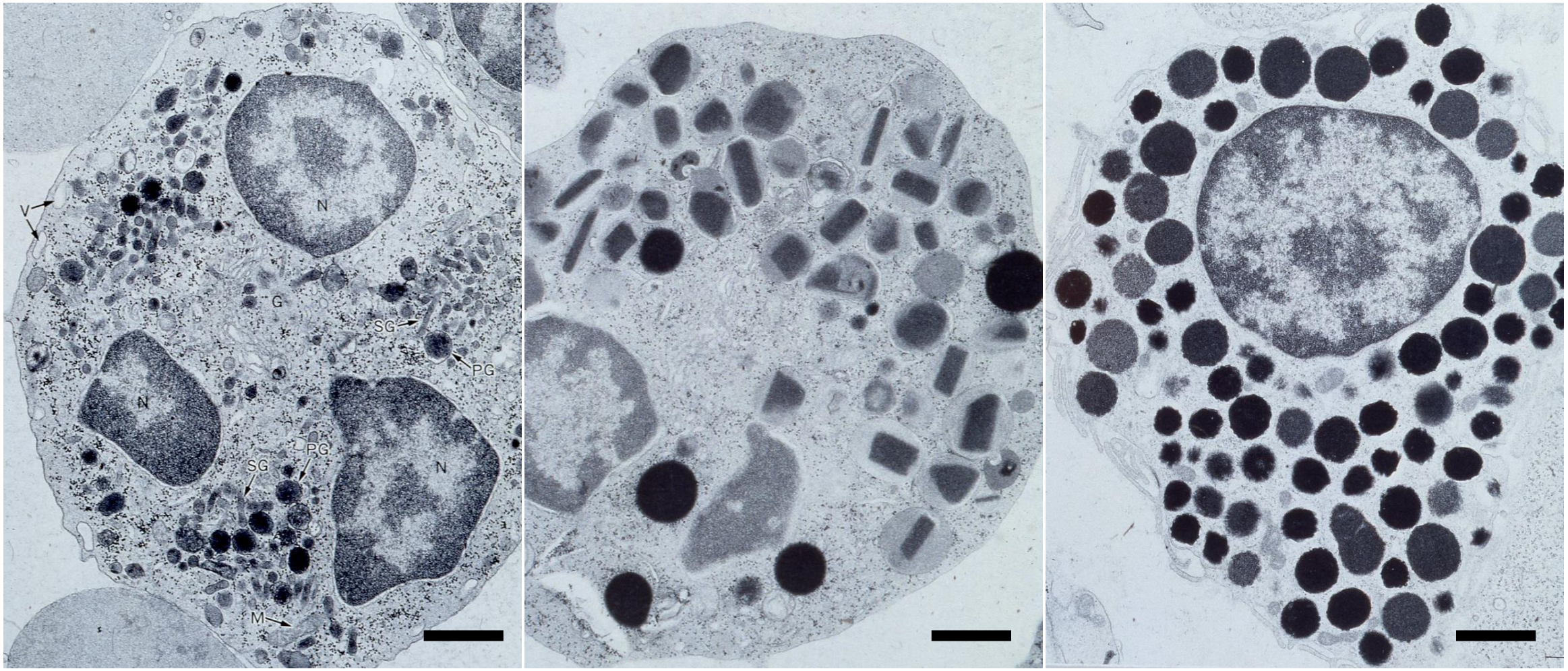

Ultrastructure of neutrophil (left), eosinophil (center) and basophil (right) in the peripheral blood.

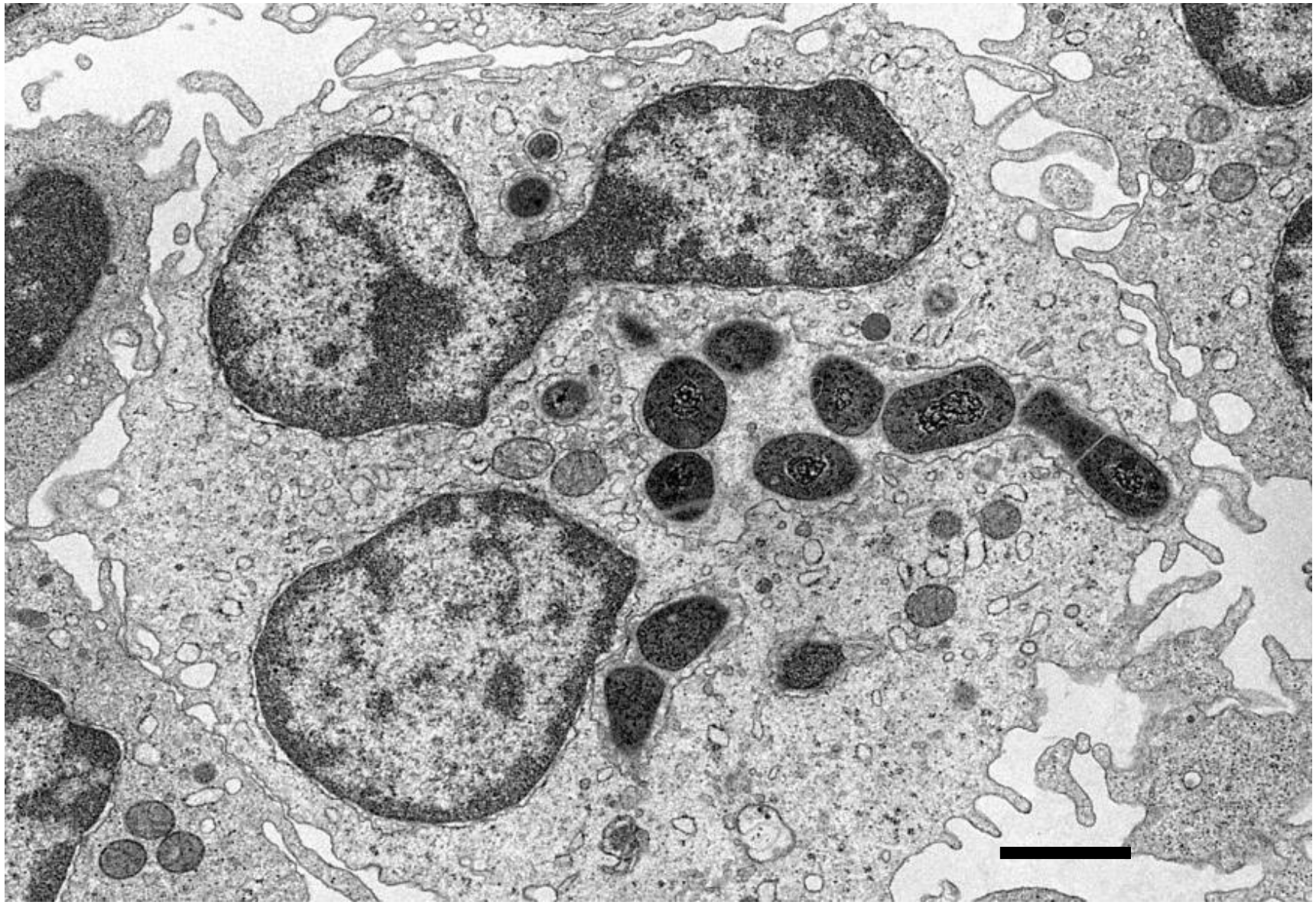

Ultrastructure of a neutrophil phagocytizing rods. Rods are seen in the lumen of lysosomes.

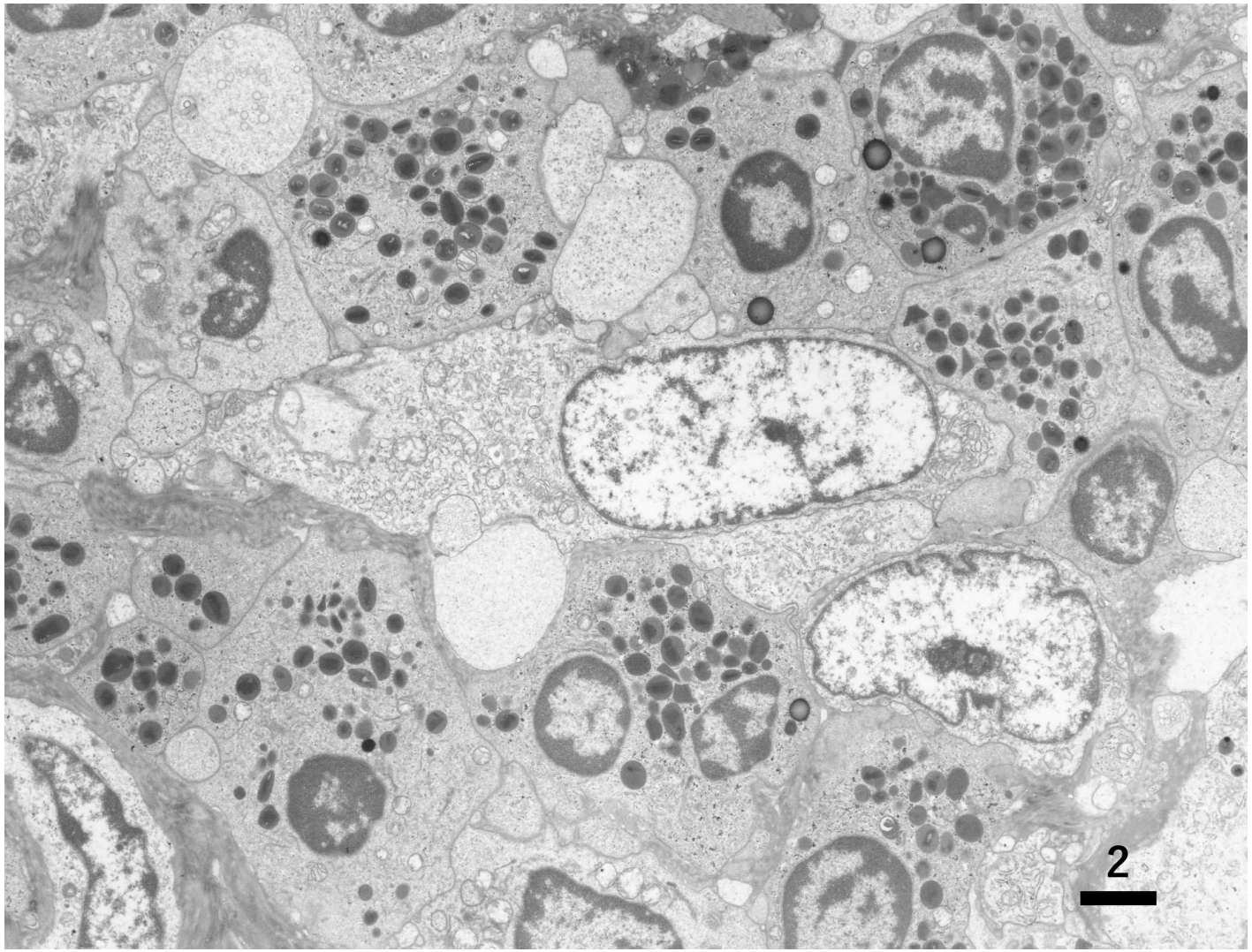

Ultrastructure of Kimura's disease in the soft tissue.
Numbers of mature eosinophils is infiltrated.
Macrophages and lymphocytes are intermingled.

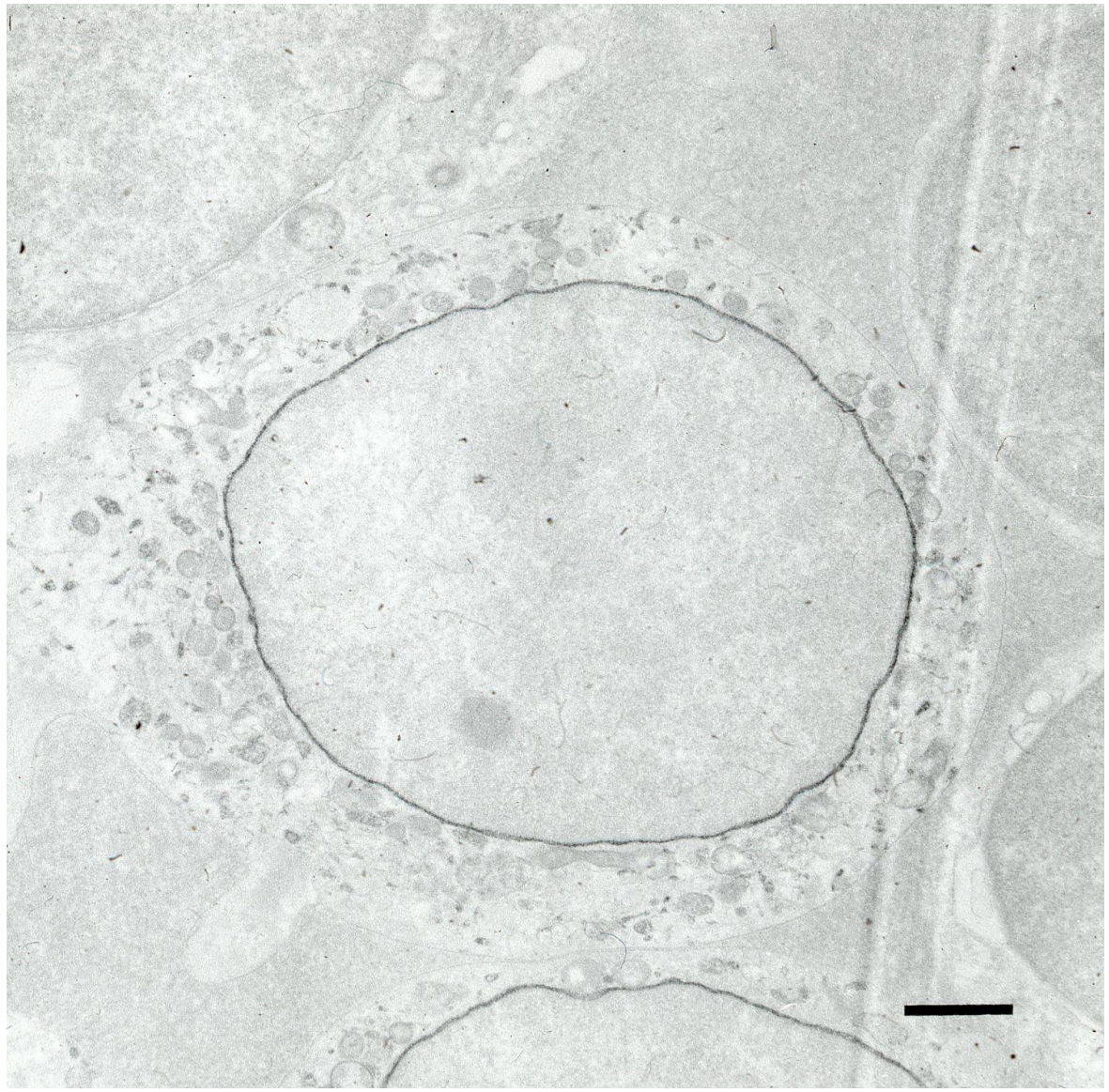

Ultrastructure of AML, M0. MPO activity is observed in the perinuclear space. No granule formation is seen.

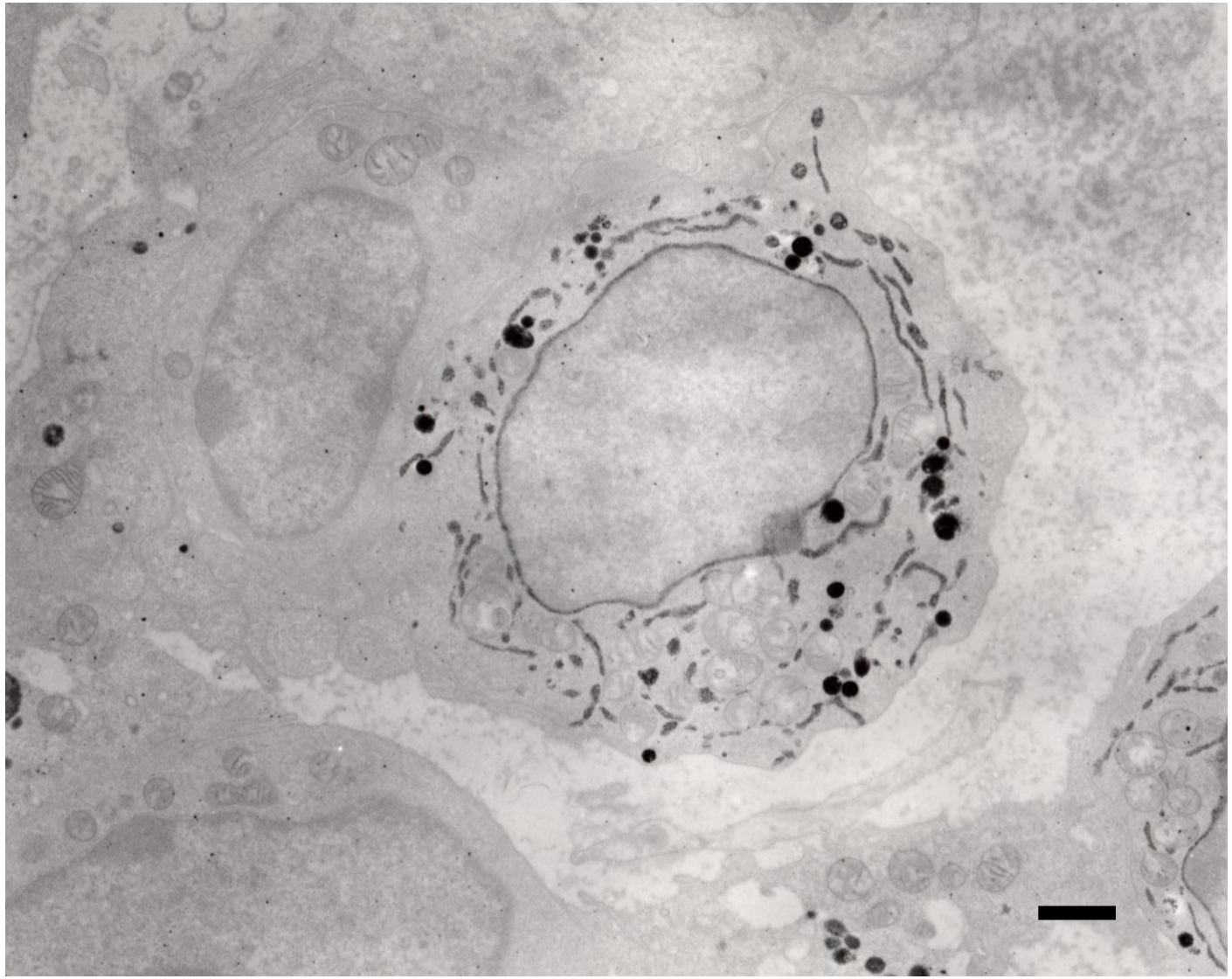

Ultrastructure of AML, M1. MPO activity is seen in the cisterna of rough endoplasmic reticulum, perinuclear space as well as in the specific granules.

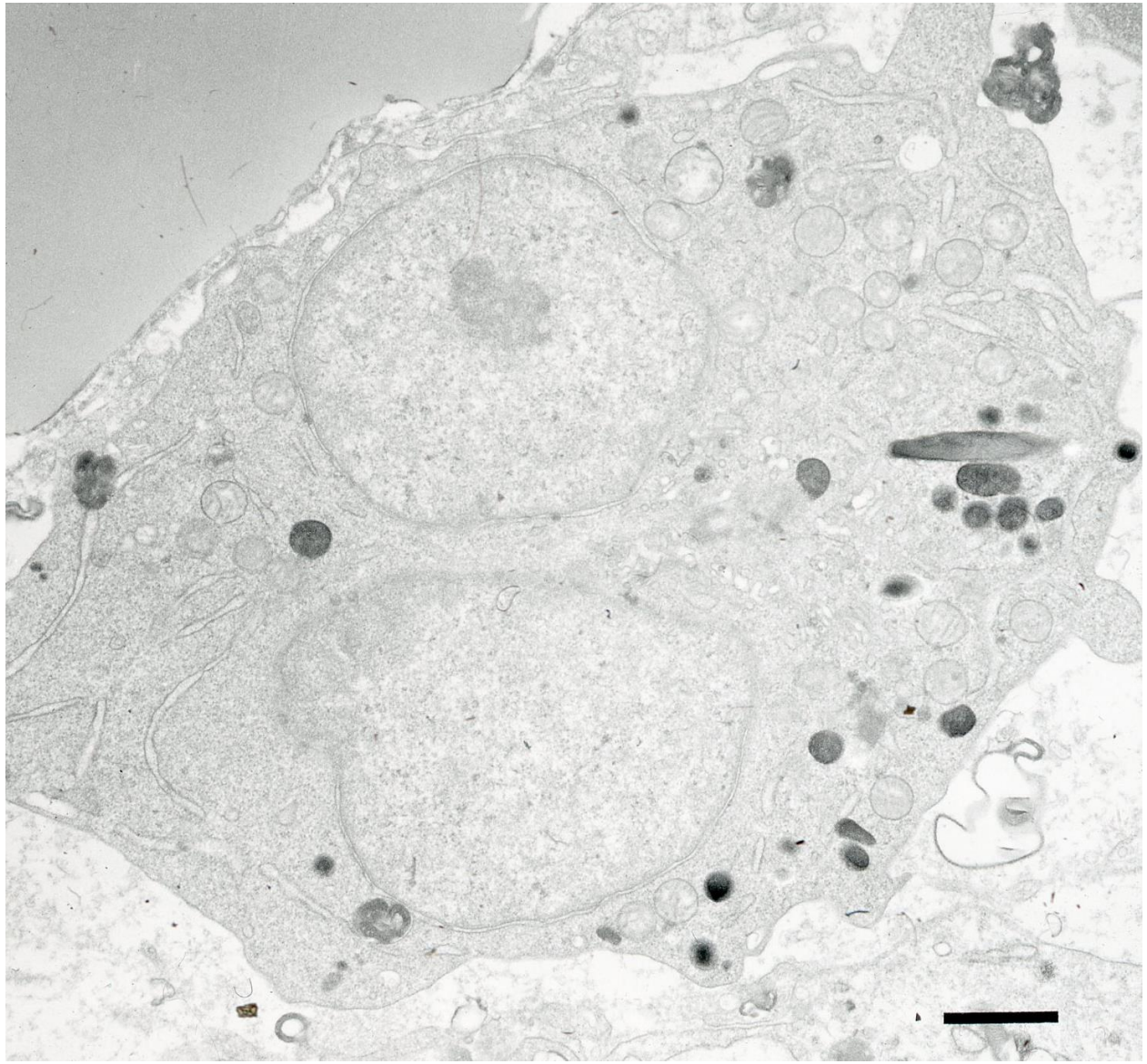

Ultrastructure of AML, M2. MPO-positive granules are observed. A small Auer body is formed. Reactivity of the perinuclear space is no longer seen.

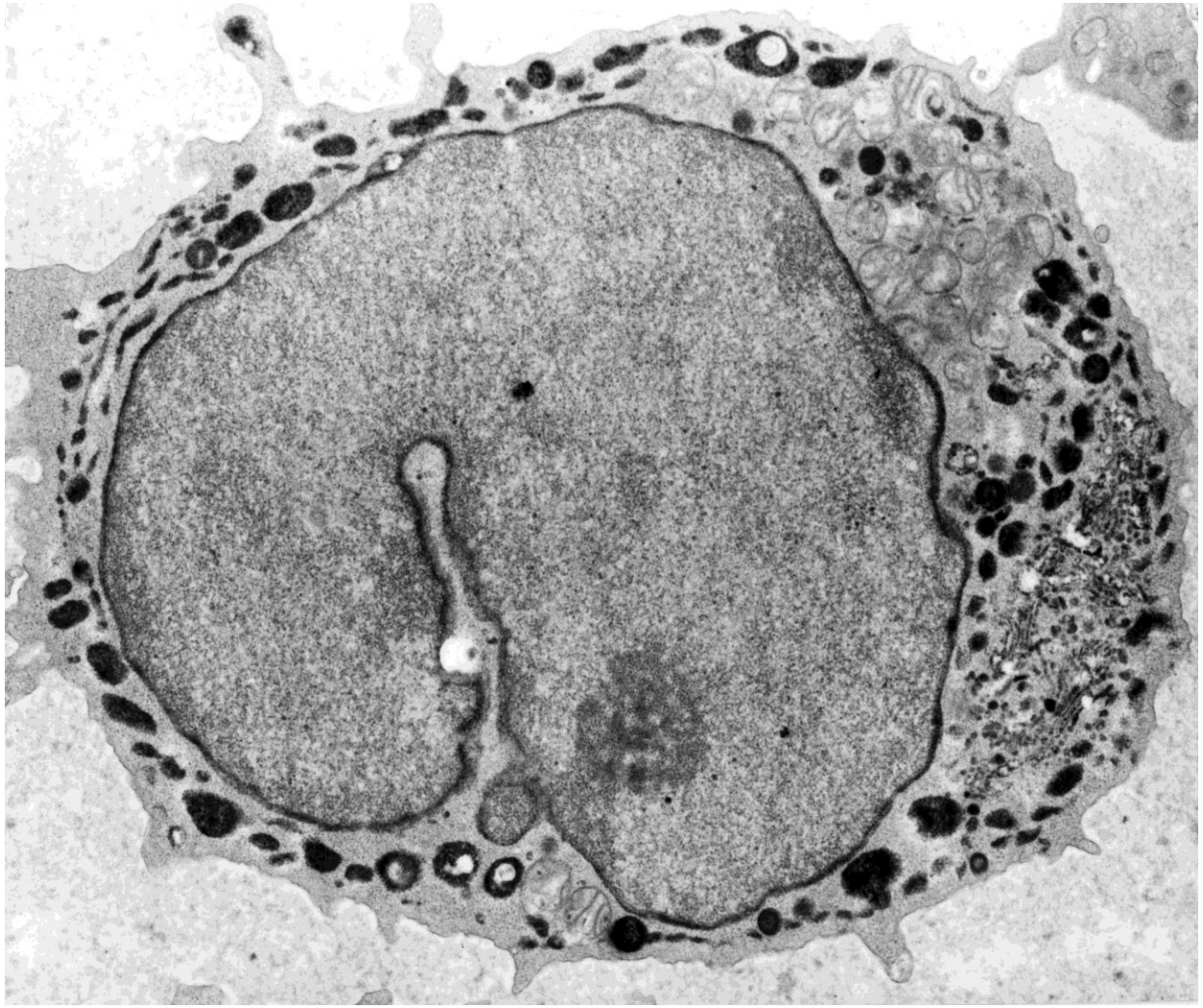

Ultrastructure of AML, M3 (acute promyelocytic leukemia). Large-sized MPO-reactive granules are richly distributed in the cytoplasm. Small-sized maturing granules are seen around the Golgi apparatus. The nucleus is indented.

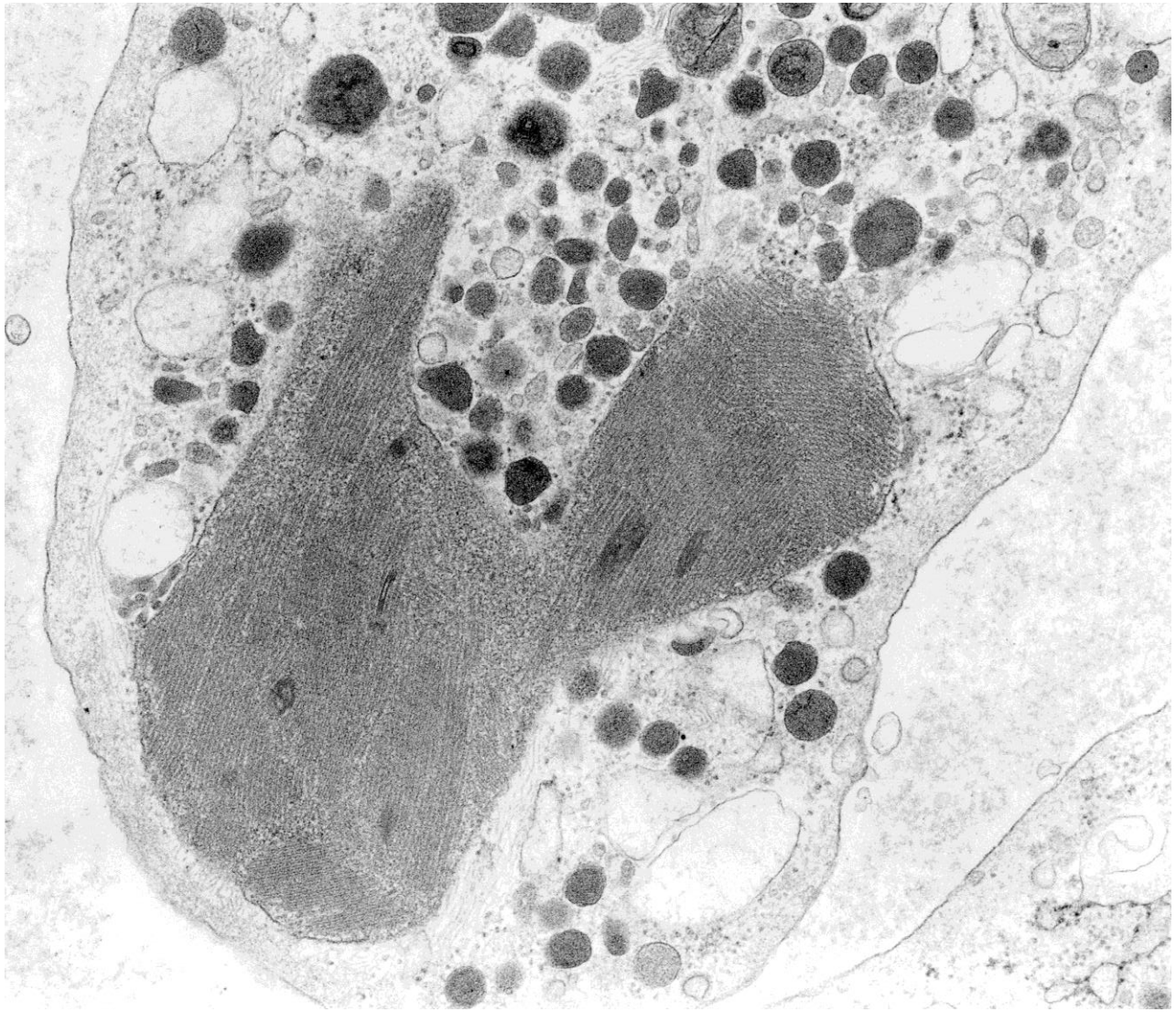

Ultrastructure of AML, M3 (acute promyelocytic leukemia).
In addition to large-sized specific granules, an Auer body
with vertically striped crystalline structure is seen.

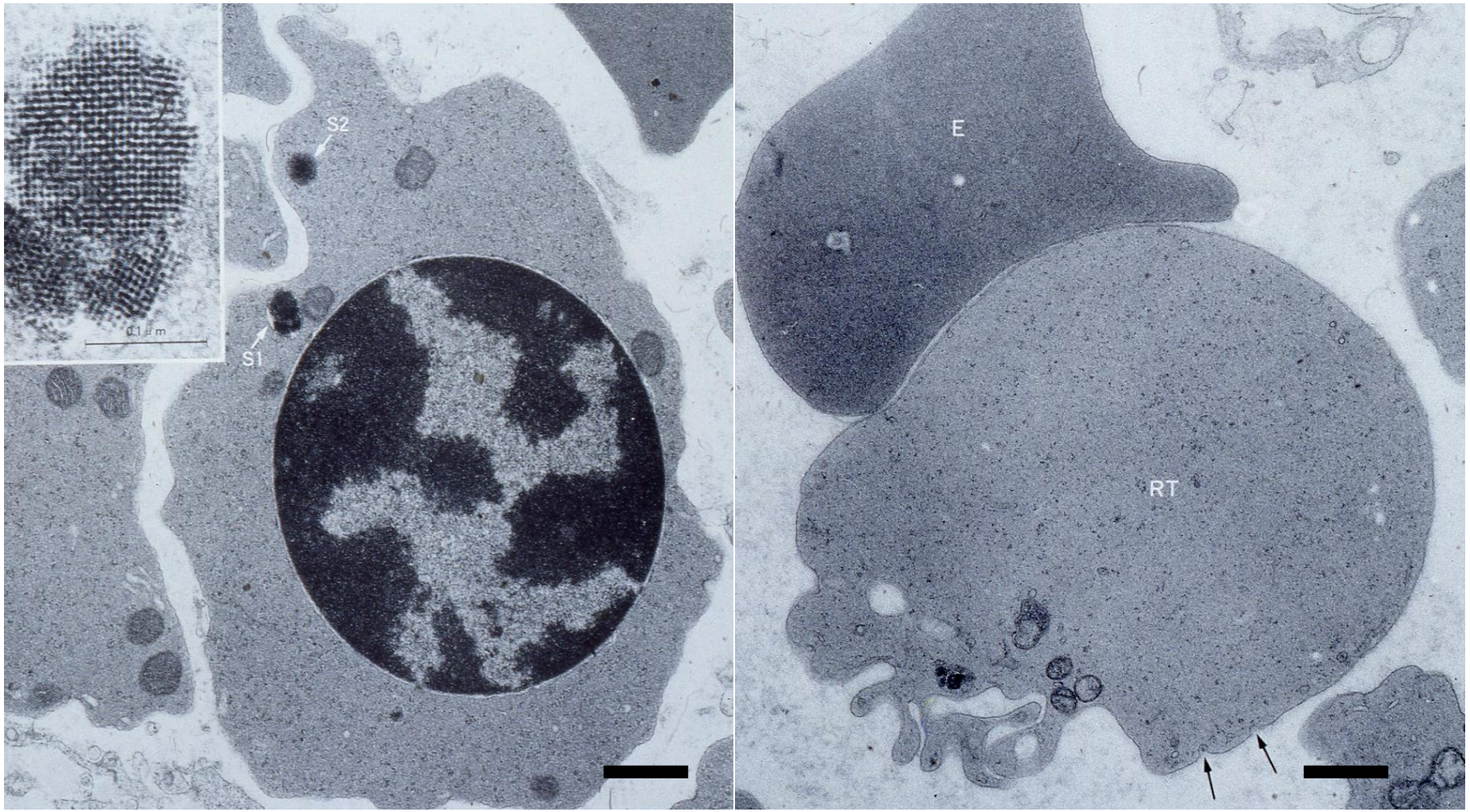

Ultrastructure of an erythroblast in the bone marrow (left) and a reticulocyte in the peripheral blood (right). Free ribosomes and mitochondria remain in the reticulocyte. S1/S2: siderosomes, E: erythrocyte, RT: reticulocyte

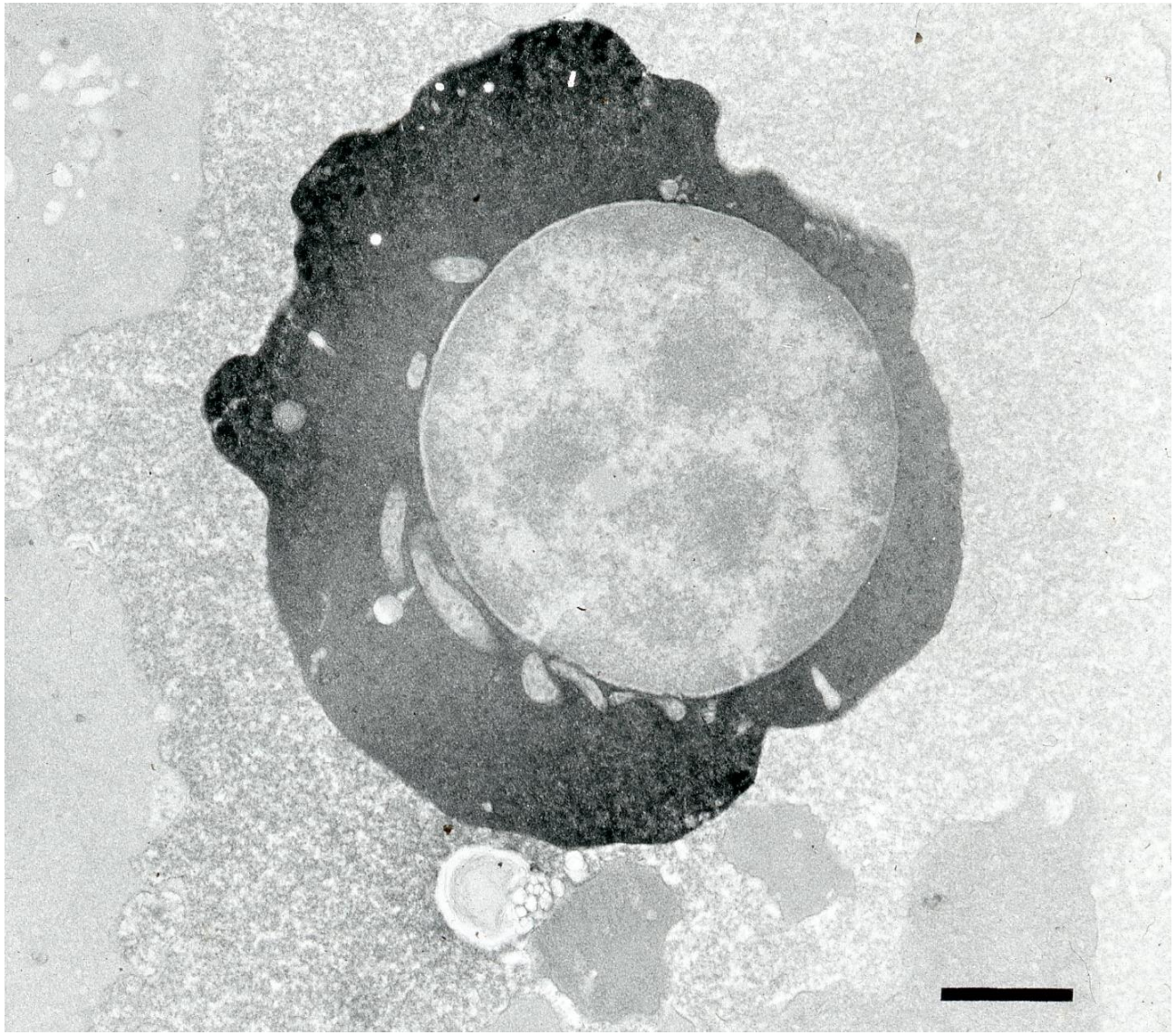

Ultrastructure of an erythroblast in the bone marrow. MPO activity due to pseudoperoxidase activity of hemoglobin is diffusely seen in the cytoplasm.

Ultrastructure of megakaryocyte in the bone marrow. Numbers of alpha-granules are distributed in the cytoplasm. Formation of agranular platelets is formed along the plasma membrane. The nucleus is indented.

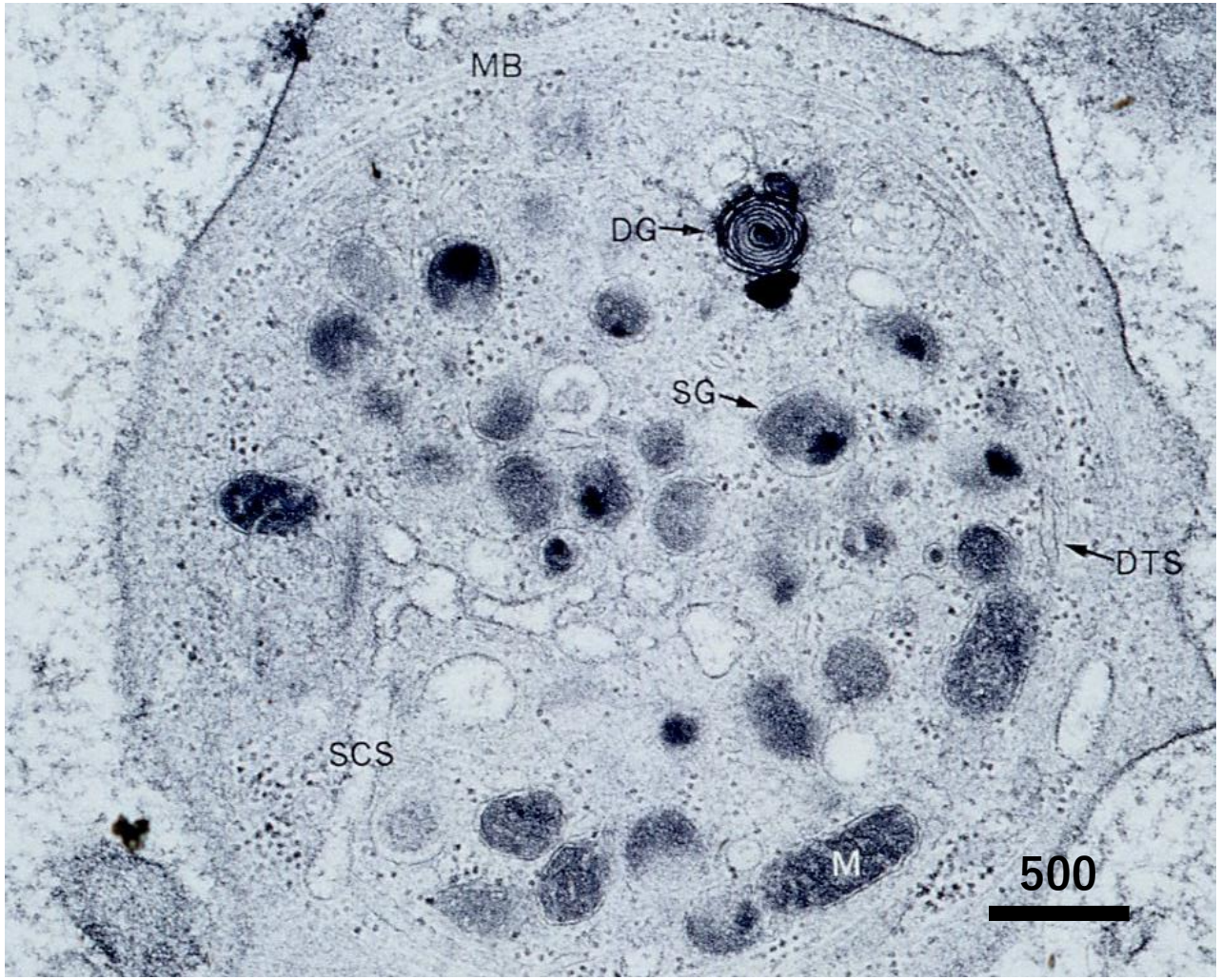

Ultrastructure of a platelet in the peripheral blood. Alpha-granule (specific granule: SG) are richly seen. Glycogen particles are dispersed. DG: dense granule, M: mitochondria, DTS: dense tubular system, SCS: open canalicular system, MB: submembranous filament bundle rich in microtubules

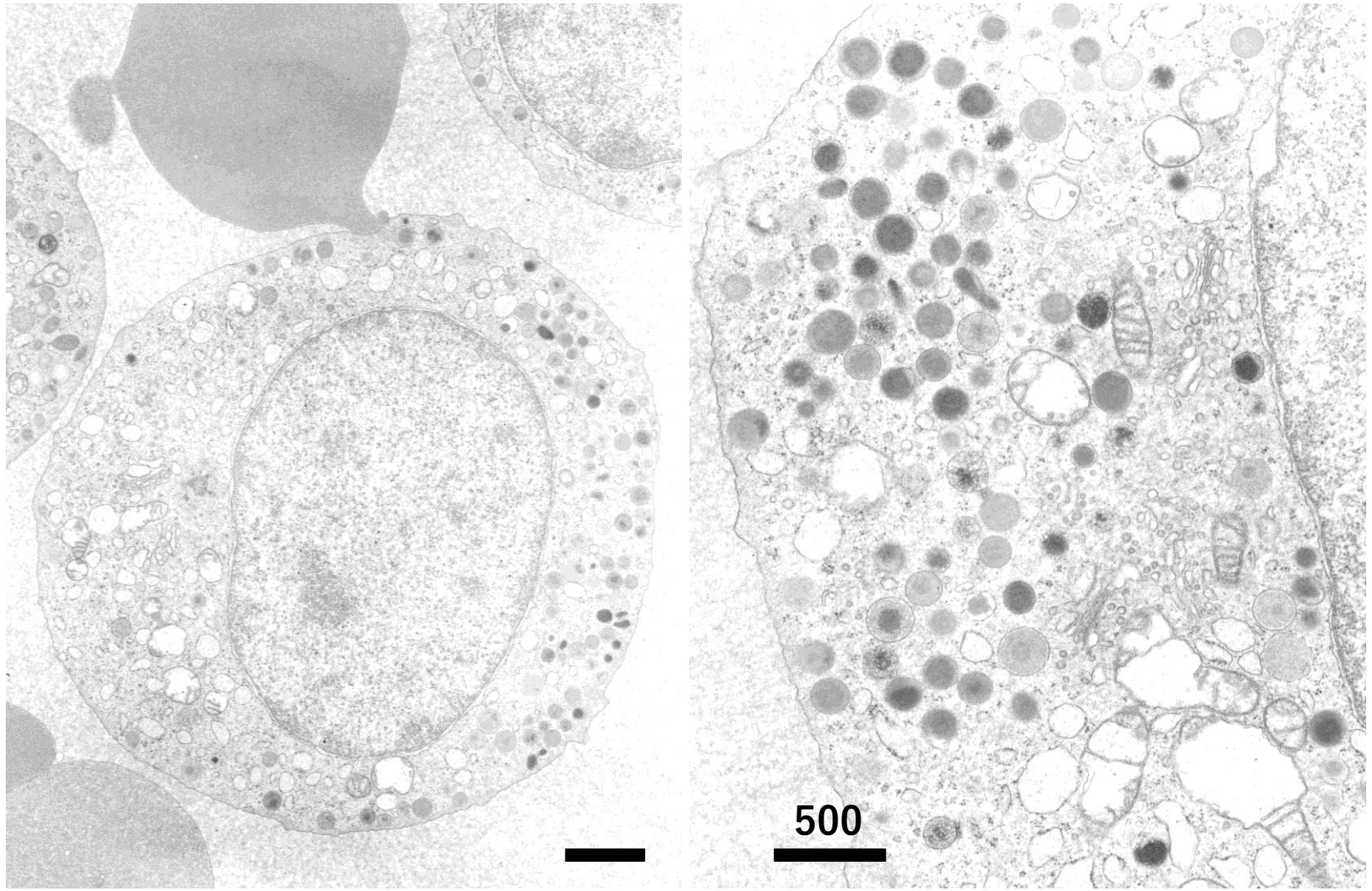

Ultrastructure of AML, M7 (acute megakaryoblastic leukemia), The blast contains a round nucleus and electron-dense alpha-granules in the cytoplasm.

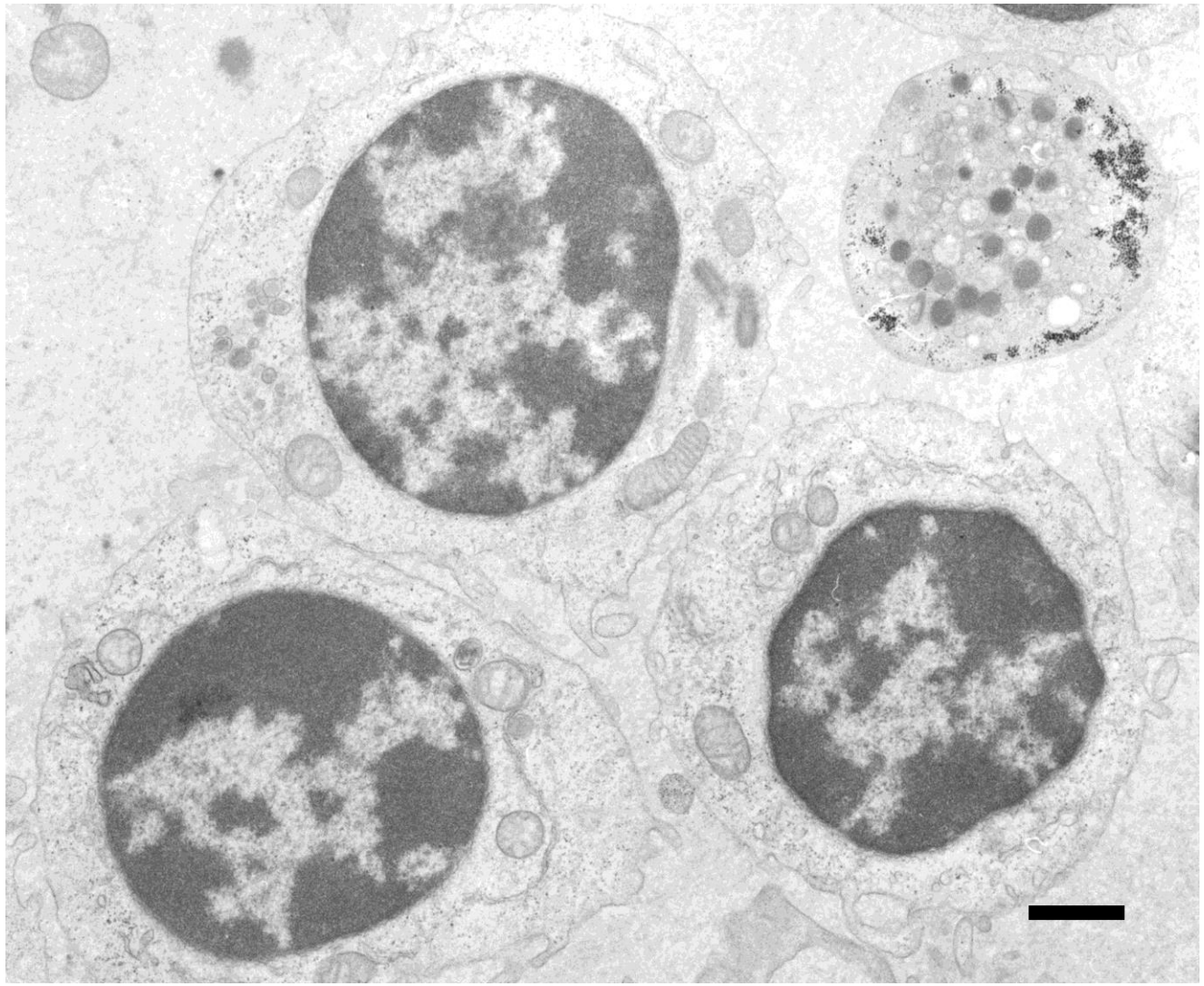

Ultrastructure of B-CLL in the bone marrow. Three small lymphocytes of B-cell lineage and one platelet are observed.

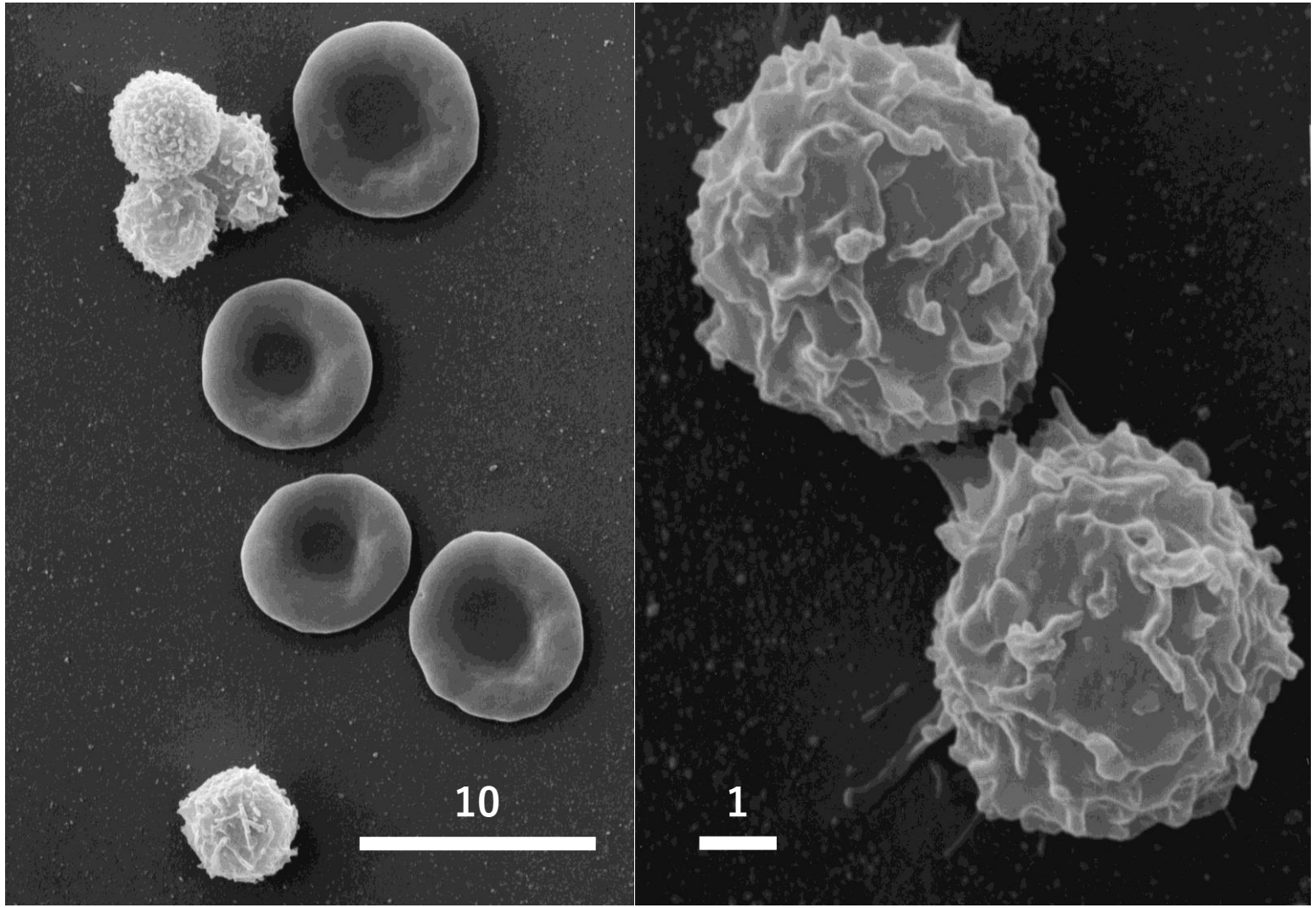

Scanning EM of B-CLL in the peripheral blood. left: small B-lymphocytes and red cells, right: small B-lymphocytes.

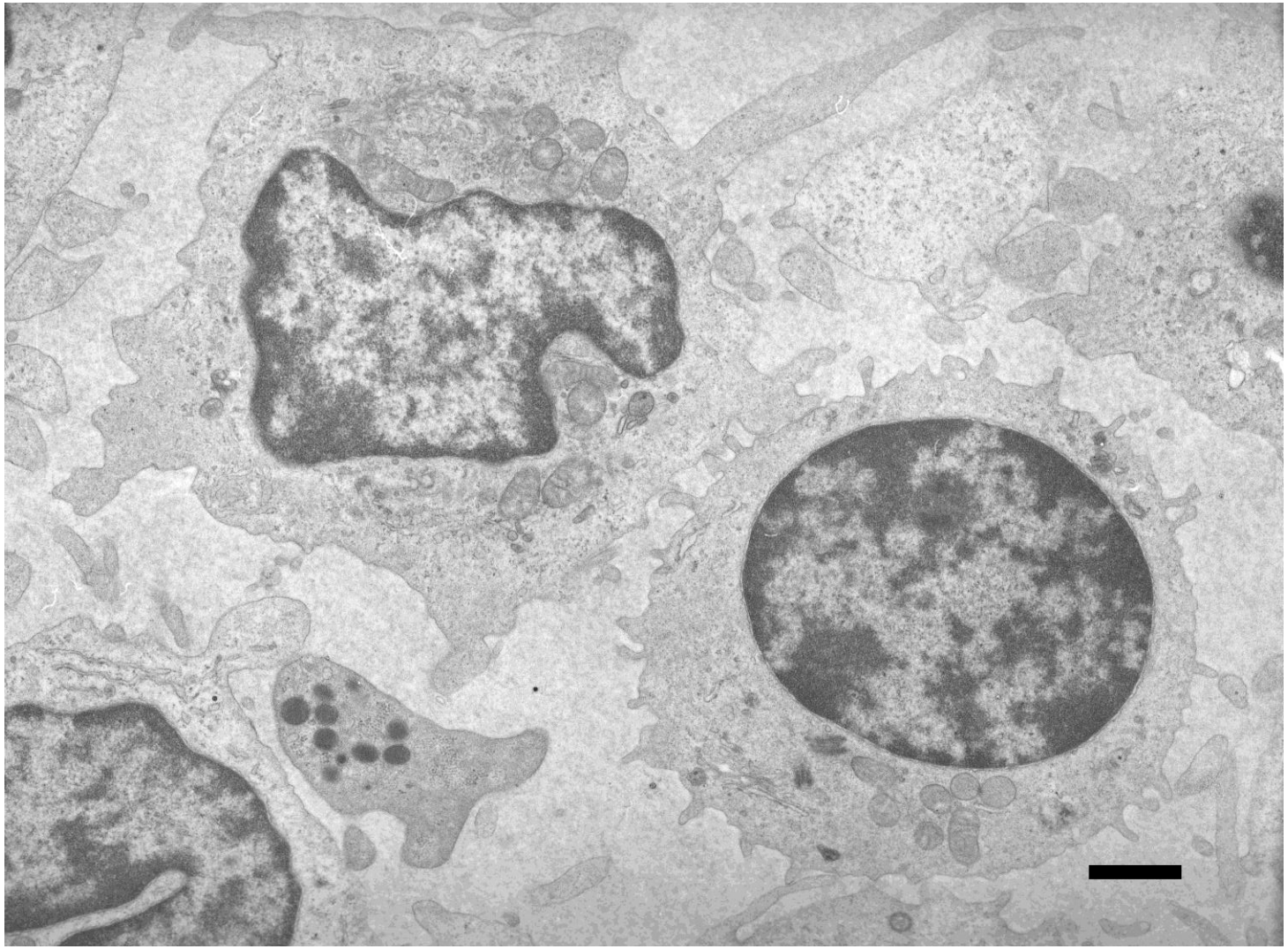

Ultrastructure of hairy cell leukemia in the peripheral blood. Three hairy cells and one platelet are seen. Fine hairy processes are observed. One platelet is included.

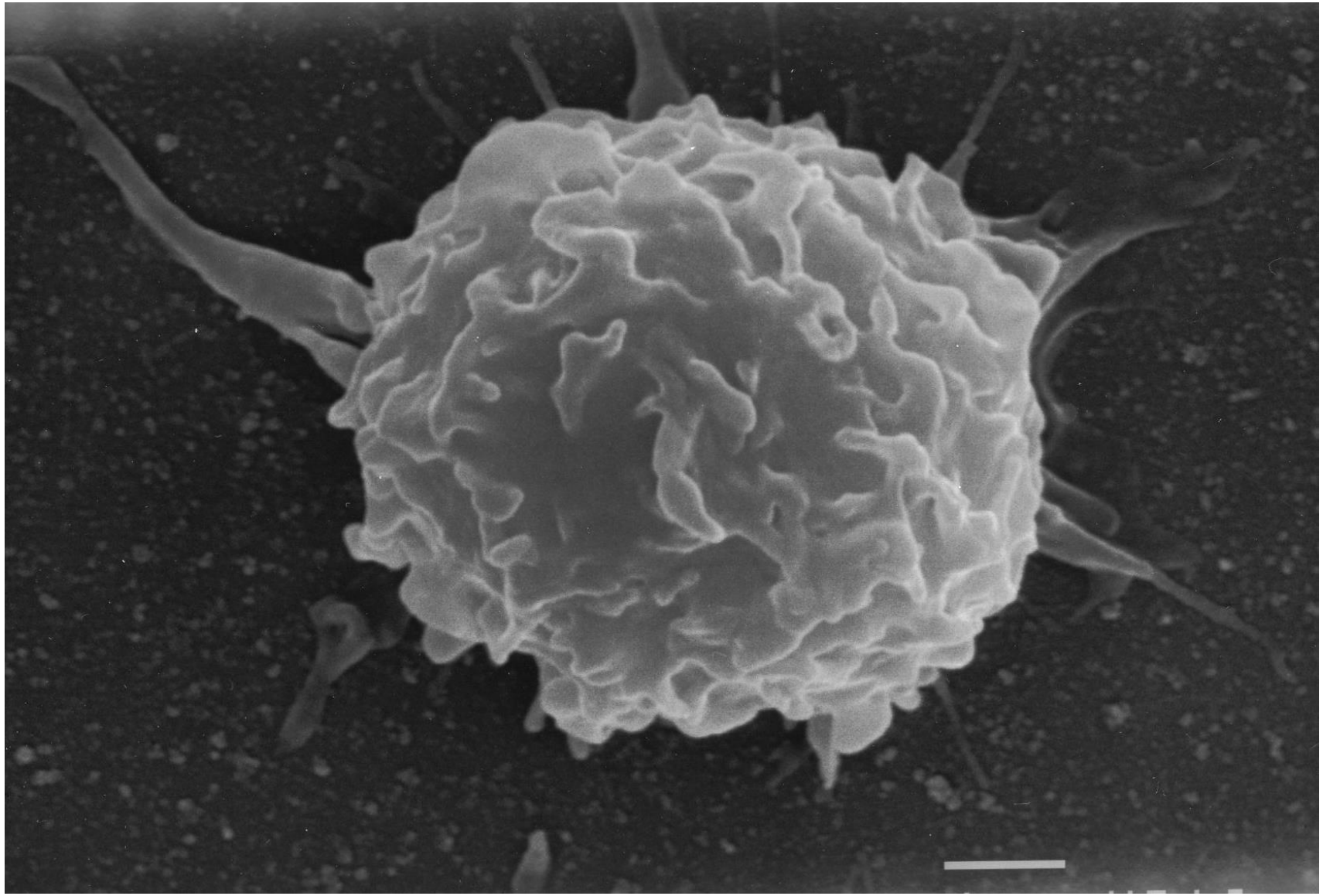

Scanning EM of hairy cell leukemia in the peripheral blood. Long hairy process are observed.

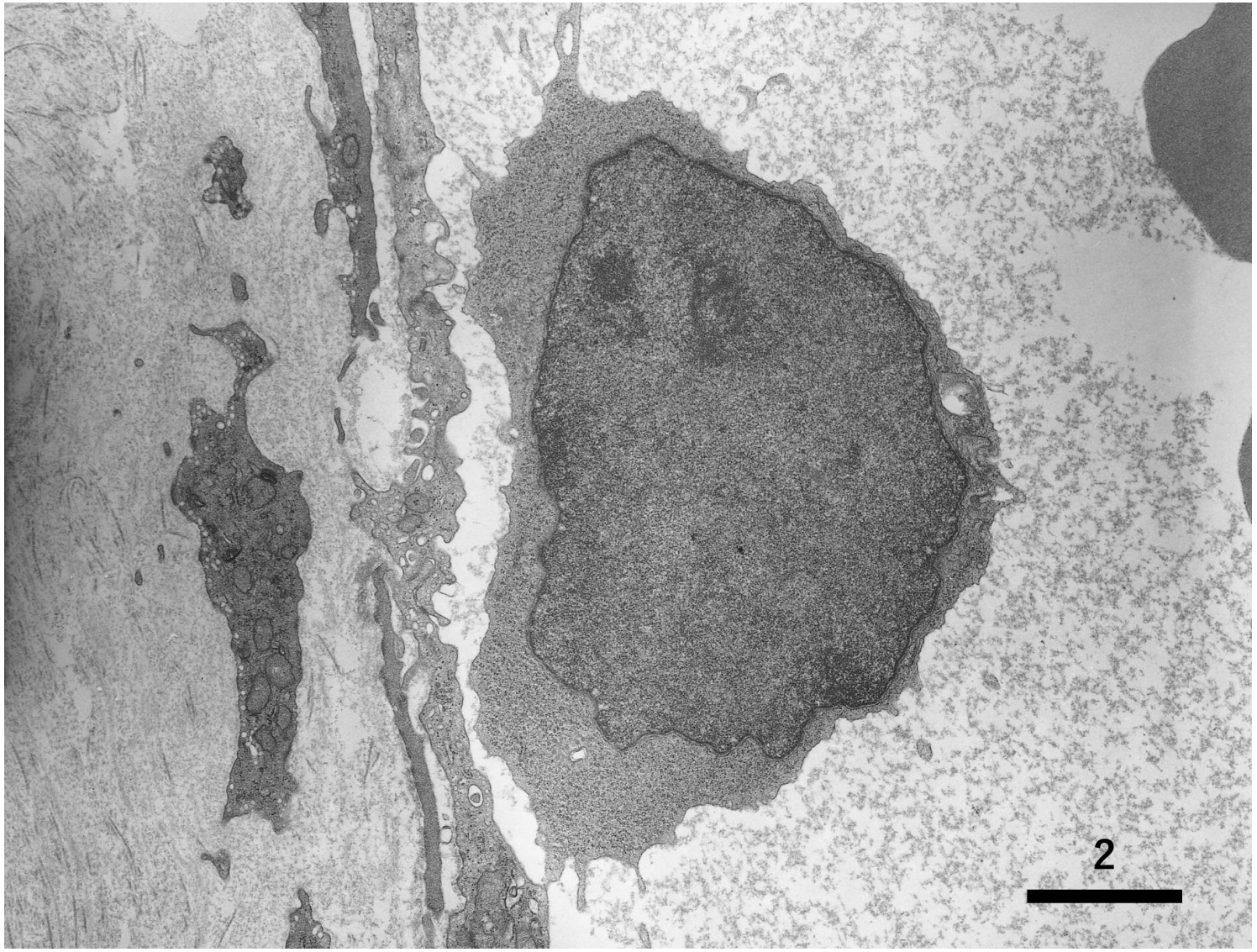

Ultrastructure of intravascular large B-cell lymphoma in the skin. An intravascular lymphoma cell in the dermal capillary vessel is anchored to the endothelial cell via fine cytoplasmic processes. Euchromatin is increased in the lymphoma cell.

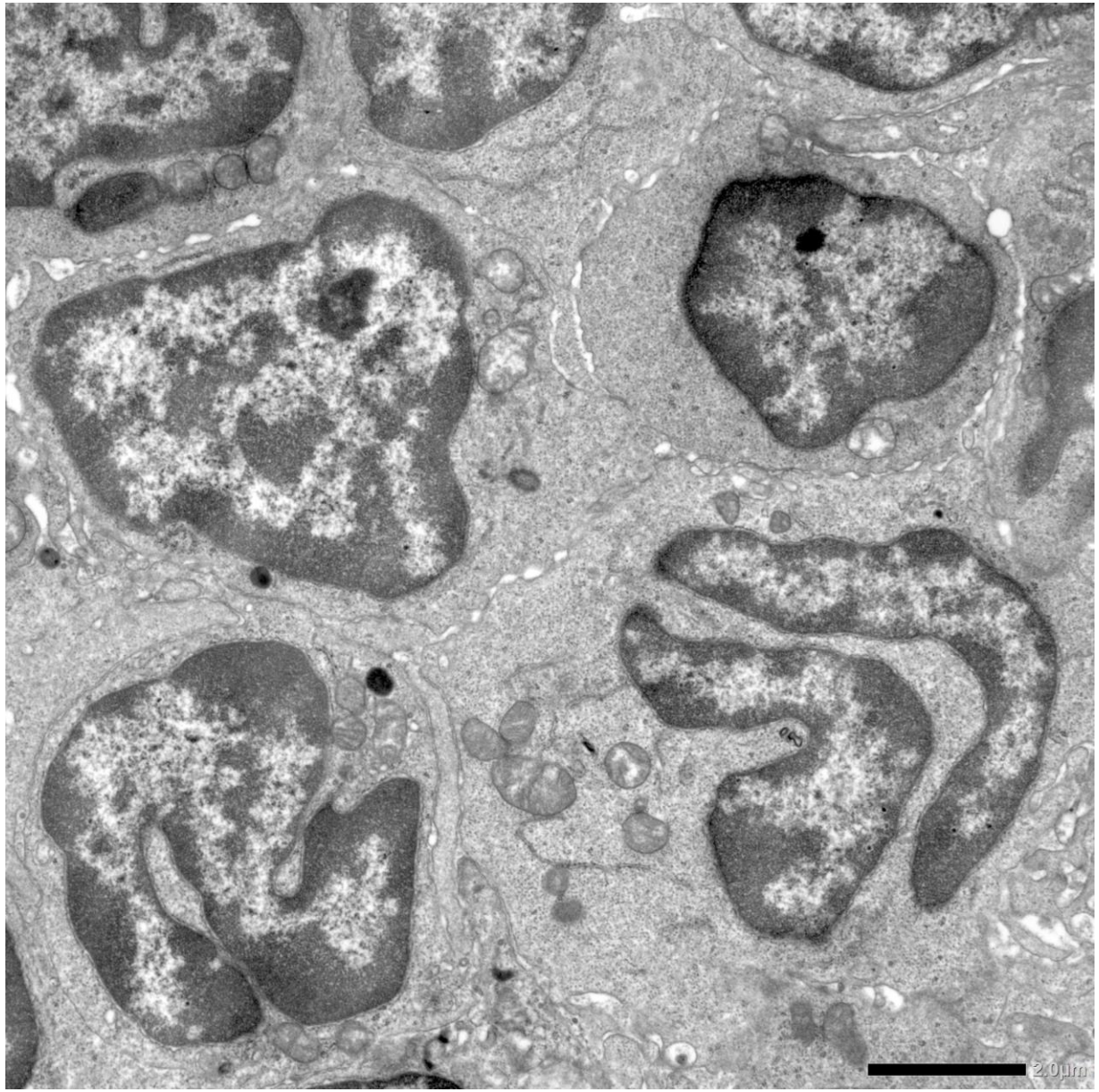

Ultrastructure of diffuse large B-cell lymphoma in the lymph node. Cleaved nuclei with distinct nuclear indentation are observed. A small reactive lymphocyte is also seen.

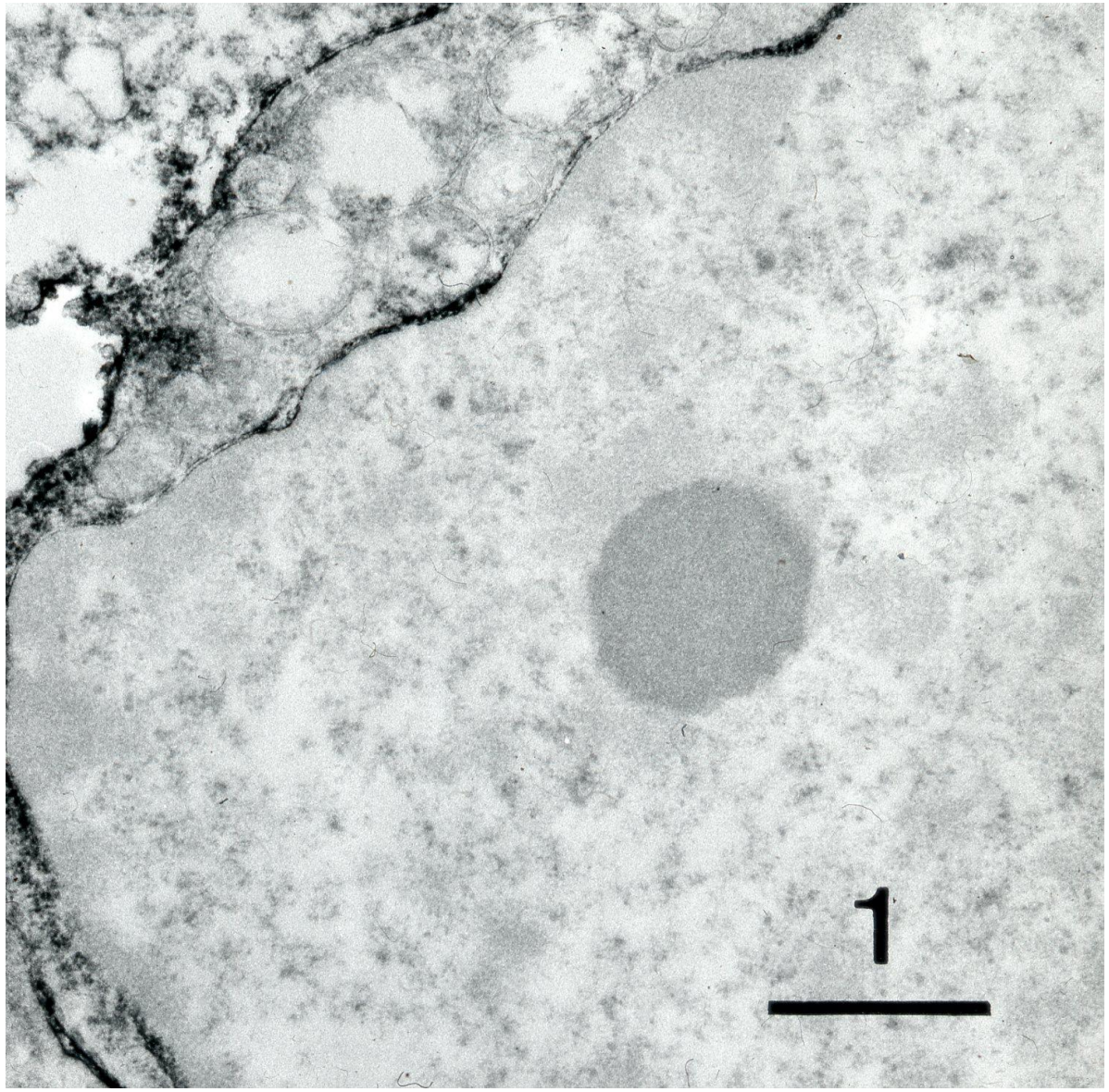

Immunoelectron microscopy for IgM, pre-embedding method, in large B-cell lymphoma with a serum monoclonal peak of IgM. IgM is localized on the plasma membrane and in the perinuclear space.

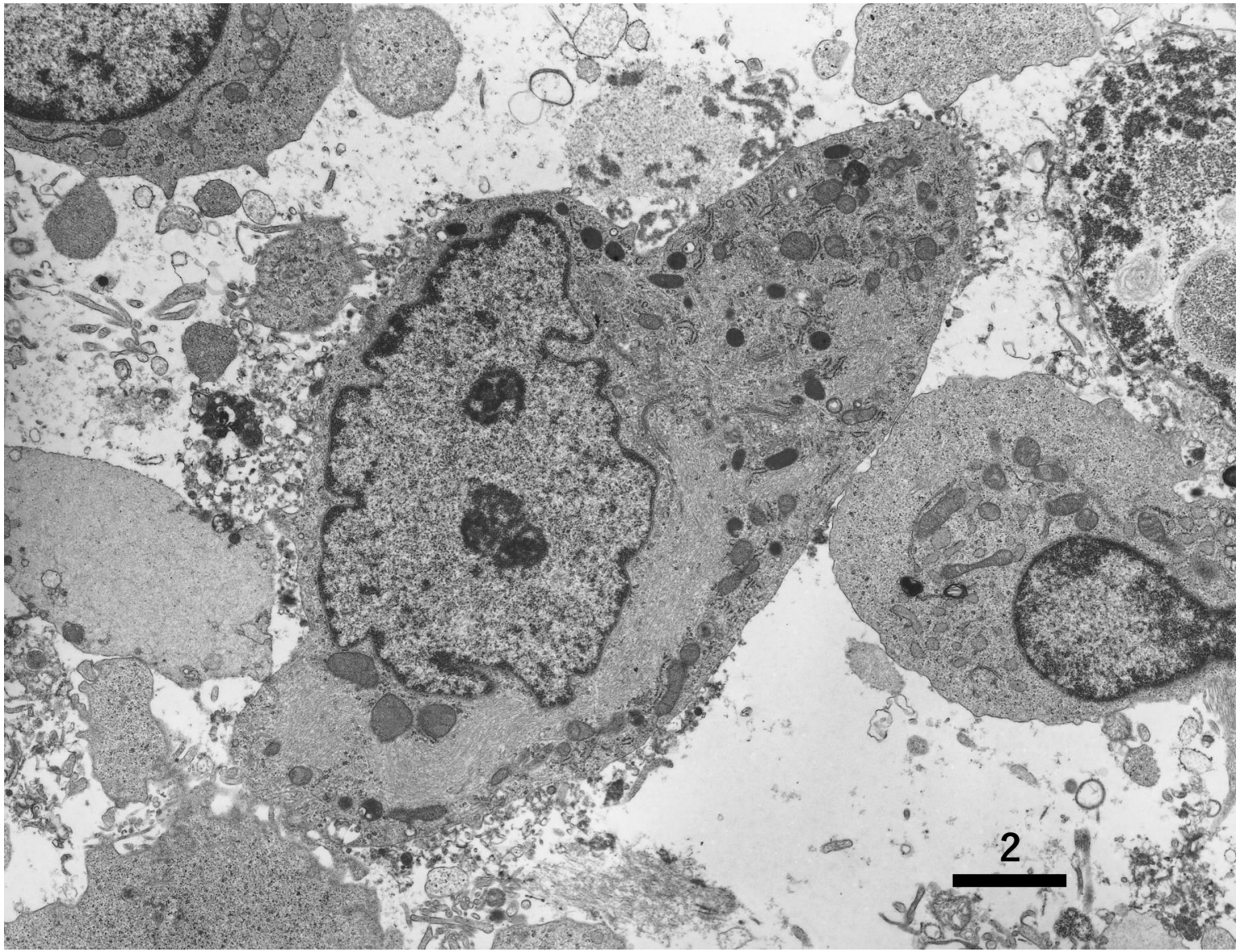

Ultrastructure of immunoblastic B-cell lymphoma in the brain. A signet ring cell-type lymphoma cell with perinuclear accumulation of intermediate (vimentin) filaments is seen.

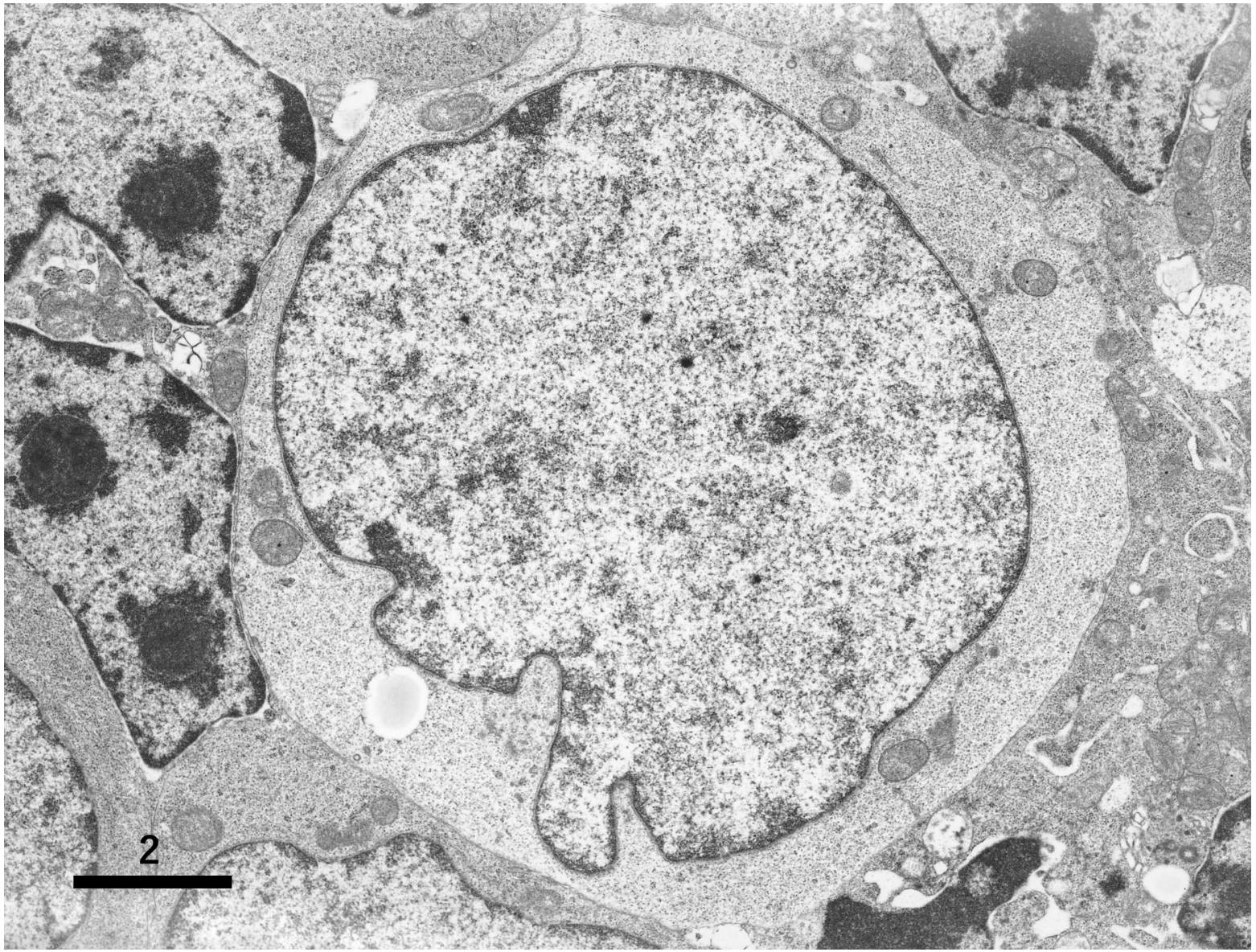

Ultrastructure of Burkitt lymphoma in the bone. Dispersed euchromatin and fat droplets in the organelle-poor cytoplasm are seen in an immature B-lymphocyte.

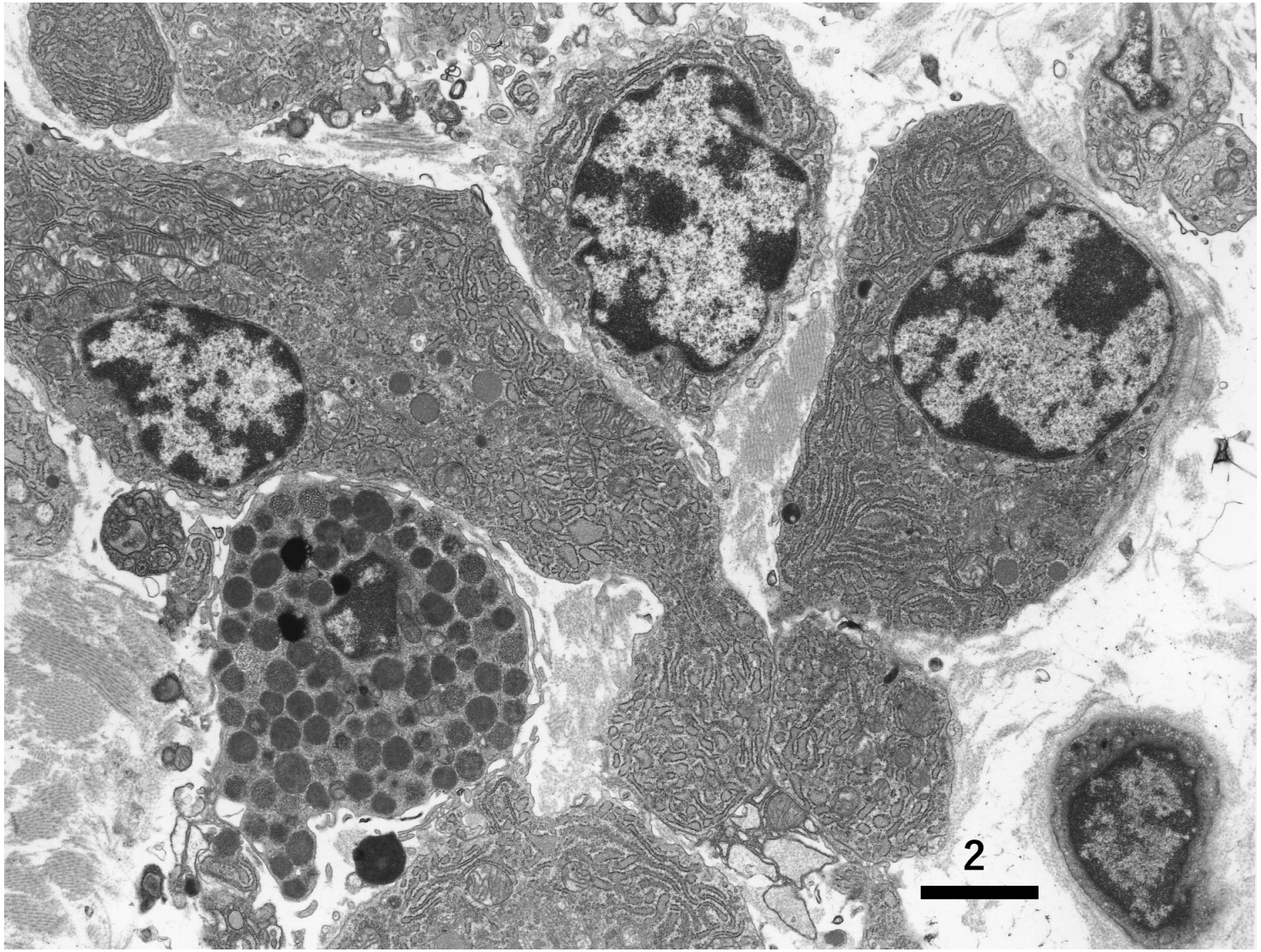

Ultrastructure of plasma cells infiltrating in the gingiva. Well-developed rER in the cytoplasm and condensed heterochromatin in the nucleus are observed. A mast cell is also distributed.

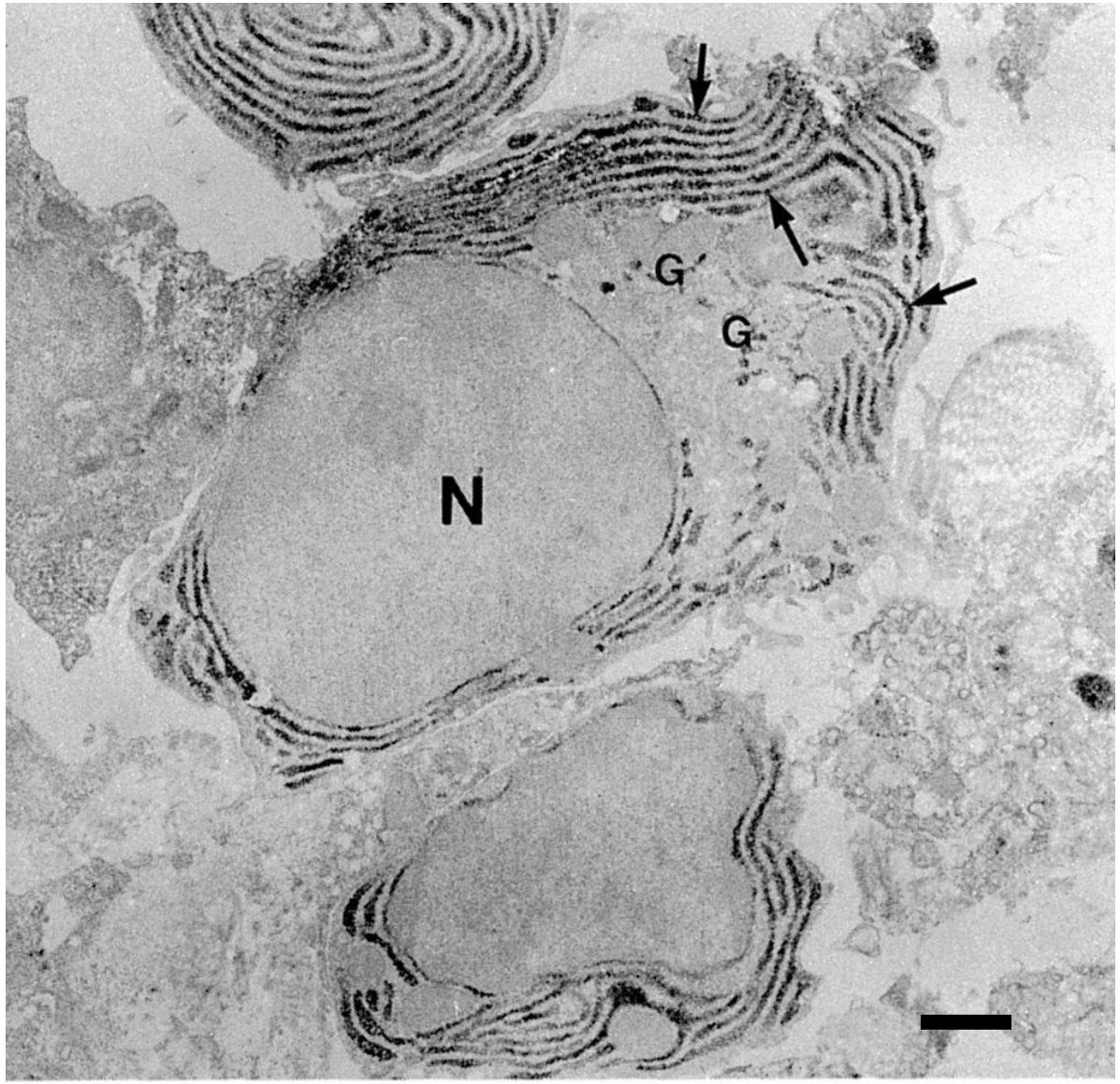

Immunoelectron microscopy for IgG production in reactive plasma cells, pre-embedding method. IgG is localized in the cisterna of rough endoplasmic reticula (arrows) and perinuclear space. Golgi apparatus (G) is devoid of IgG immunoreactivity. N=nucleus

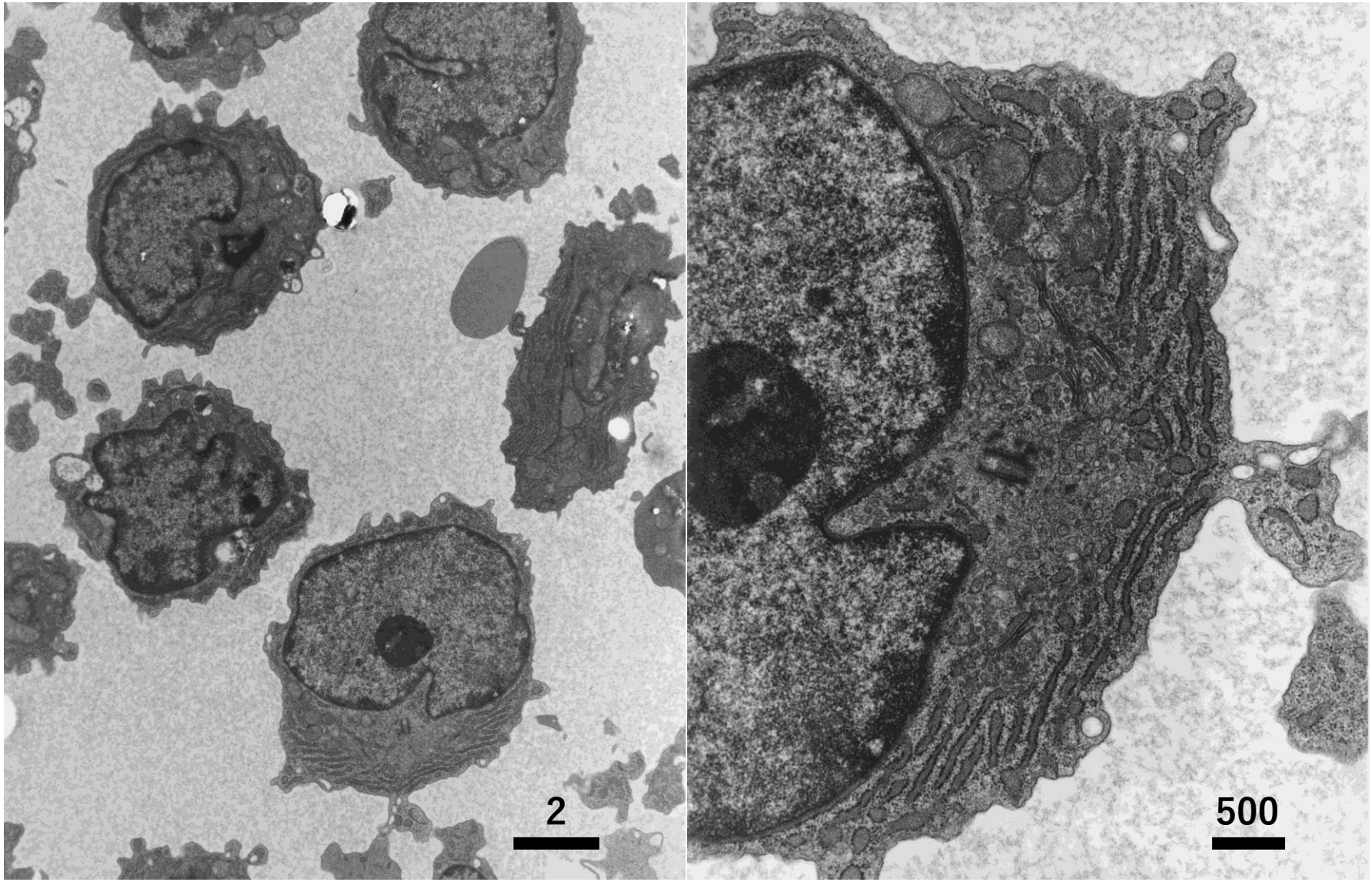

Ultrastructure of plasmablastic leukemia in the peripheral blood. Moderately developed rER and Golgi apparatus are observed. The nuclei possess a prominent nucleolus.

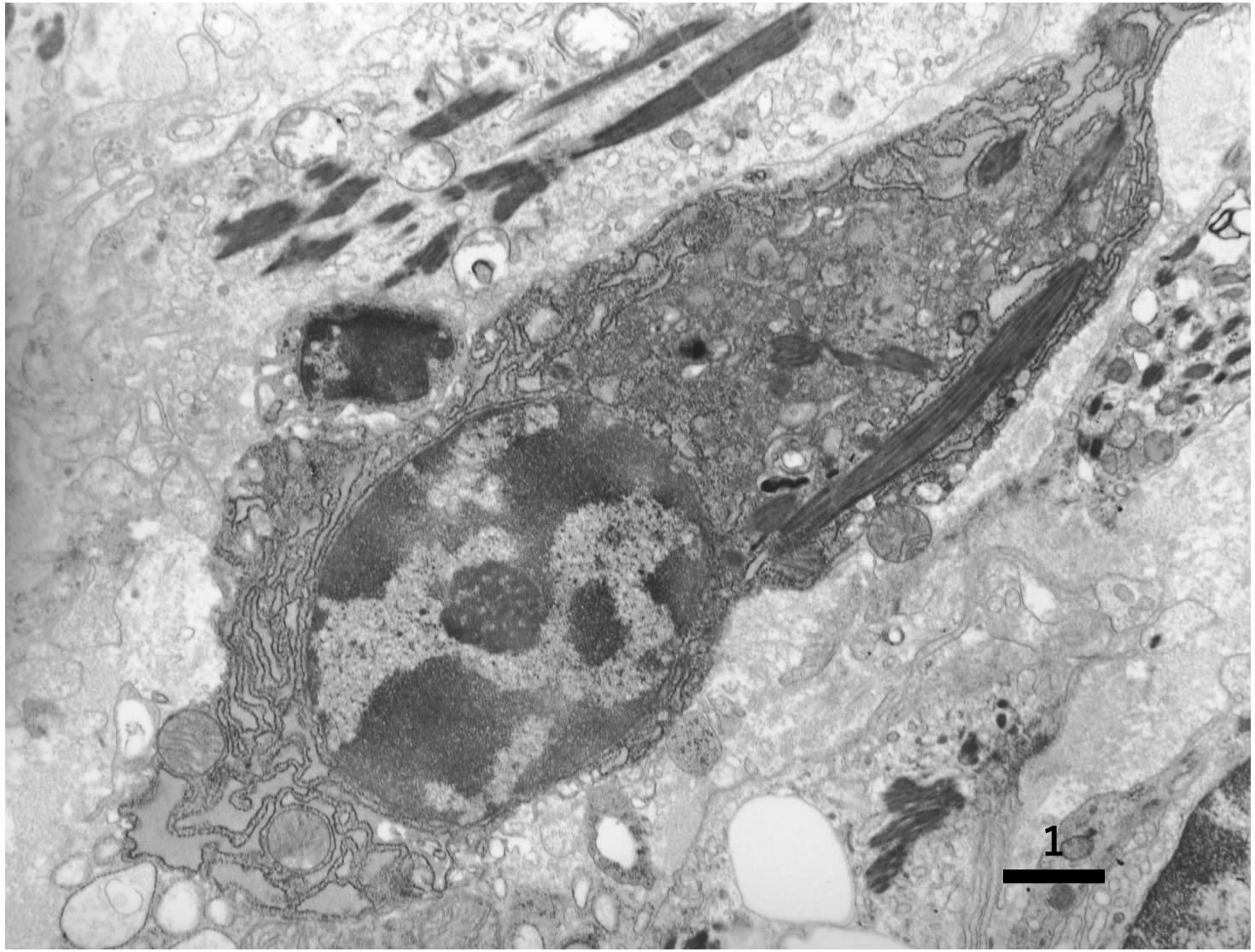

Ultrastructure of extramedullary plasmacytoma in the nasal cavity. Well-developed rER, condensed heterochromatin and a prominent nucleolus are noted. Intracytoplasmic crystal formation is associated.

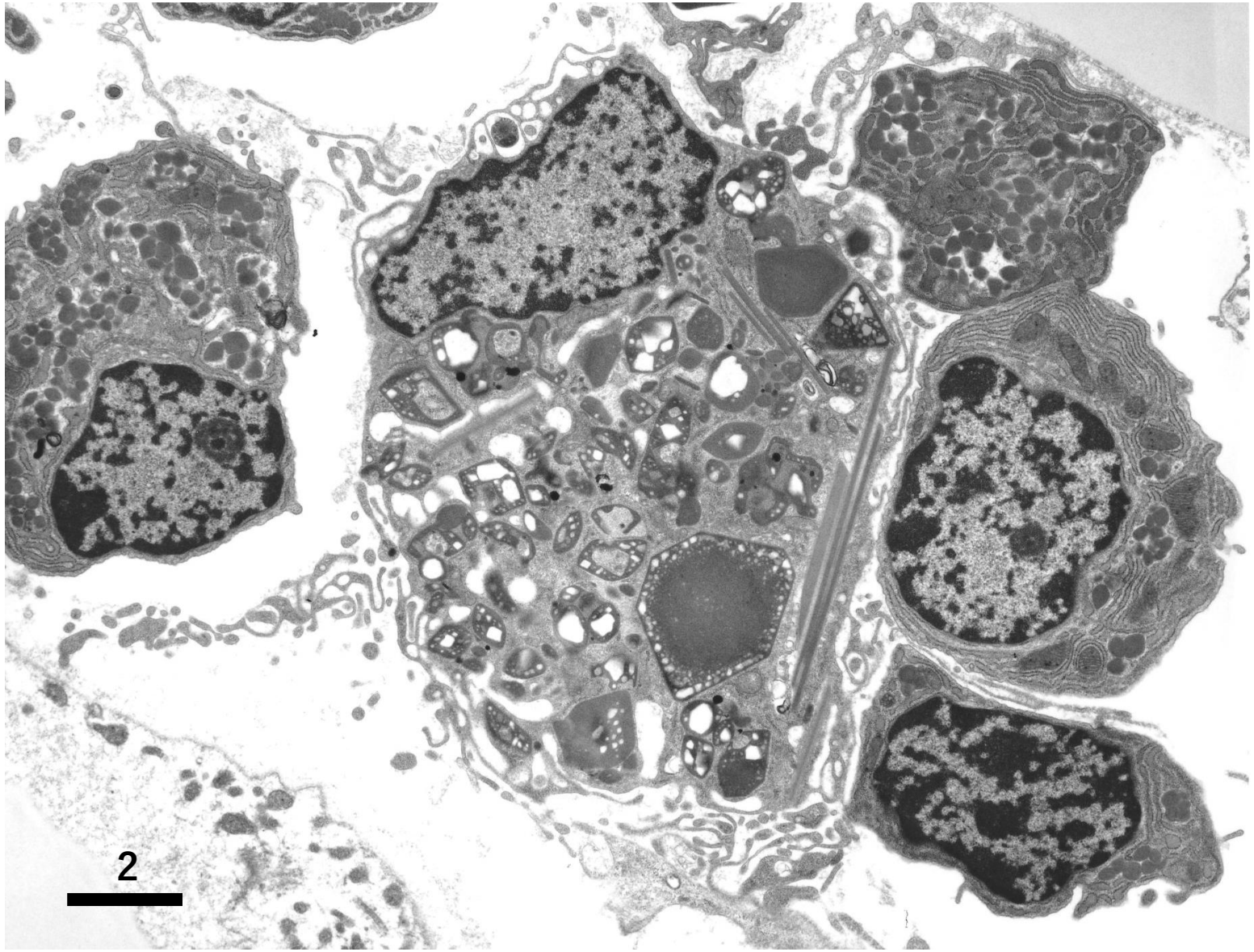

Ultrastructure of multiple myeloma in the bone marrow. Rough endoplasmic reticula are well developed. Peculiar crystallization of immunoglobulin molecules is observed. Needle-shaped, rhomboid, triangular and ovoid crystals fill the cytoplasm.

Immunoelectron microscopy for kappa light chain in multiple myeloma, kappa-type. The pre-embedding method visualizes kappa light chain in the cisterna of rER and perinuclear space.

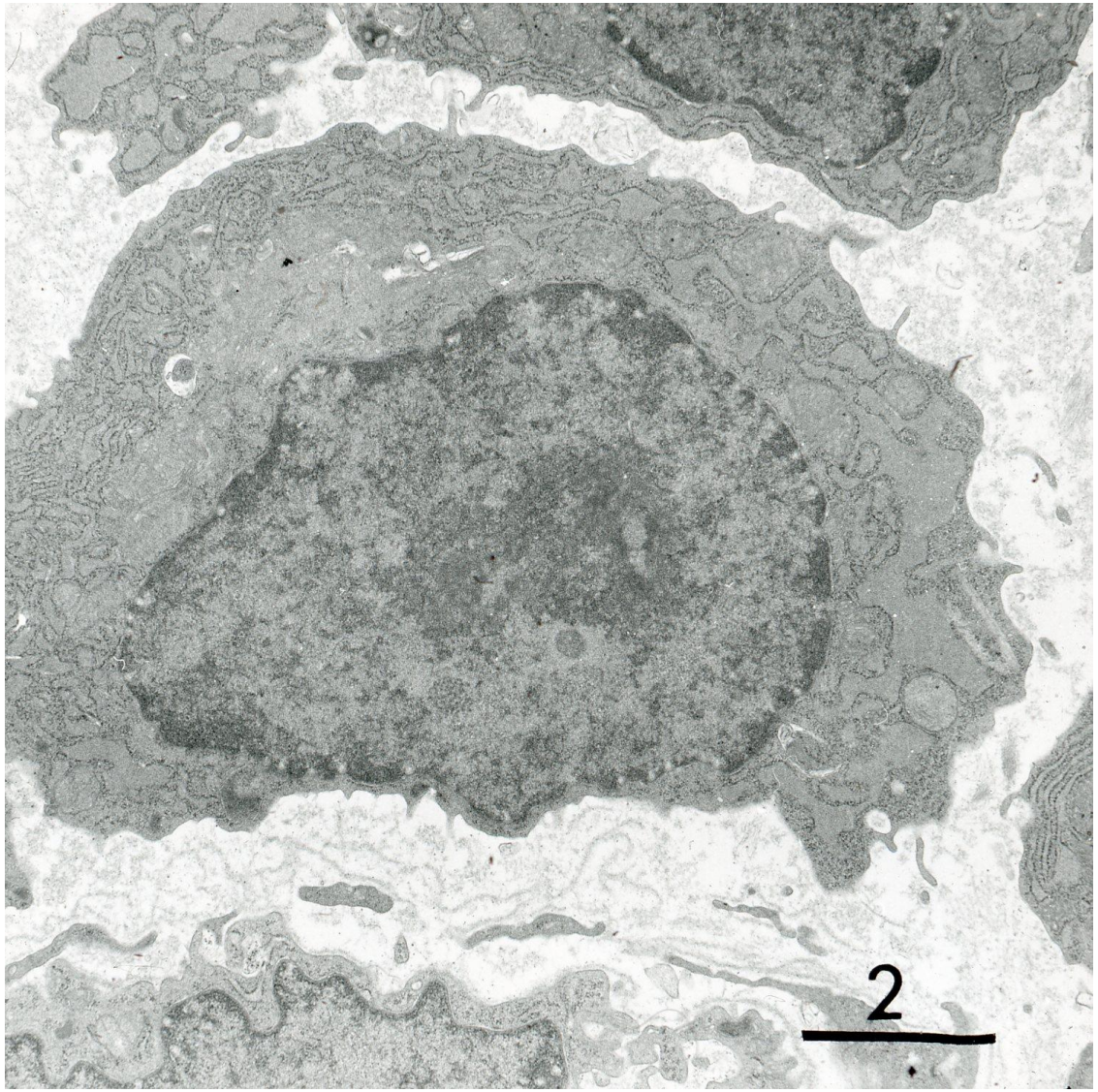

Ultrastructure of a lymphoplasmacytoid cell in Waldenström's macroglobulinemia in the bone marrow. Moderately developed rER and Golgi apparatus are noted.

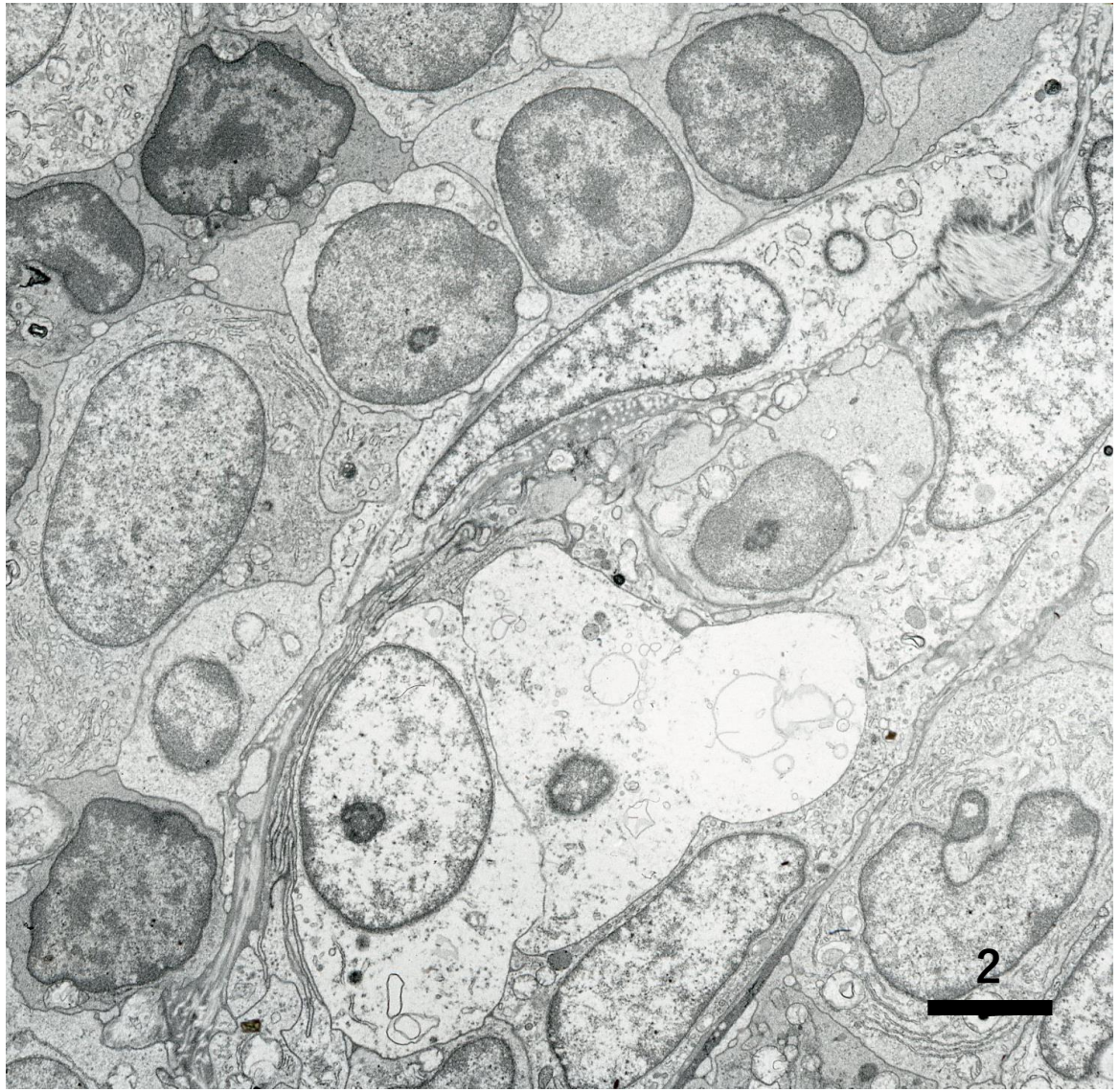

Ultrastructure of post-capillary venule (PCV) in an reactive lymph node. Features of lymphocyte homing (penetration of lymphocytes through the tall endothelial cells) is observed.

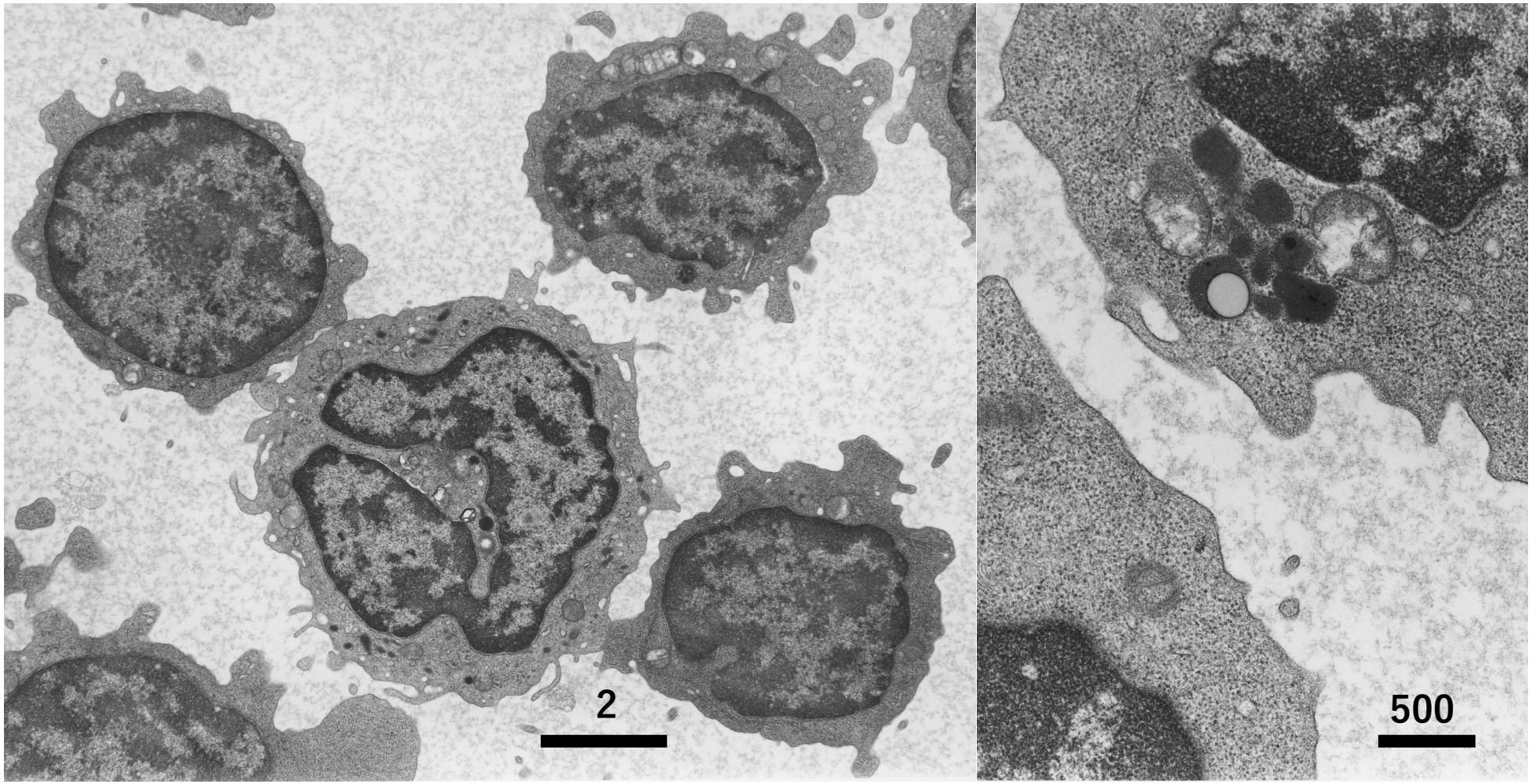

Ultrastructure of T-CLL in the peripheral blood. Small lymphocytes with distinct heterochromatin. Clusterd dense bodies are focally seen in the cytoplasm (right: higher power).

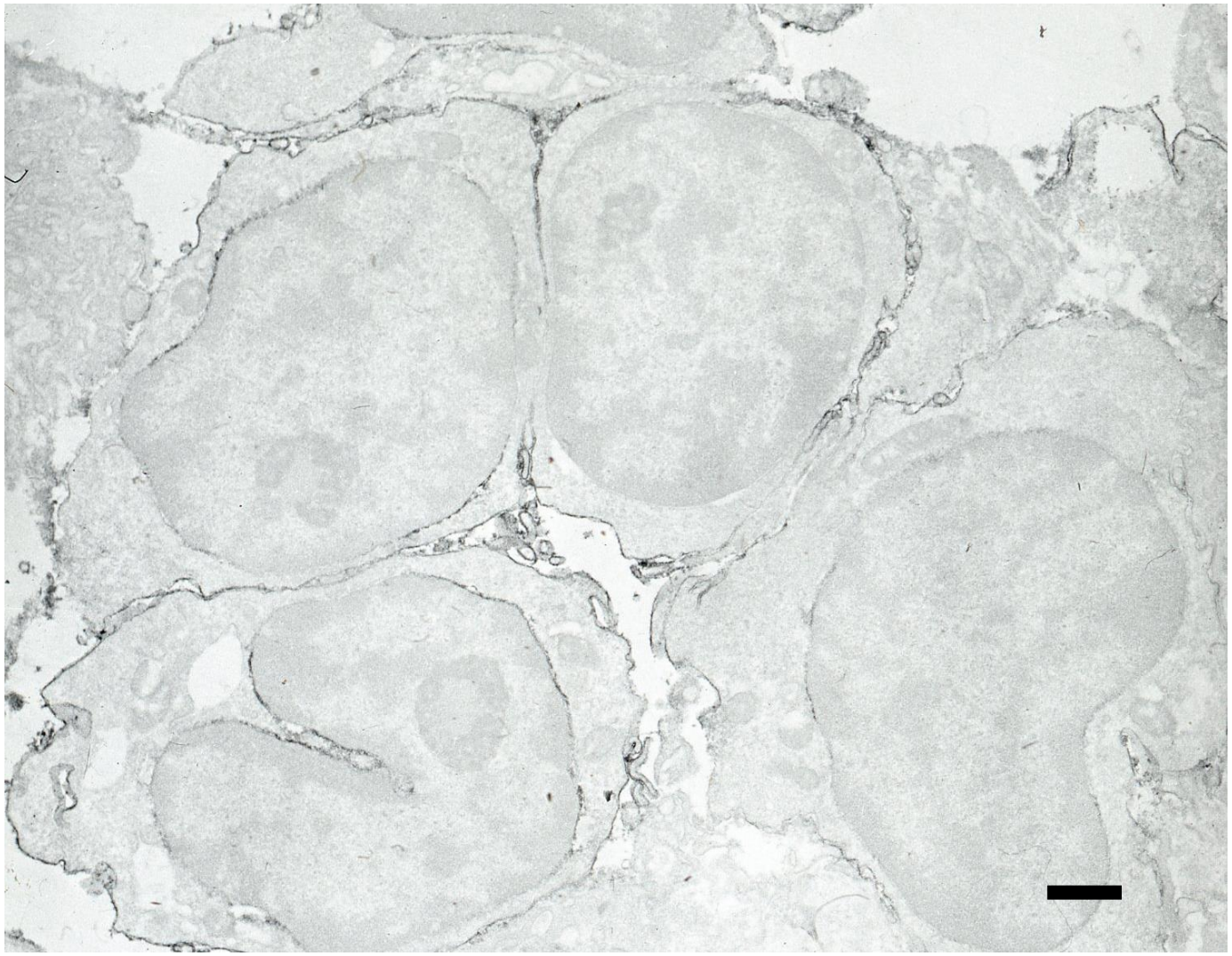

Pre-embedding immunoelectron microscopy for CD3 (tonsil). CD3-positive T-lymphocytes are clustered. CD3 antigen is localized both on the plasma membrane and along the perinuclear space.

Ultrastructure of Sezary cell in Sezary syndrome in the peripheral blood. A cerebriform (convoluted) nucleus is characteristic.

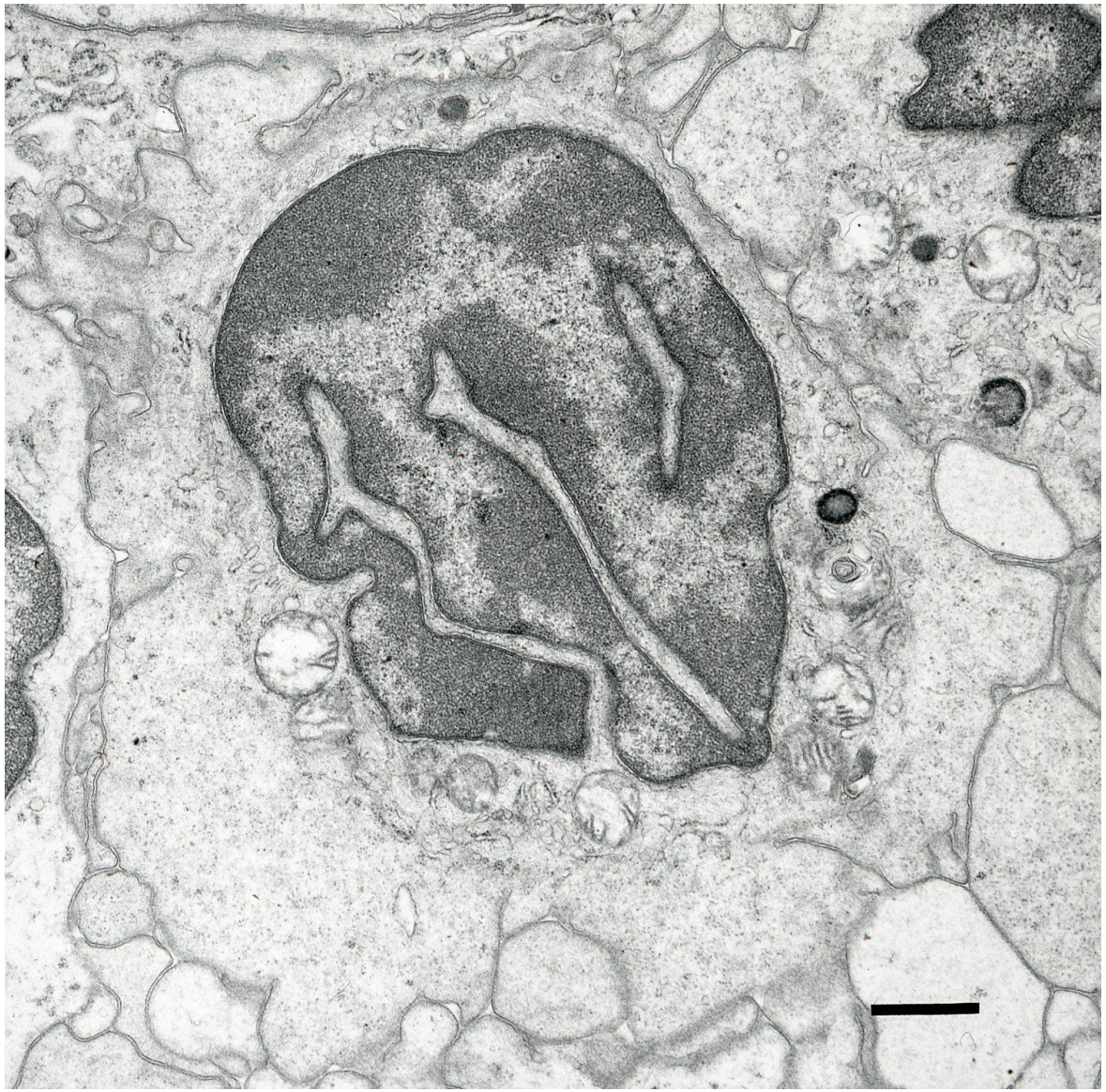

Ultrastructure of mycosis fungoides in the skin. A cerebriform (convoluted) nucleus is located in the center of the lymphoma cell.

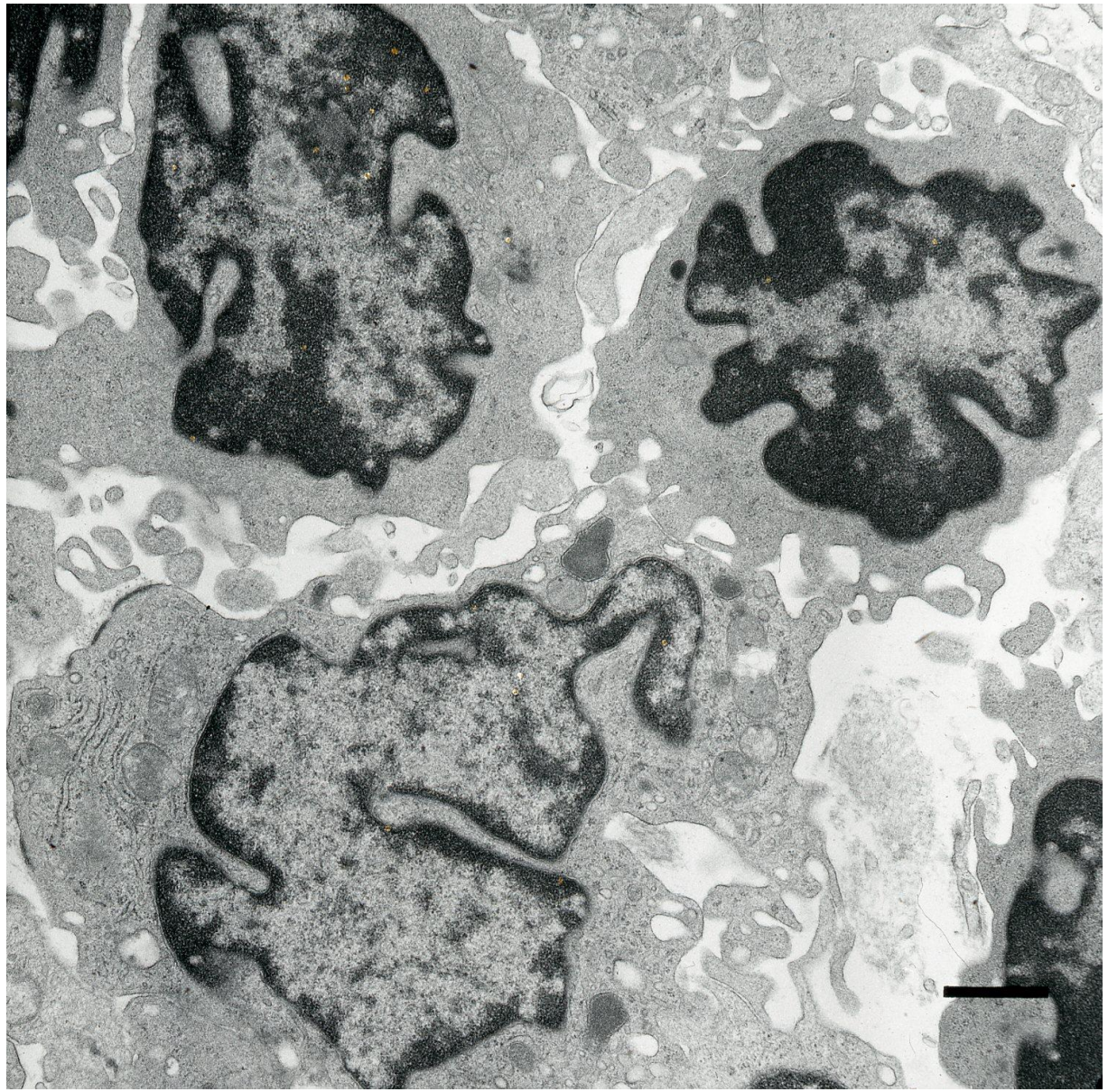

Ultrastructure of adult T-cell leukemia/lymphoma involving the skin. Convoluted nuclei are characteristic.

Ultrastructure of lymphoblastic lymphoma in the ascites. An immature T-lymphocyte possesses poorly developed organellae.

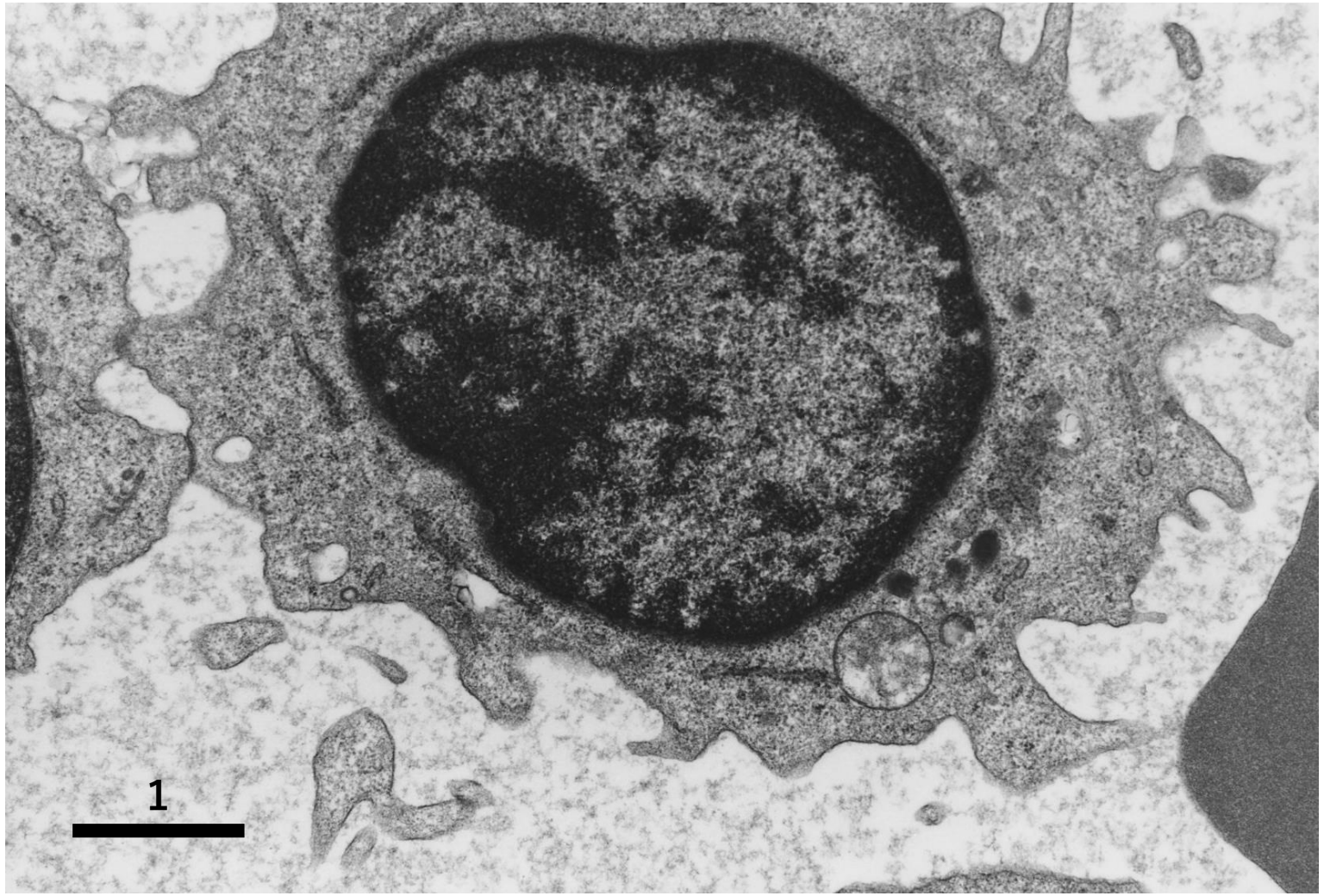

Ultrastructure of large granular lymphocytic leukemia (NK cell leukemia) in the peripheral blood. Killer cell-type, electron-dense granules are scattered in the cytoplasm.

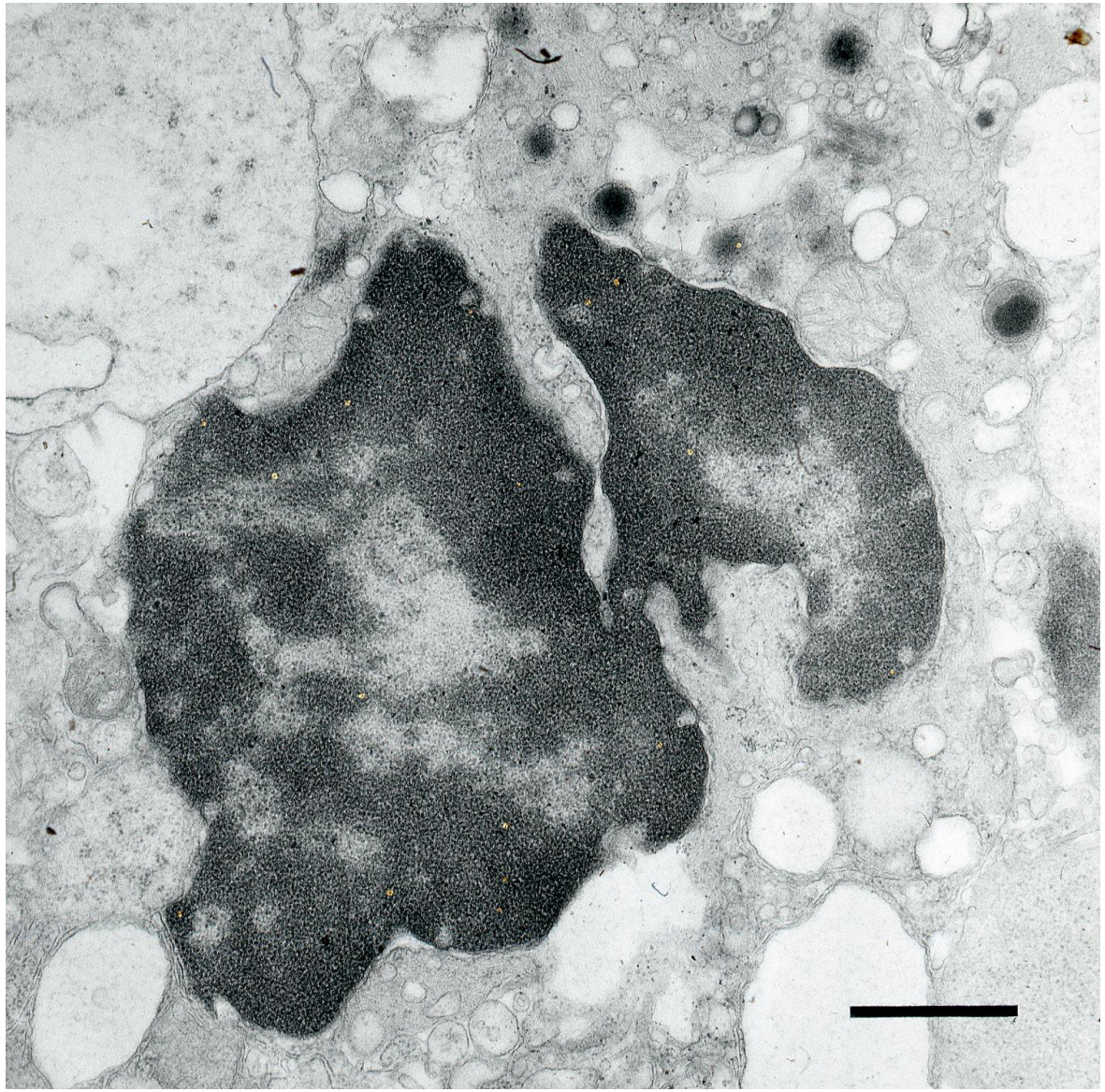

Ultrastructure of nasal NK cell lymphoma. Electron-dense granules are seen in the cytoplasm.

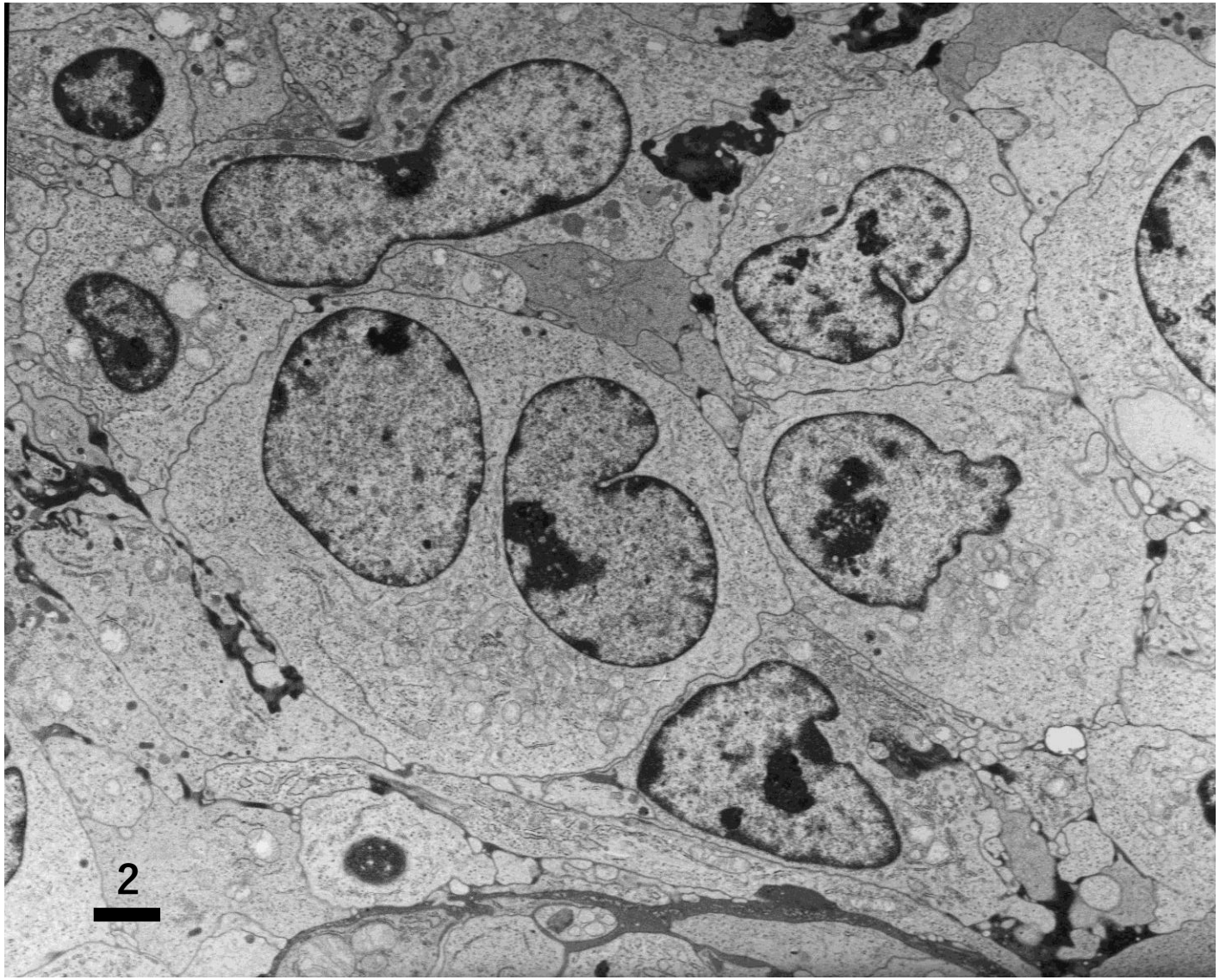

Ultrastructure of Ki-1 lymphoma in the lymph node. Large-sized lymphoma cells resembling Hodgkin's cells are seen.

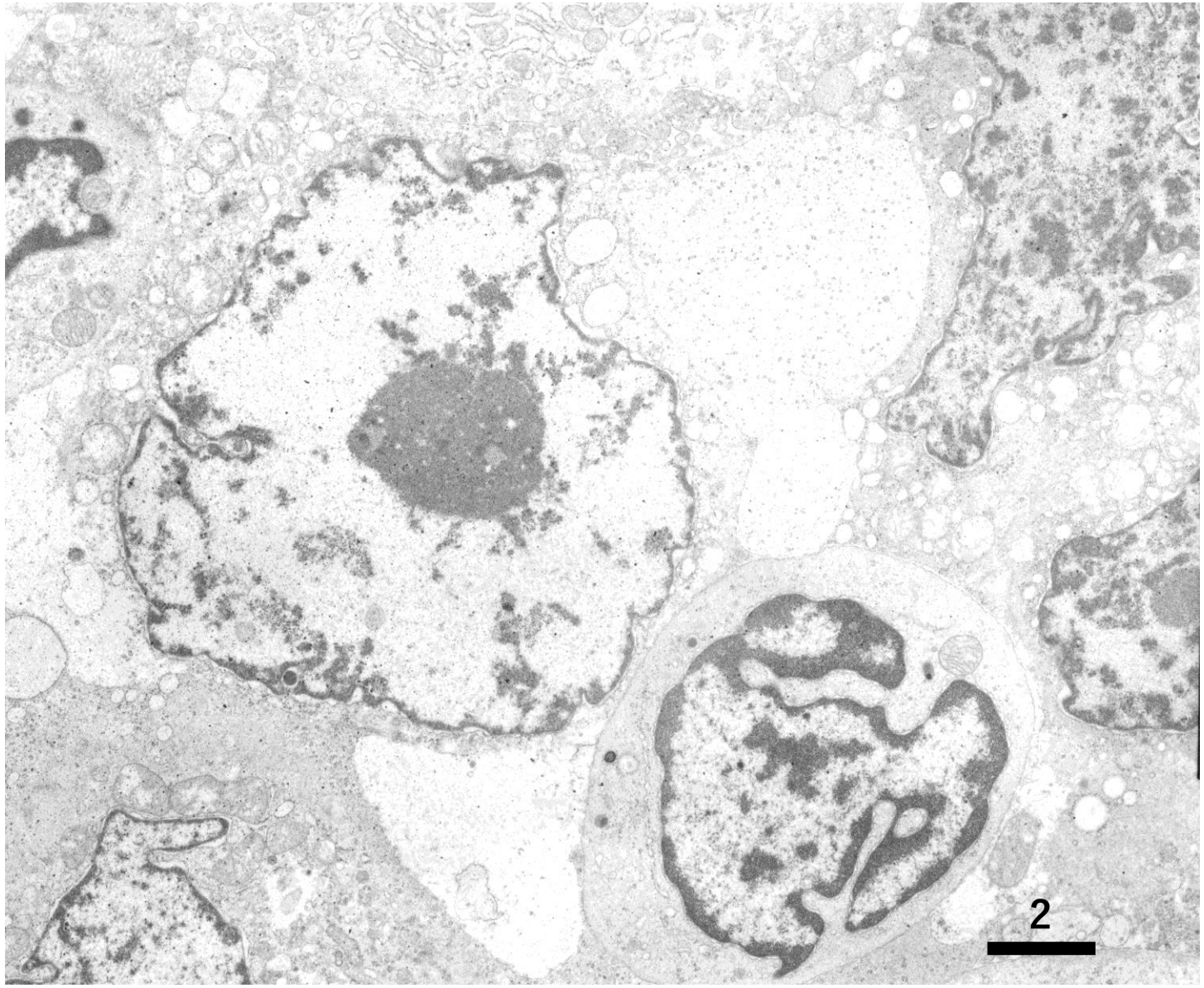

Ultrastructure of Hodgkin's cell in the lymph node. A large-sized cell with poorly developed organellae contains a prominent nucleolus.

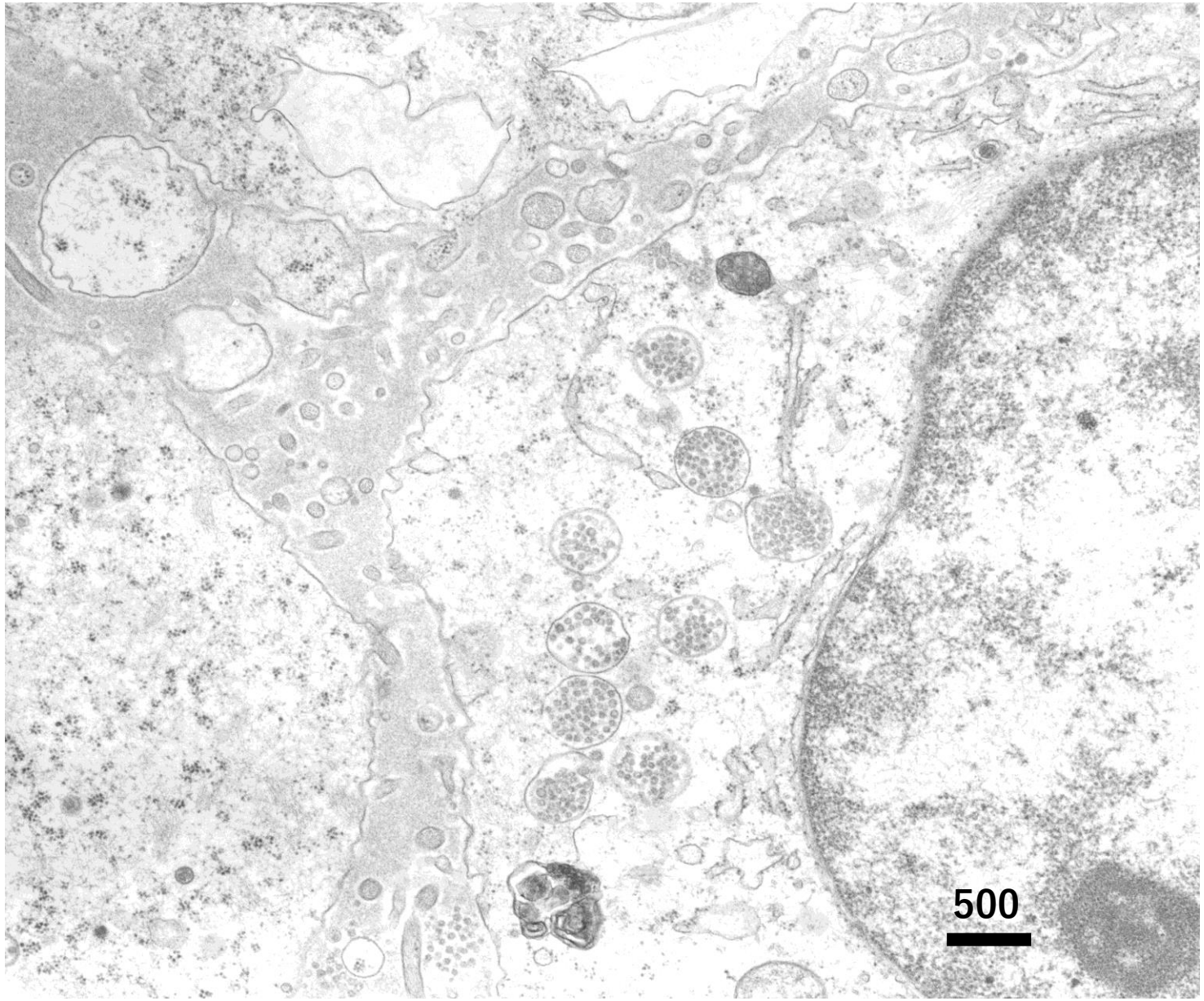

Ultrastructure of immunoblastic lymphoma, microvillous type, involving the jejunum. In addition to microvillous projections along the plasma membrane, multivesicular bodies are clustered.

Ultrastructure of erythrophagocytosis by a macrophage (lymph node). Erythrocyte (E) is phagocytized by the macrophage, and degraded cell debris is seen in activated lysosomes (E1/P).

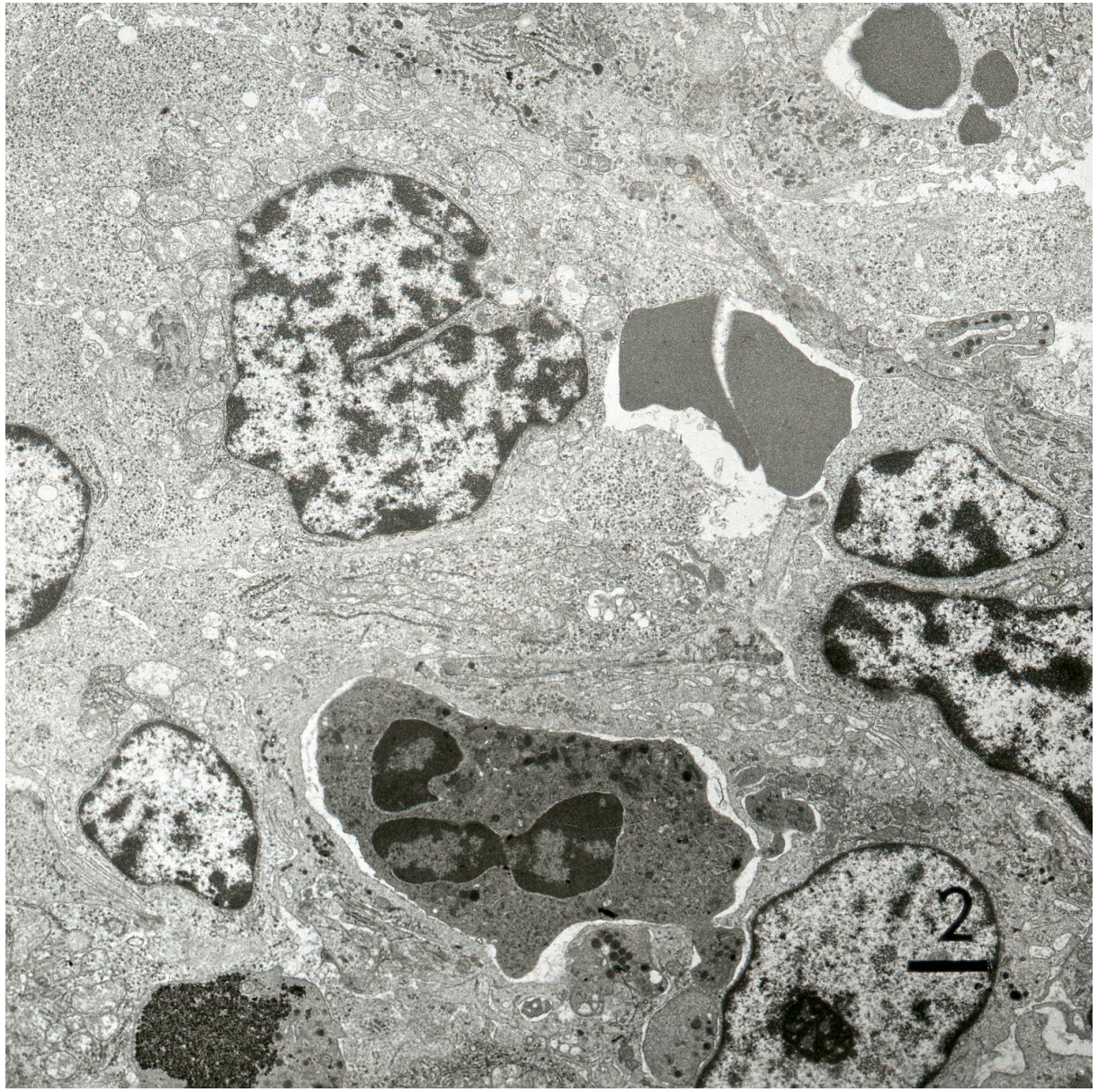

Ultrastructure of hemophagocytosis in the spleen. A neutrophil and platelets are phagocytized by an activated macrophage.

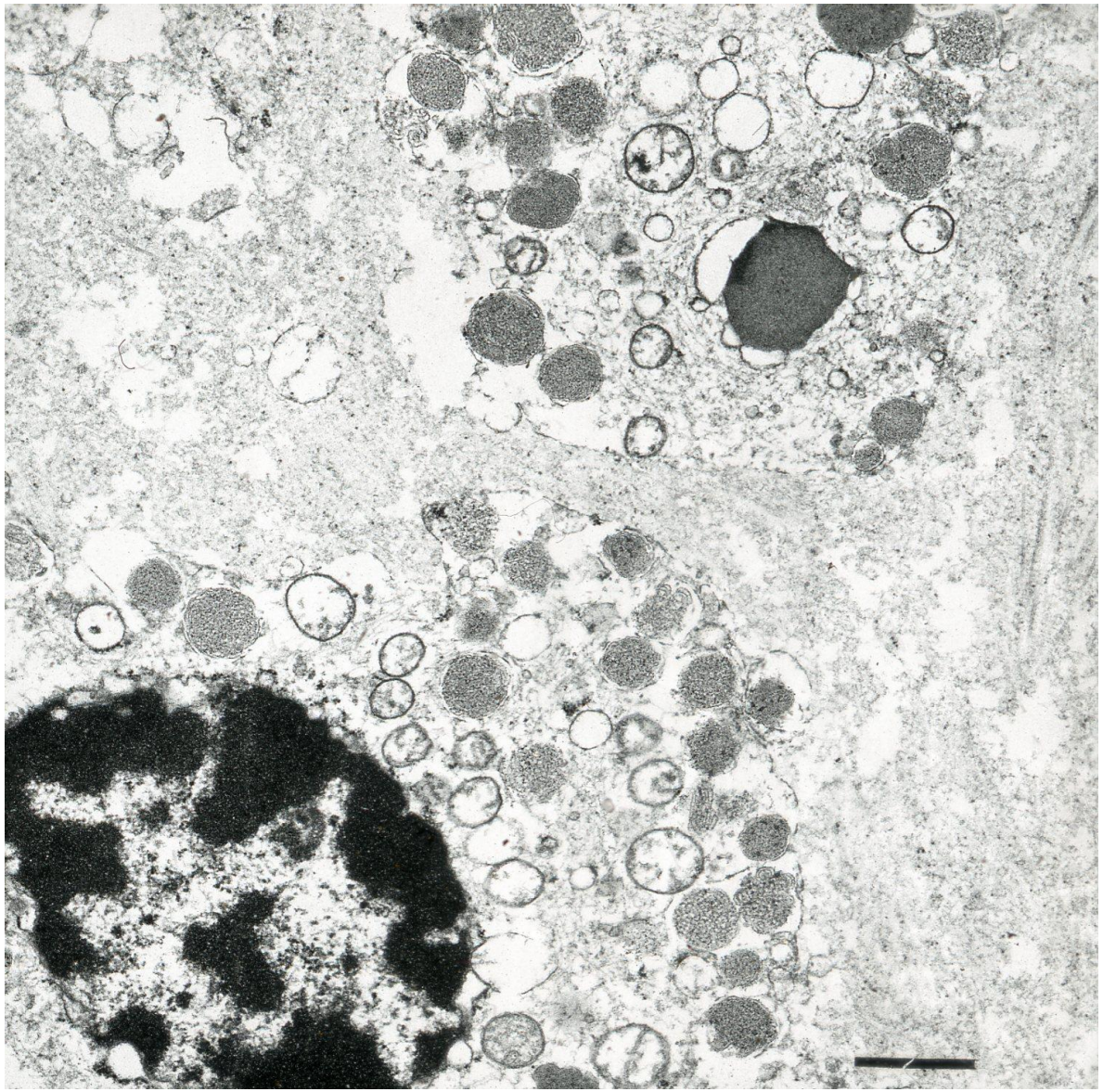

Ultrastructure of mastocytosis involving the colon.
Round granules with fingerprint appearance are noted.

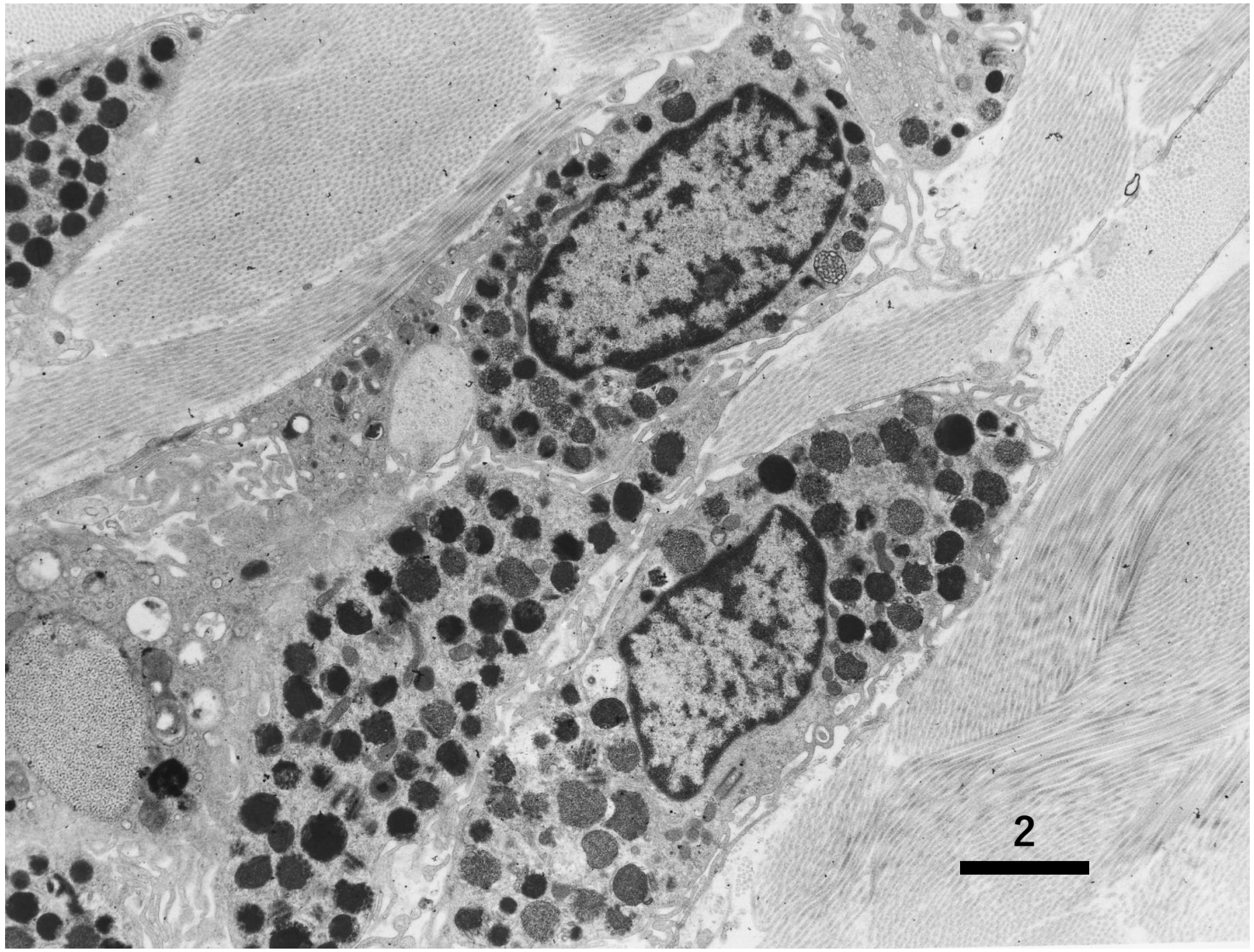

Ultrastructure of mastocytosis involving the skin of a 4-year-old boy. Electron-dense round granules focally with fingerprint appearance are richly distributed in the cytoplasm.

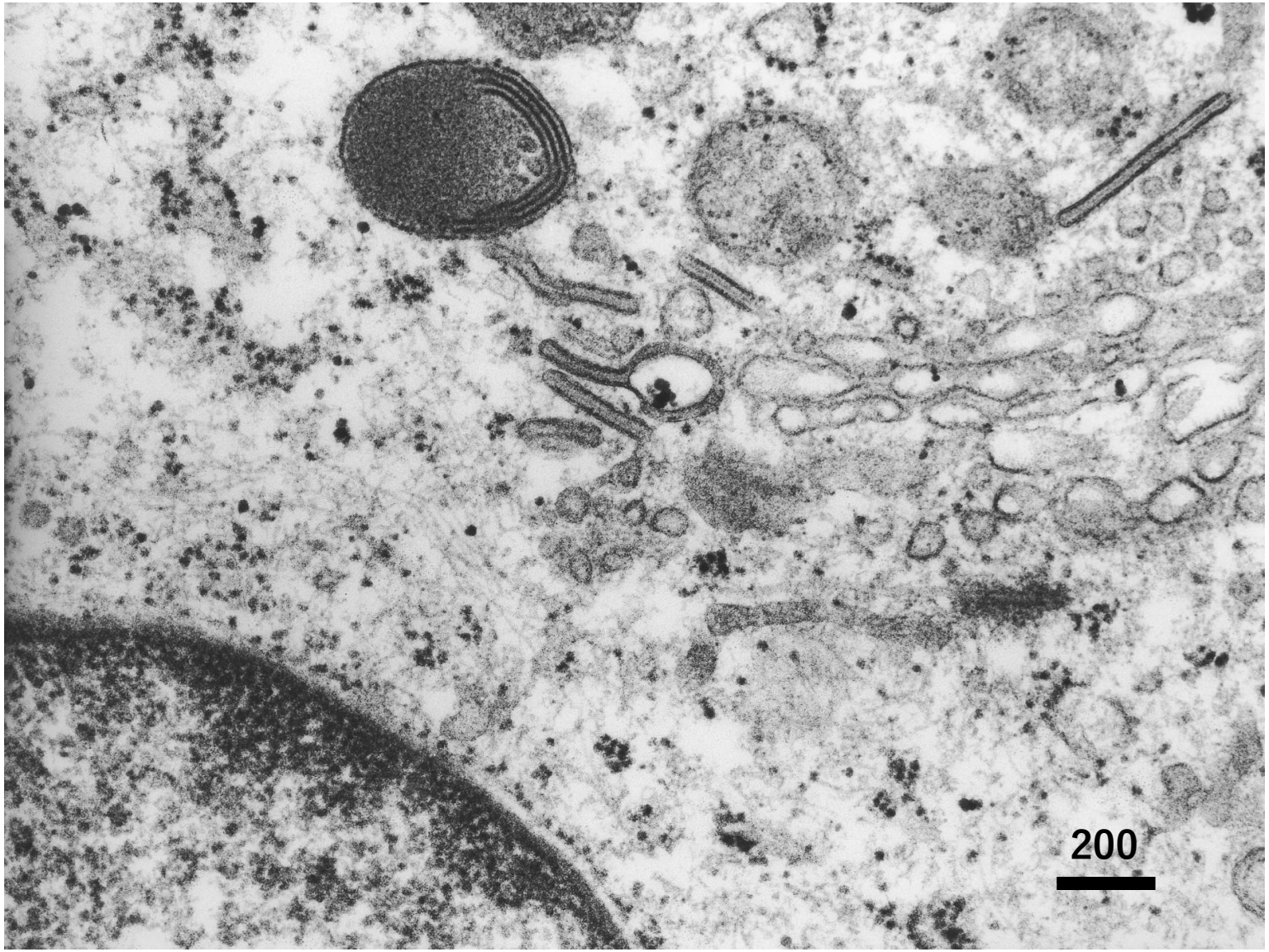

Ultrastructure of Langerhans cell histiocytosis involving the skin. The cytoplasm contains Birbeck granules, rod-shaped or "tennis-racket“-like organelles with a central linear density and a striated appearance.