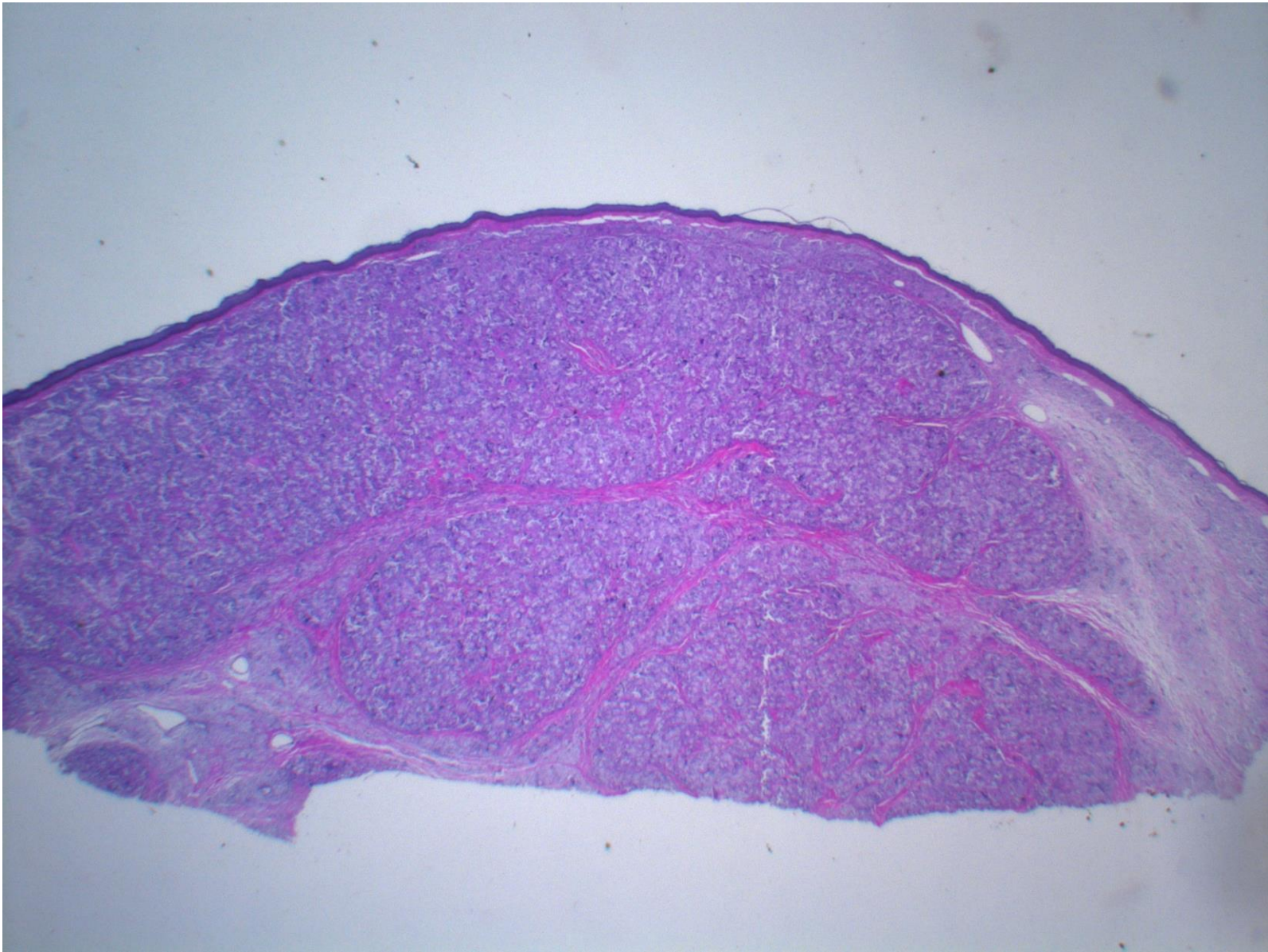
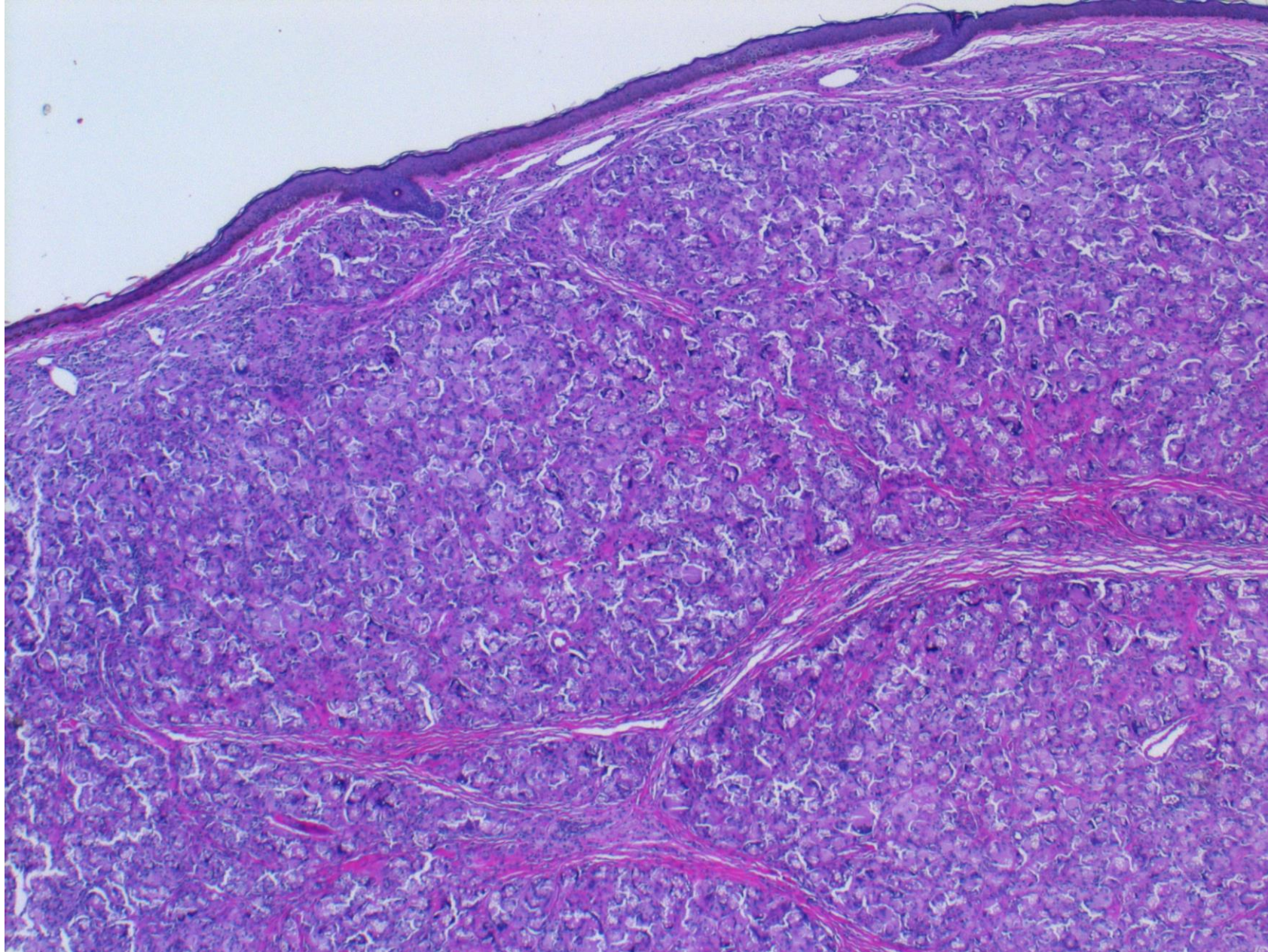


Lobomycosis (leg skin, Brazilian lady, 29F)

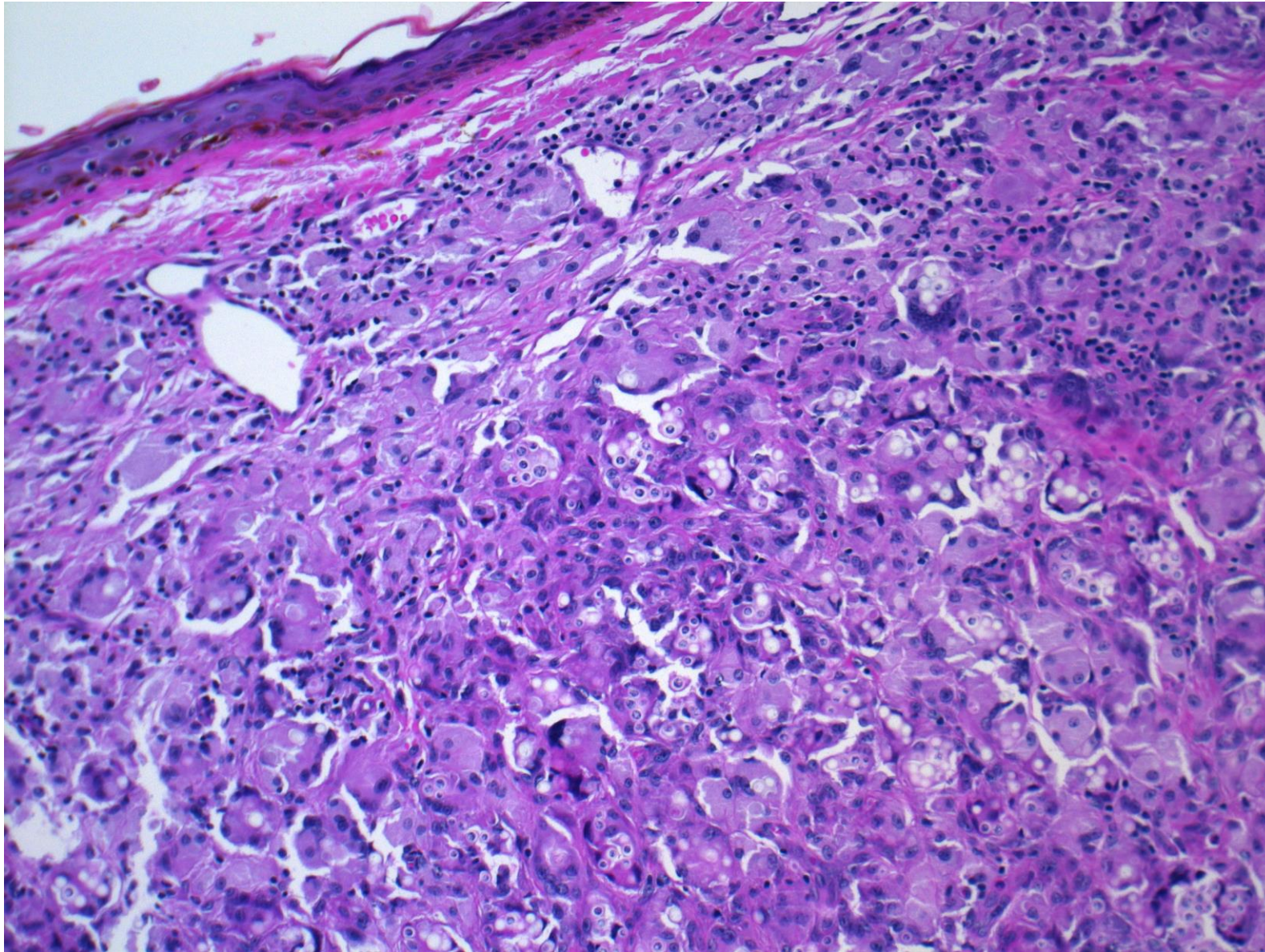
Lobomycosis is a fungal infection of the skin endemic in South and Central America. Infection most commonly develops after minor scratches or insect bites. The pathogen is *Lacazia loboi* (formerly named *Loboa loboi*). Direct contact with an infected dolphin also mediates the mycosis. Keloid-like indurated nodules are formed on the ear, leg or arm. The disease is acquired from the environment (no human-to human transmission seen). Microscopically, demarcated granulomatous inflammation with multinucleated giant cells is noted. Numerous oval-shaped yeasts are phagocytized by multinucleated giant cells. PAS and Grocott stains clearly demonstrate the pathogens. Fontana-Masson argentaffin stain also gives a positive reaction.



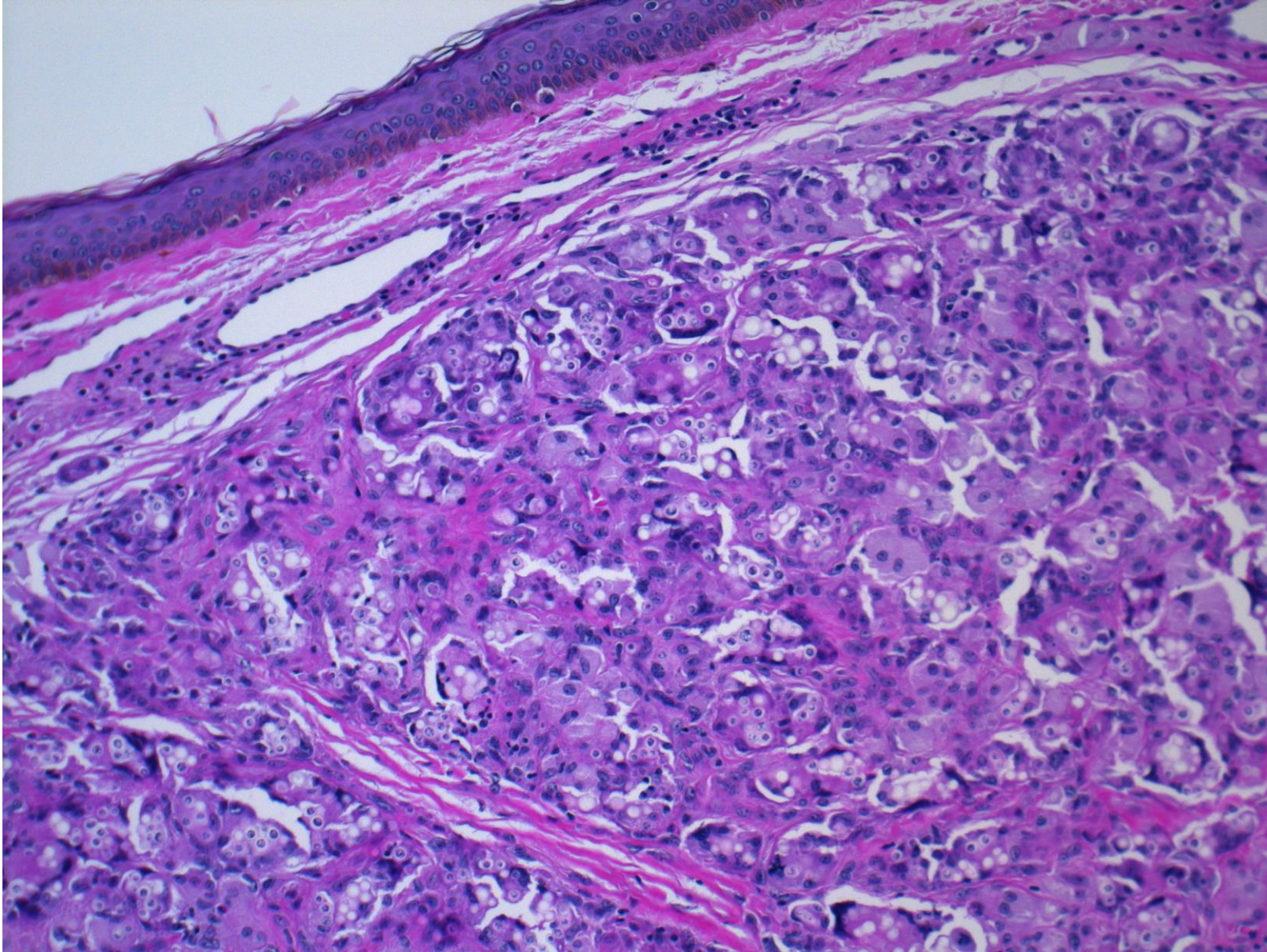
Lobomycosis (leg skin, Brazilian lady, 29F), HE-1



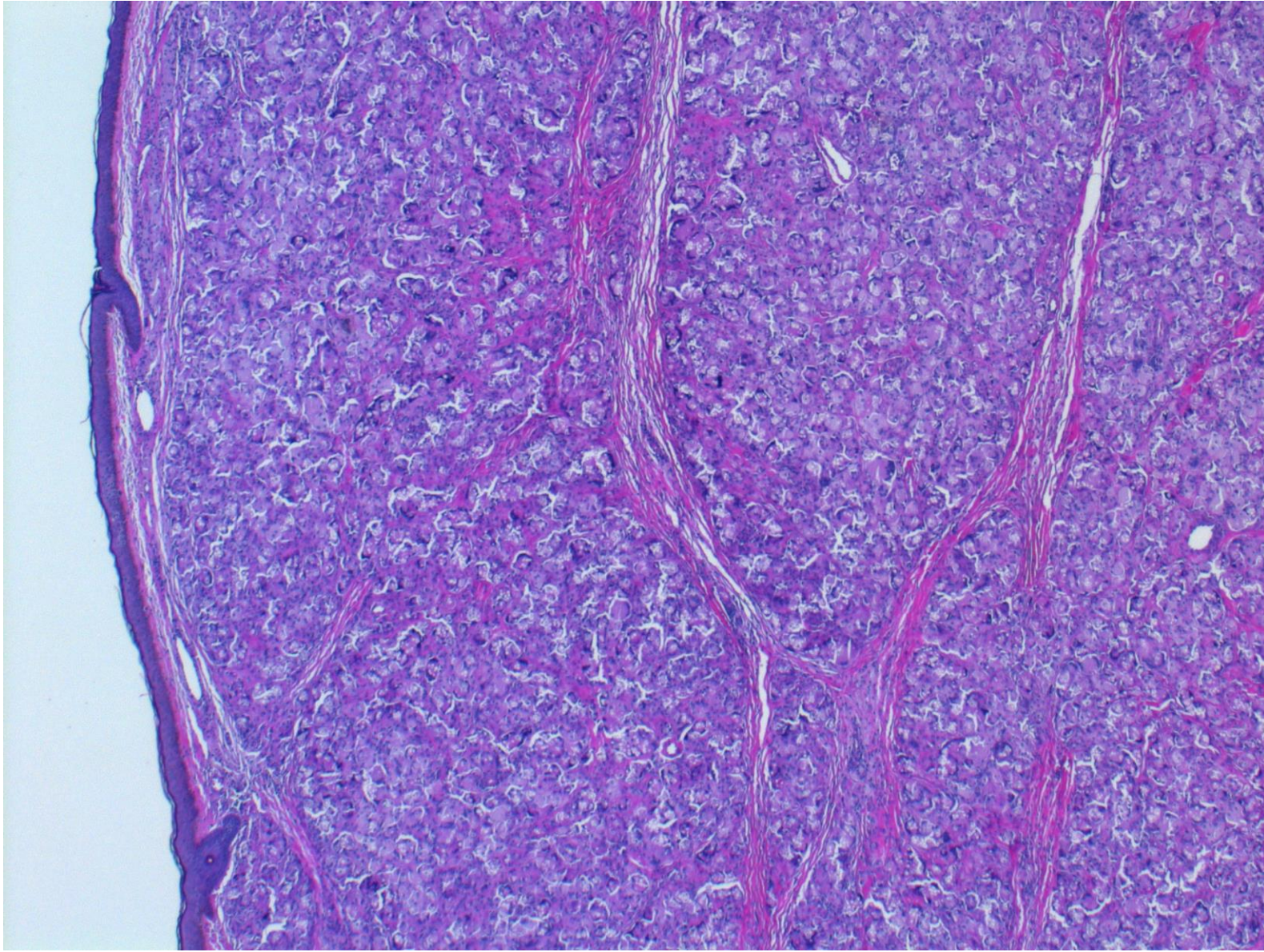
Lobomycosis (leg skin, Brazilian lady, 29F), HE-2



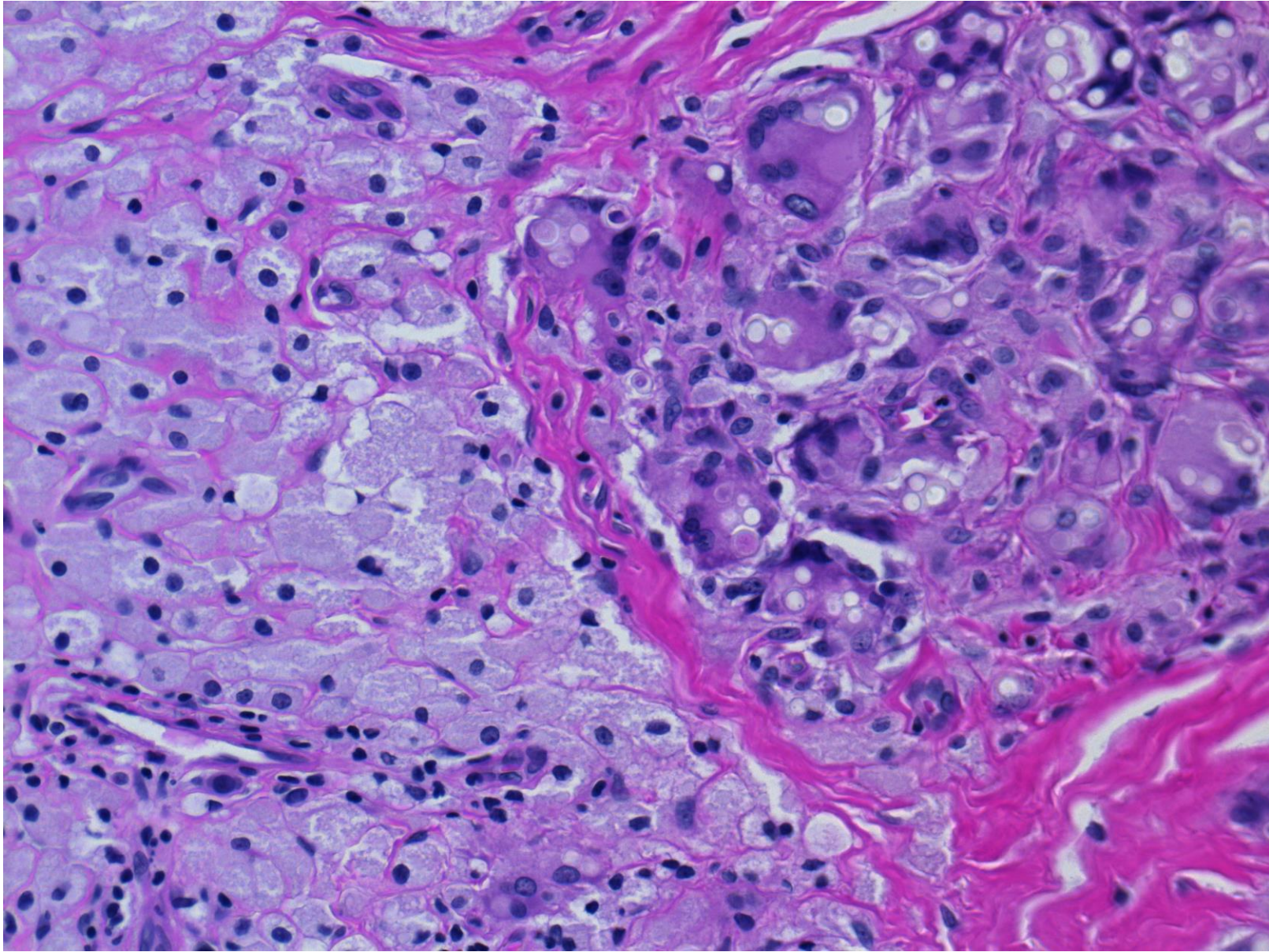
Lobomycosis (leg skin, Brazilian lady, 29F), HE-3



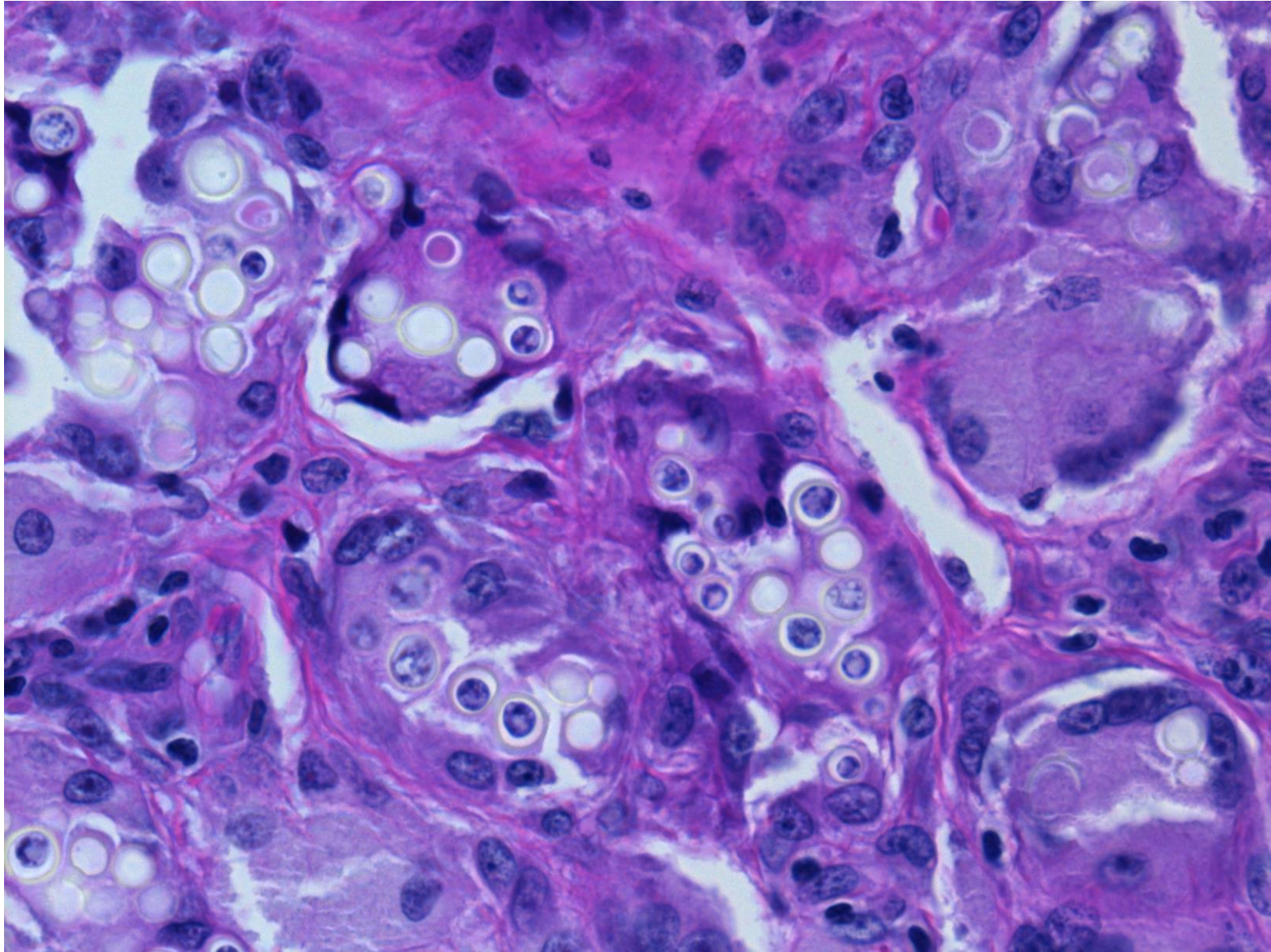
Lobomycosis (leg skin, Brazilian lady, 29F), HE-4



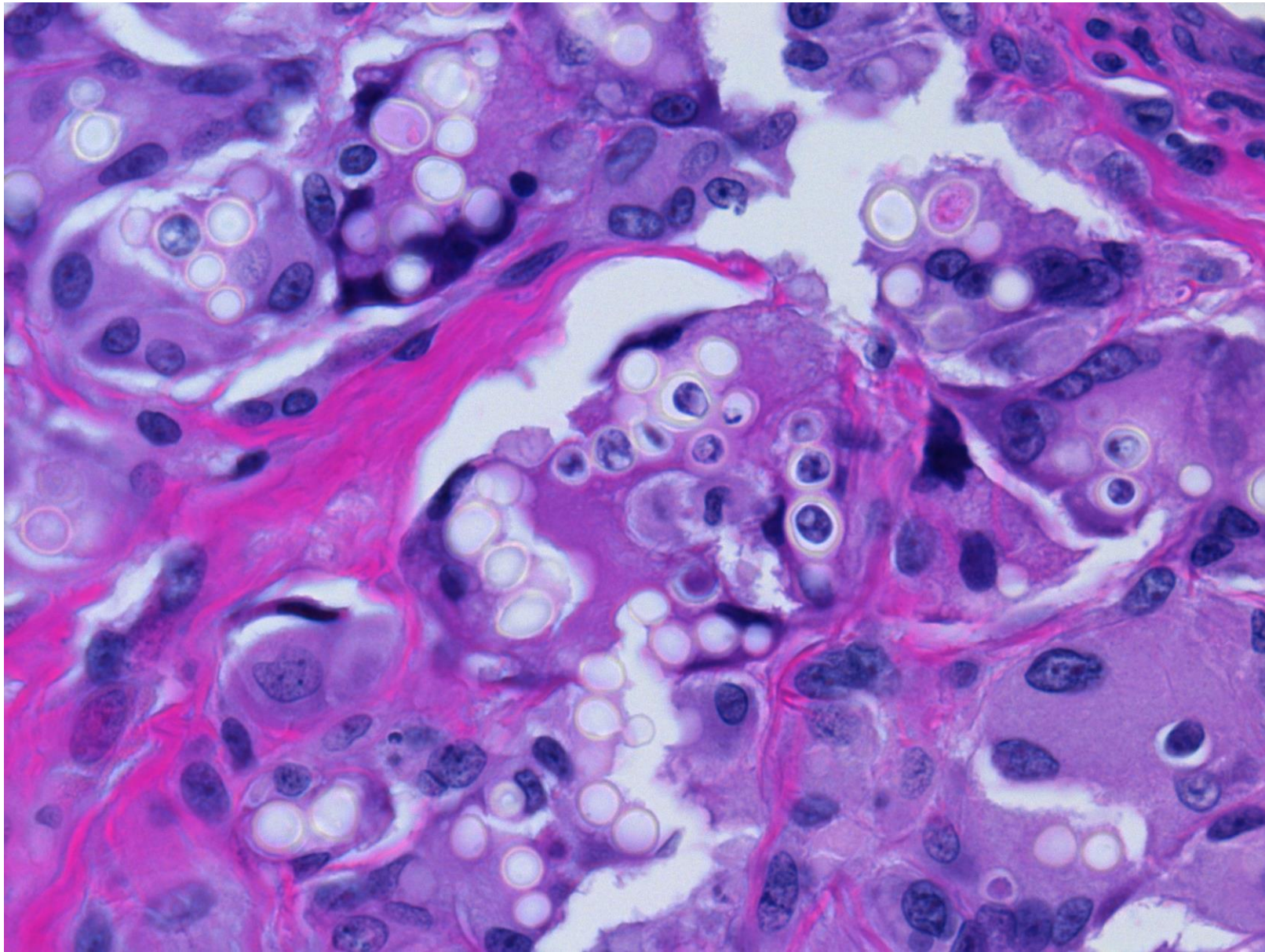
Lobomycosis (leg skin, Brazilian lady, 29F), HE-5



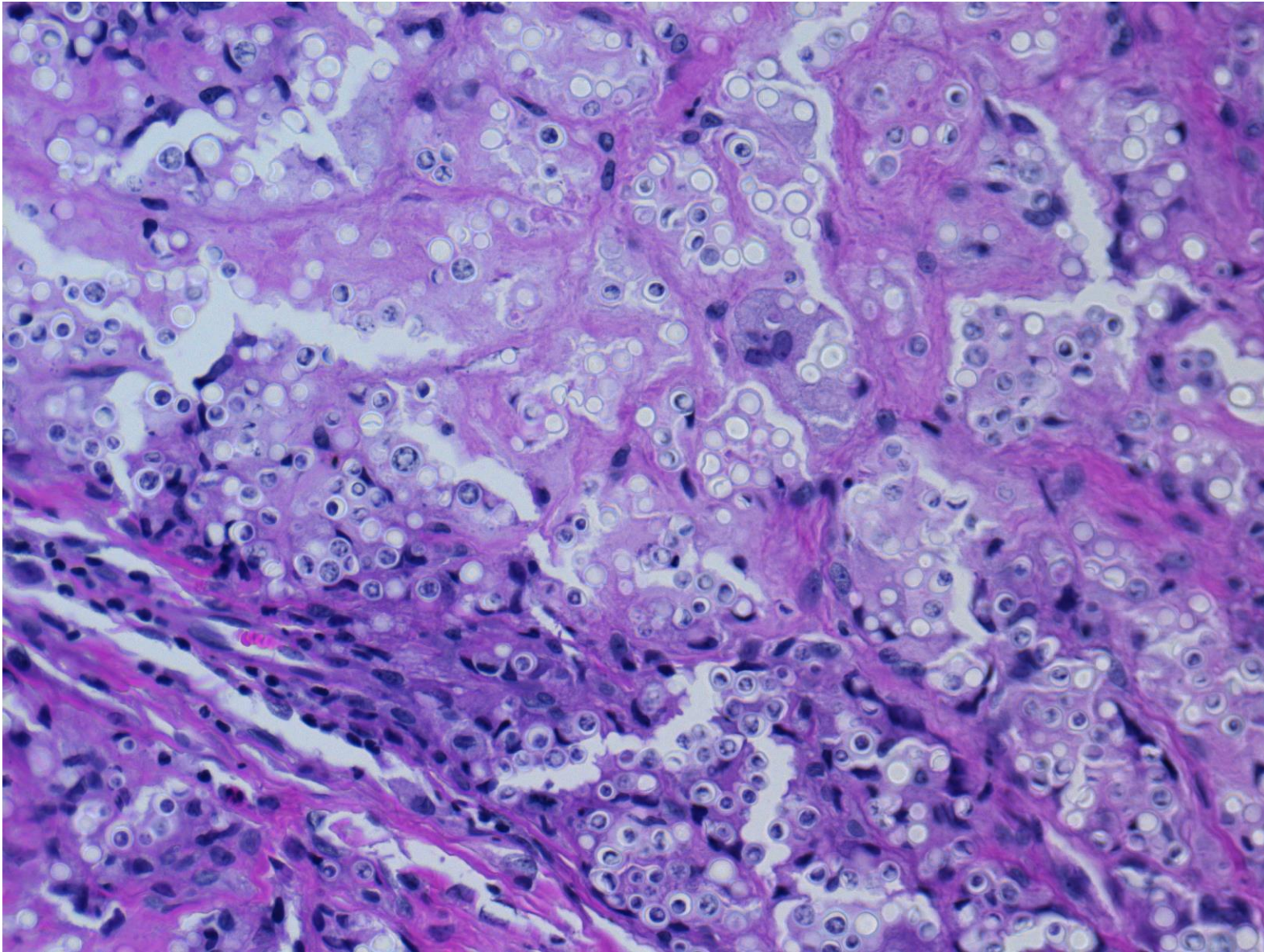
Lobomycosis (leg skin, Brazilian lady, 29F), HE-6



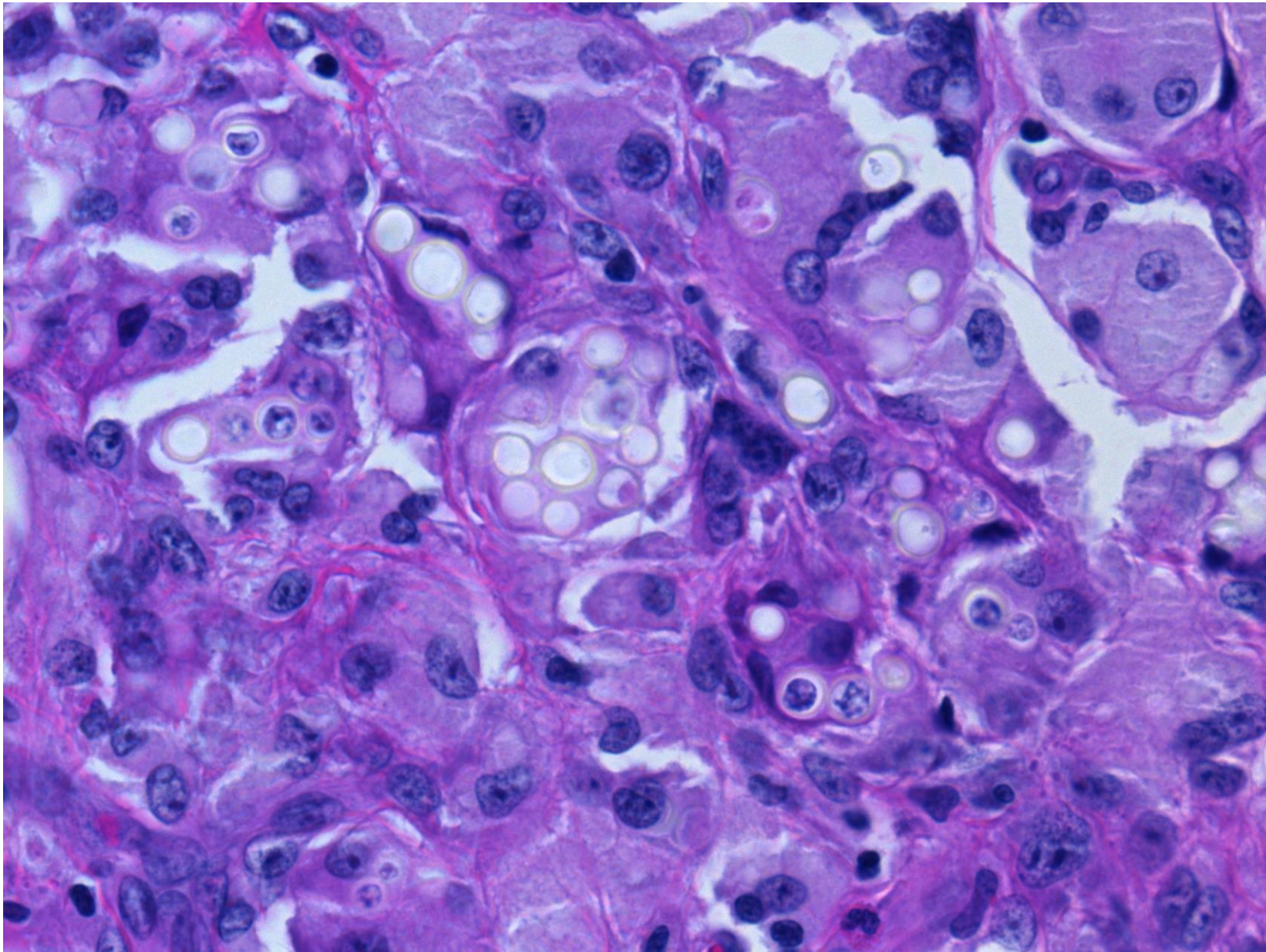
Lobomycosis (leg skin, Brazilian lady, 29F), HE-7



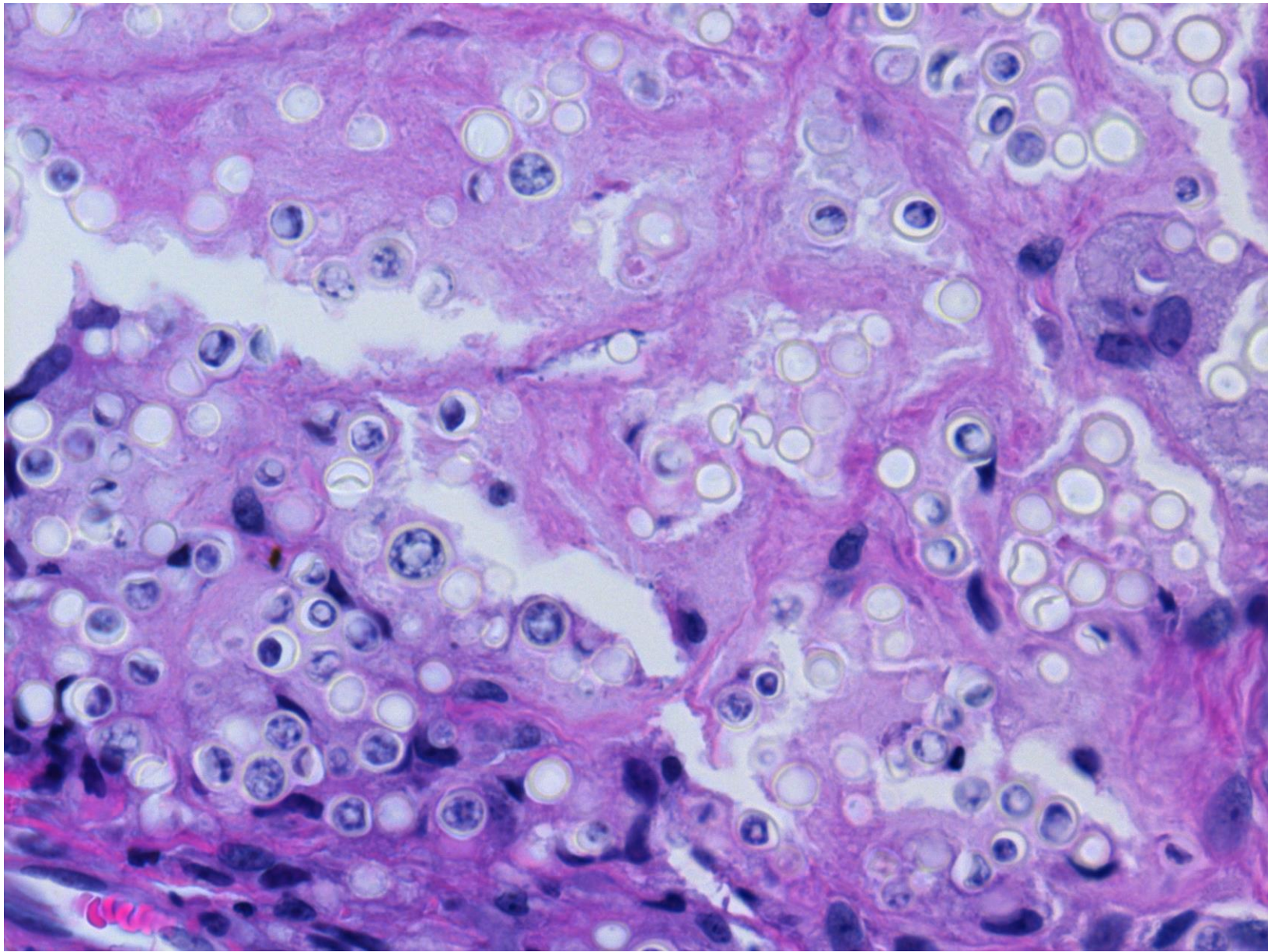
Lobomycosis (leg skin, Brazilian lady, 29F), HE-8



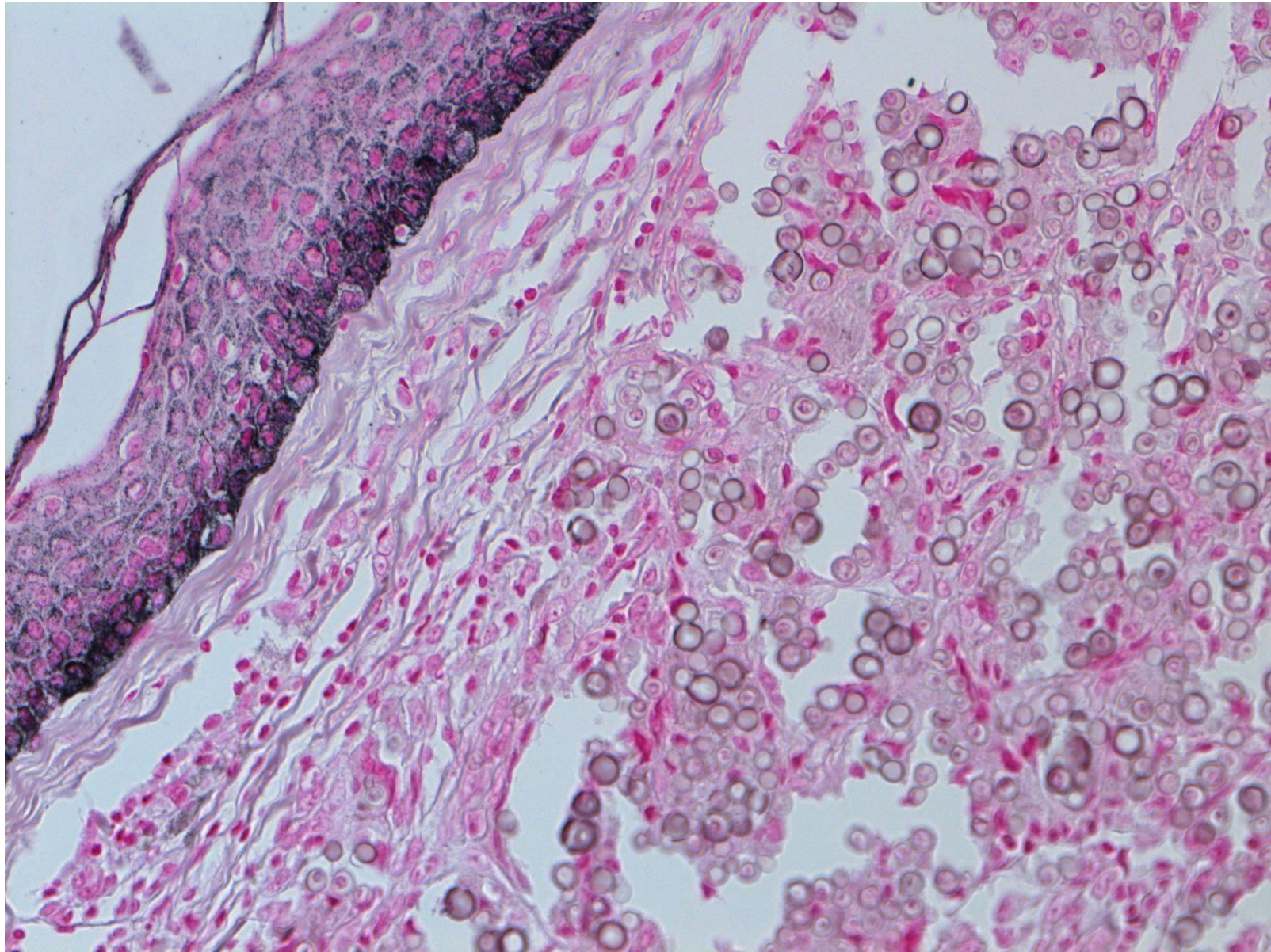
Lobomycosis (leg skin, Brazilian lady, 29F), HE-9



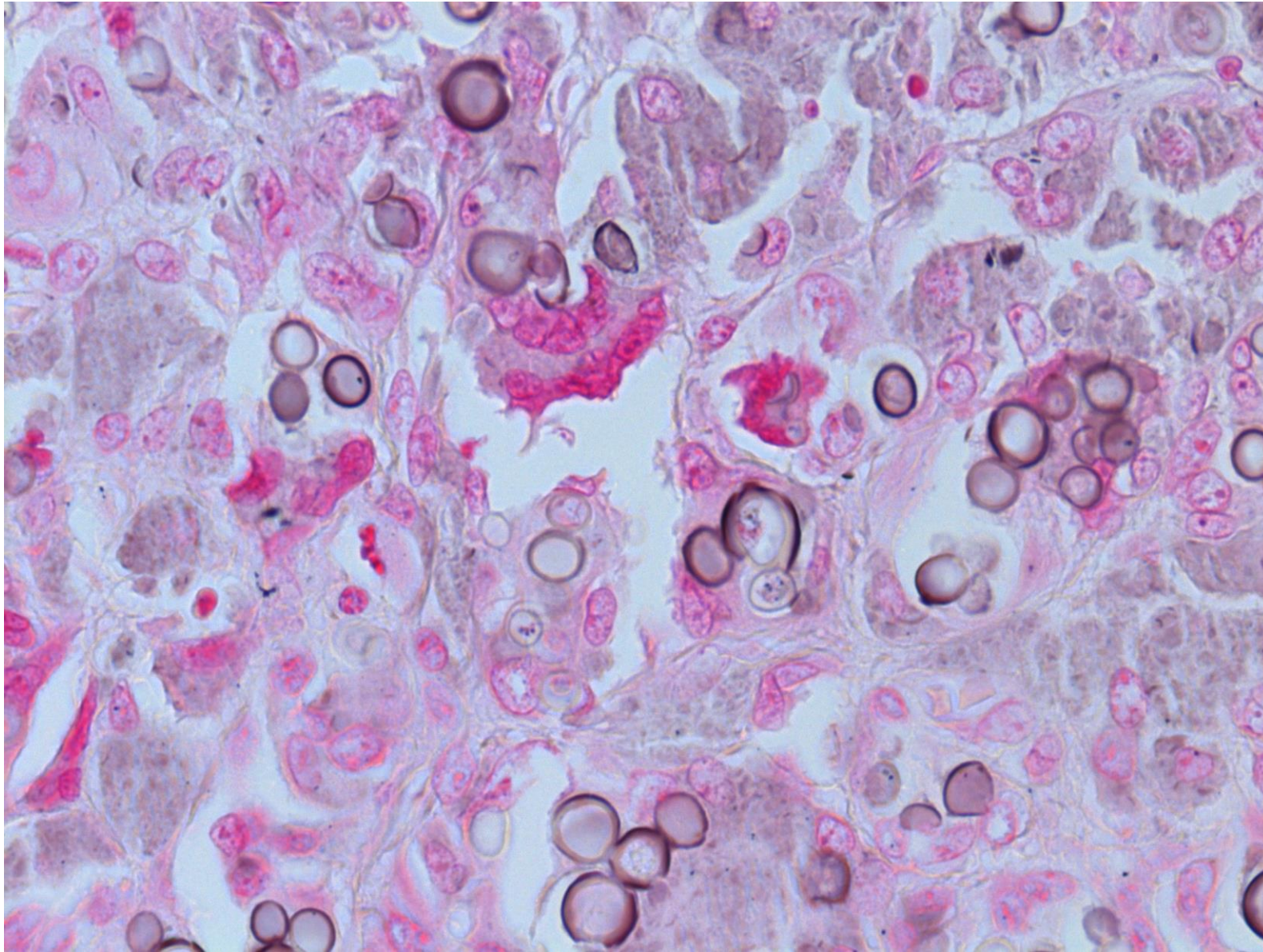
Lobomycosis (leg skin, Brazilian lady, 29F), HE-10



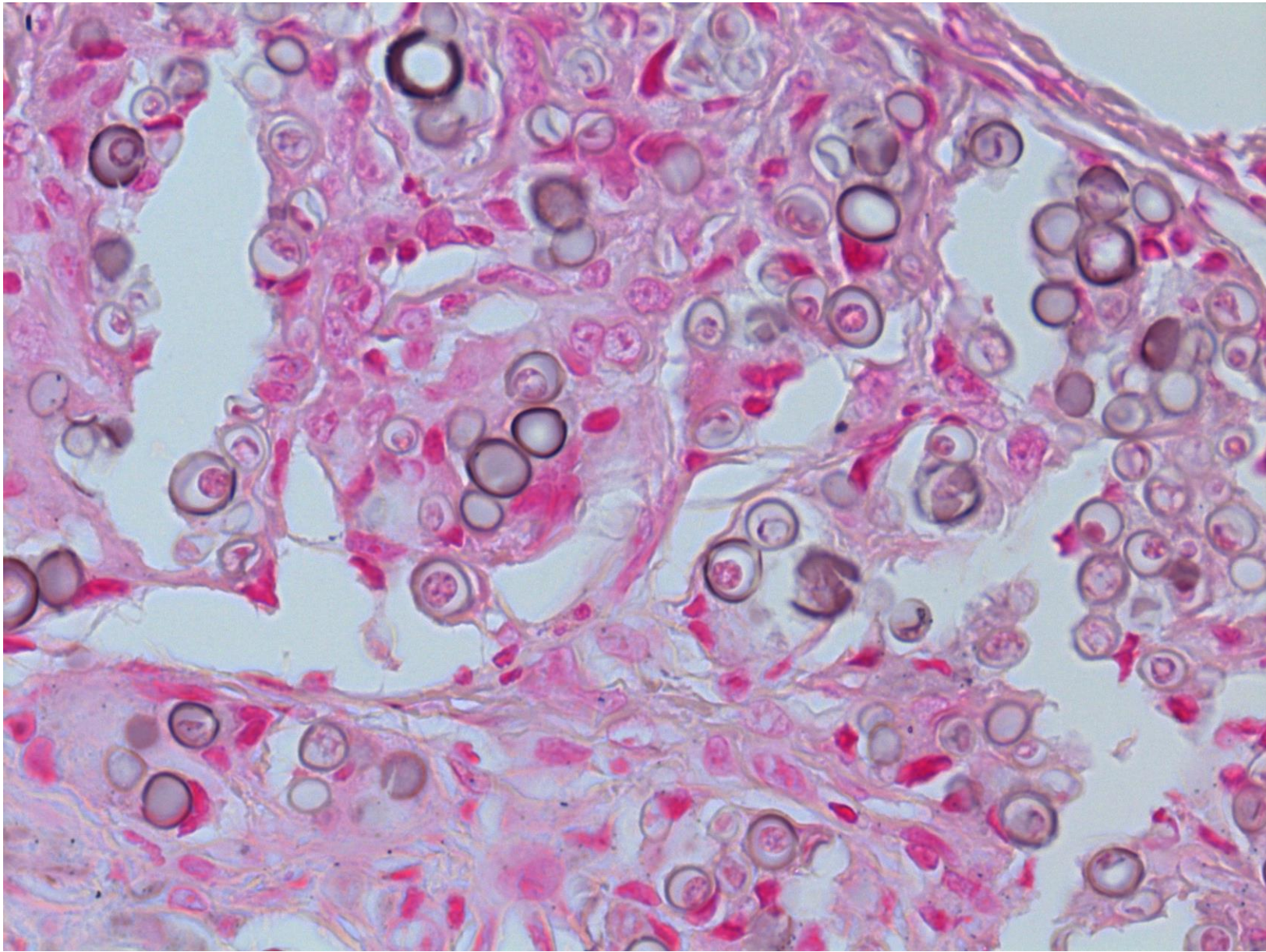
Lobomycosis (leg skin, Brazilian lady, 29F), HE-11



Lobomycosis (leg skin, Brazilian lady, 29F), Fontana-Masson-1



Lobomycosis (leg skin, Brazilian lady, 29F), Fontana-Masson-2



Lobomycosis (leg skin, Brazilian lady, 29F), Fontana-Masson-3