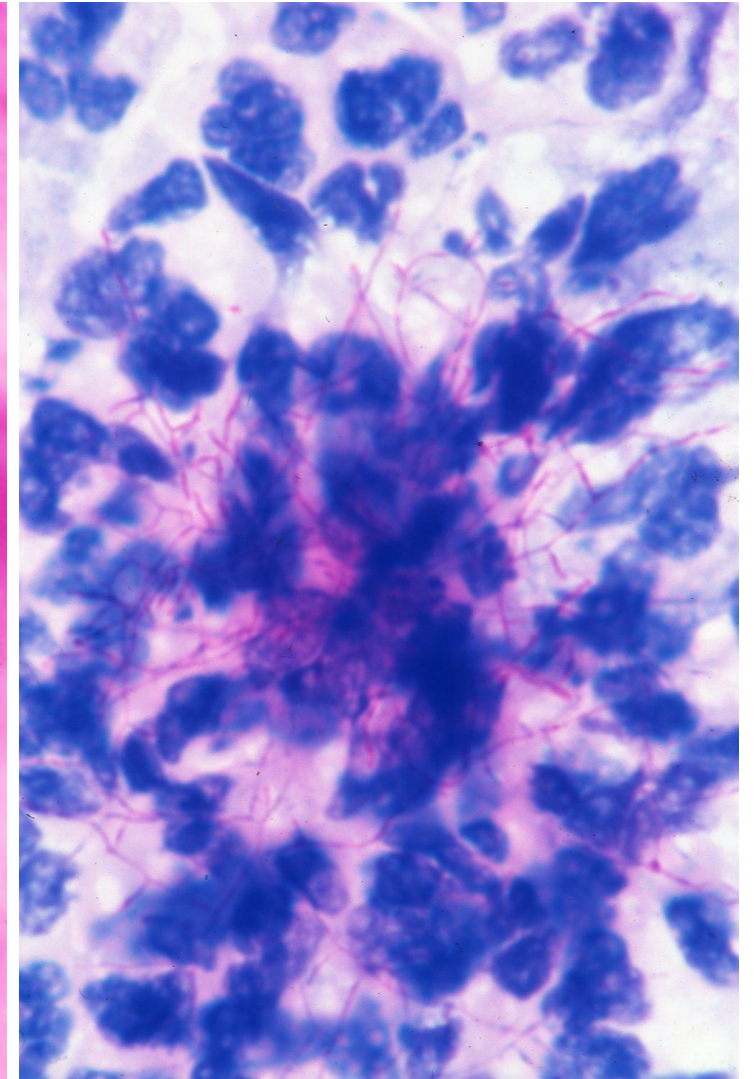
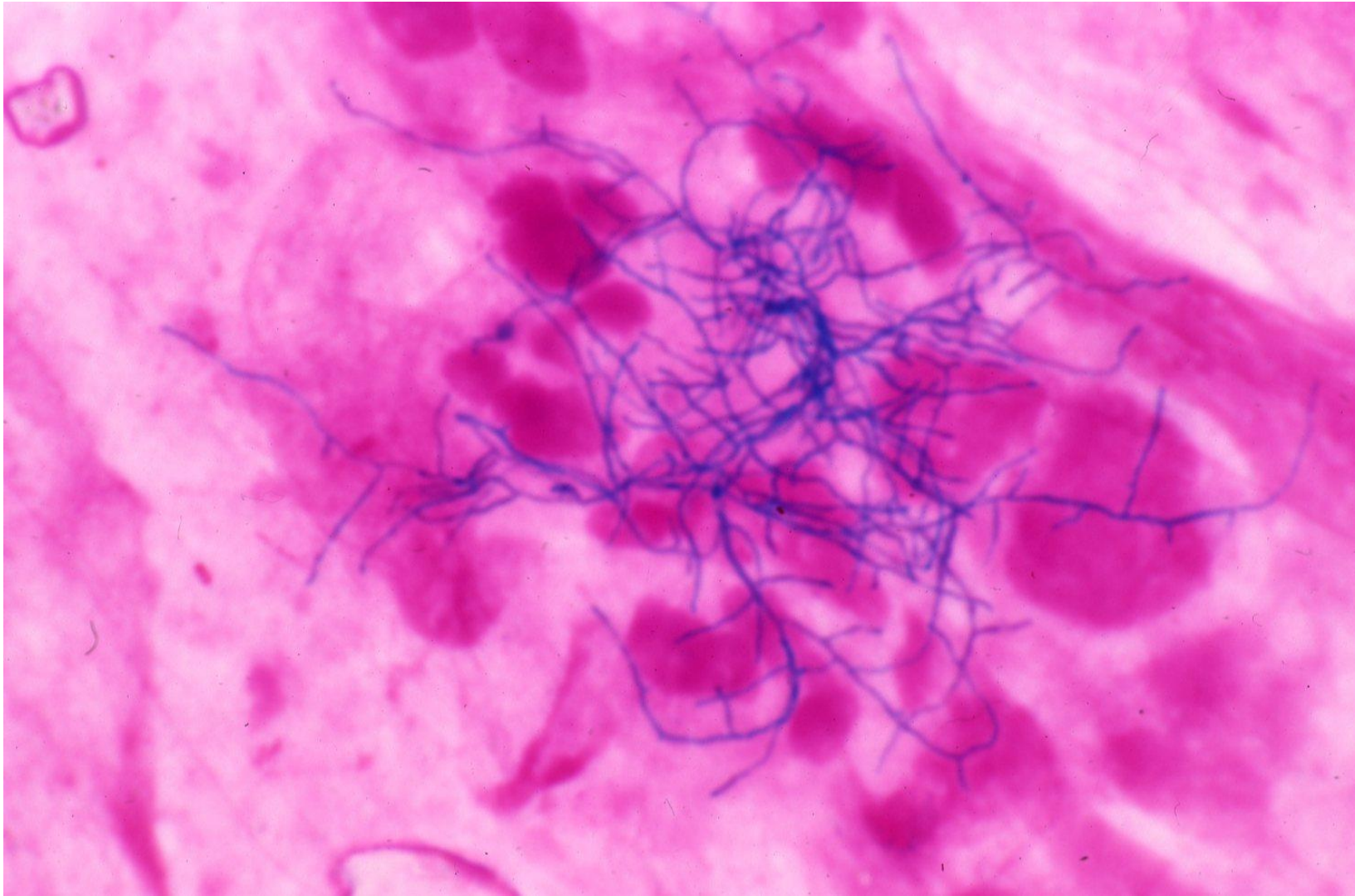
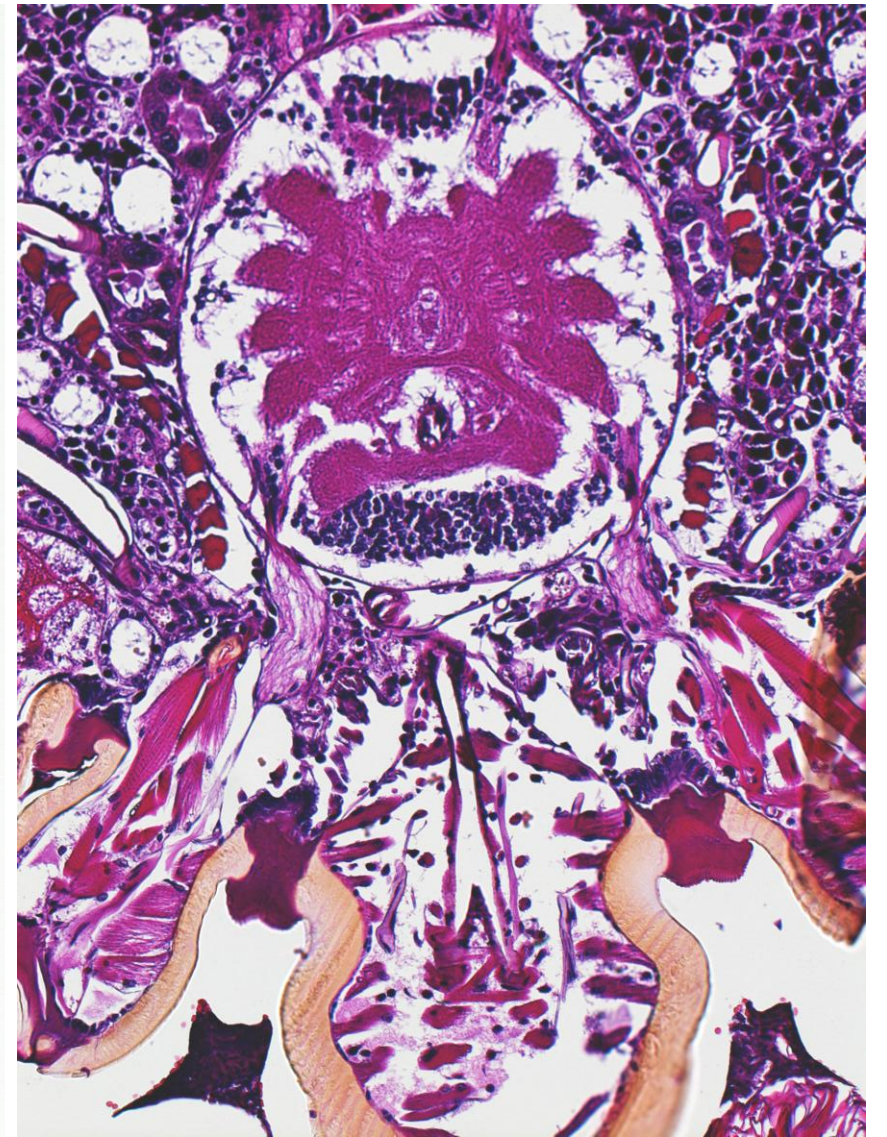
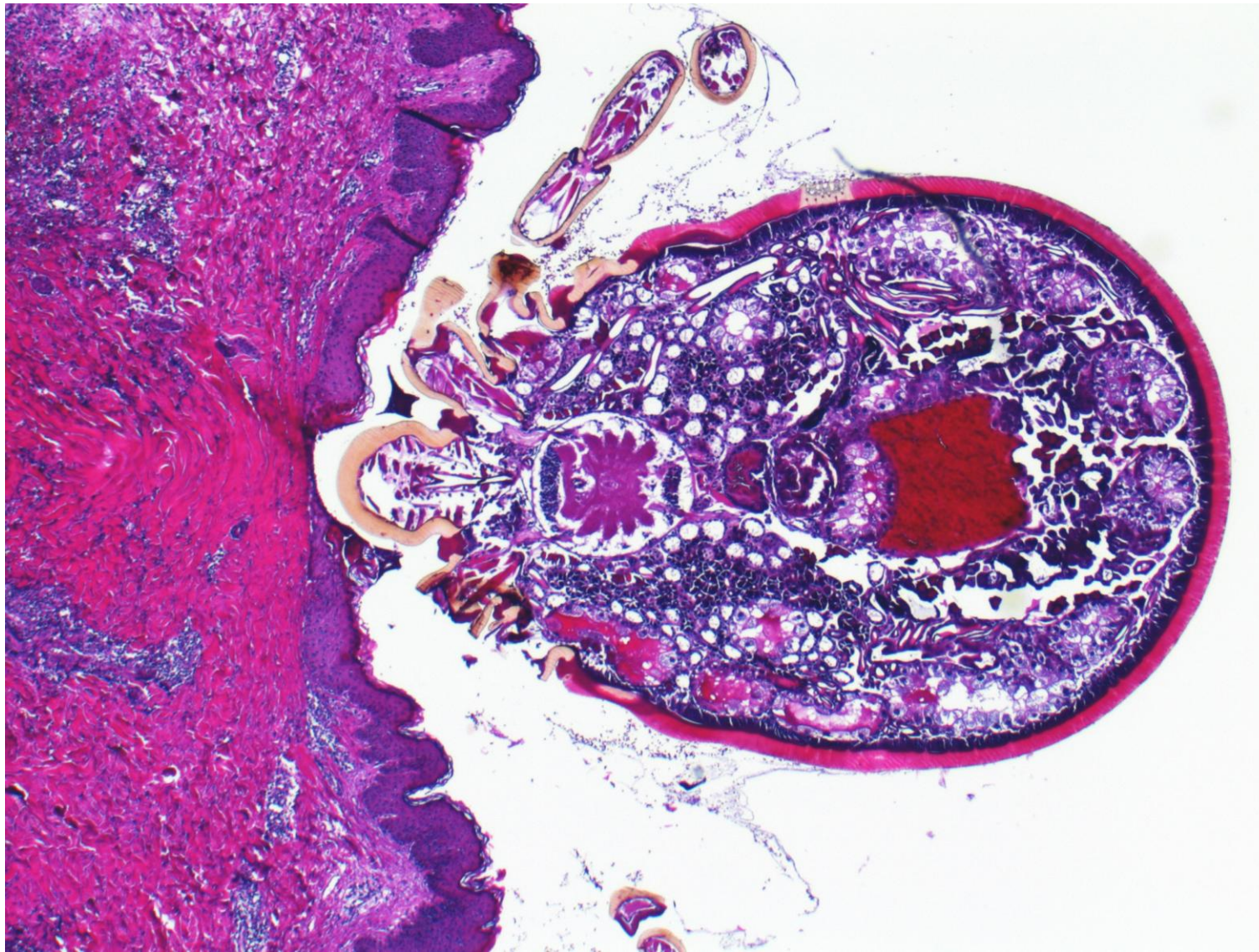
Art of pathology images, pathogens 50

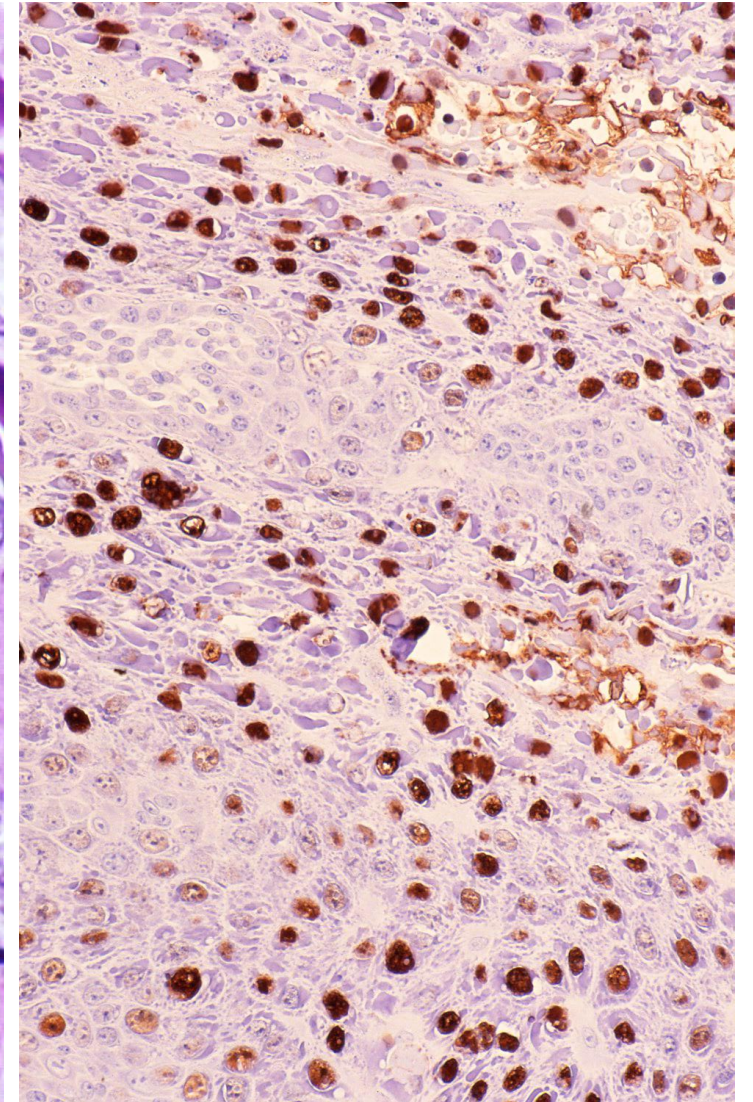
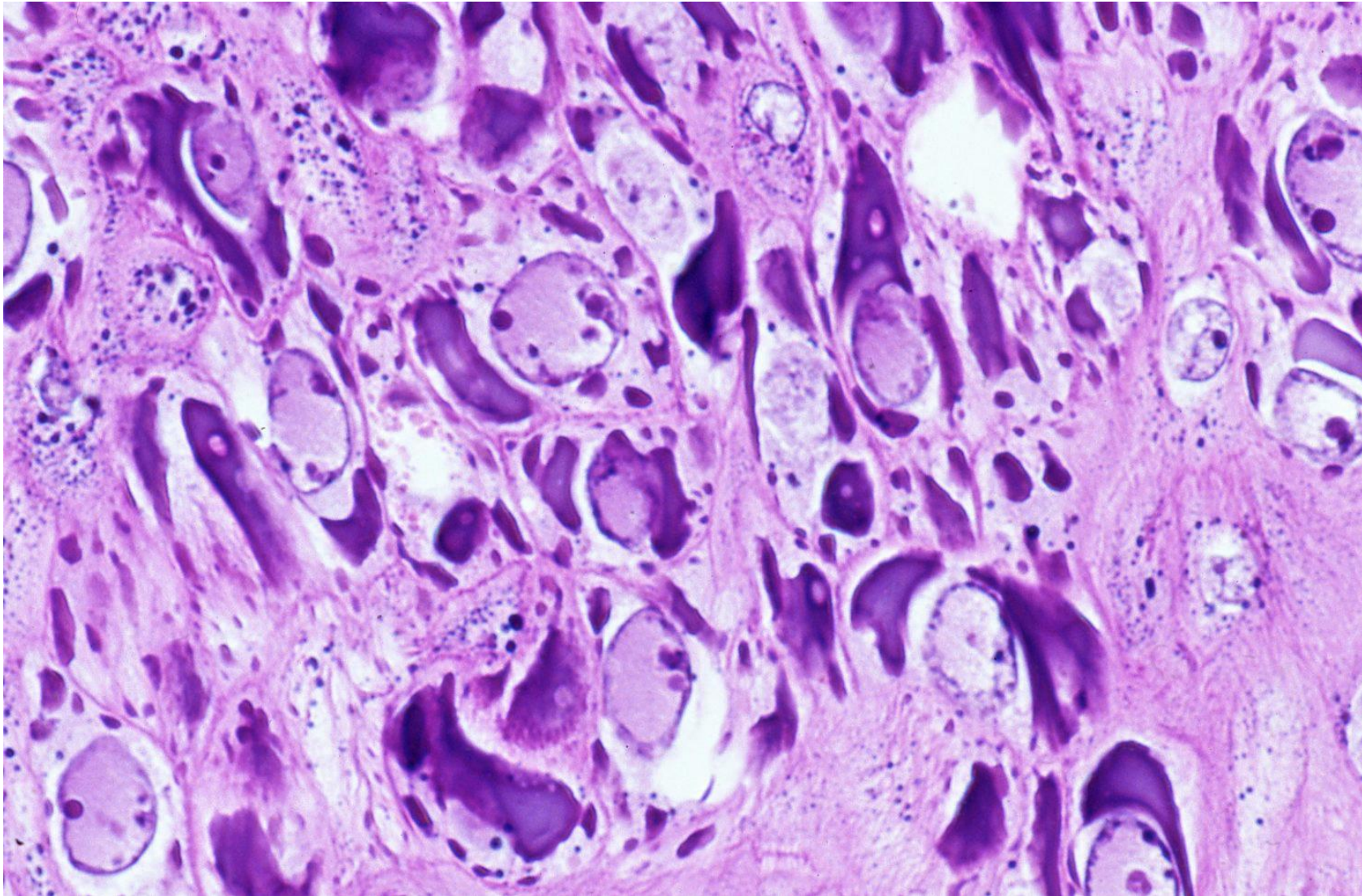
Pathology images of pathogens and infectious diseases are often quite artistic. As a diagnostic pathologist, the author Yutaka Tsutsumi has been fascinated for 48 years by the art of nature. Various staining procedures are used to visualize the pathogens. He is sincerely eager to share the fabulous, fascinating and mystical artistic beauty, brought by the mixture of natural structuring and artificial staining. In 2022, Yutaka Tsutsumi published a Japanese-written atlas entitled “Artistic Pathology Images 50. Presentation of the artistry of pathology images of infectious diseases” from Pathogenarts Publisher, Inazawa, Japan. Here, the English version of the artistic pathology images 50 is presented. Enjoy the pictures.



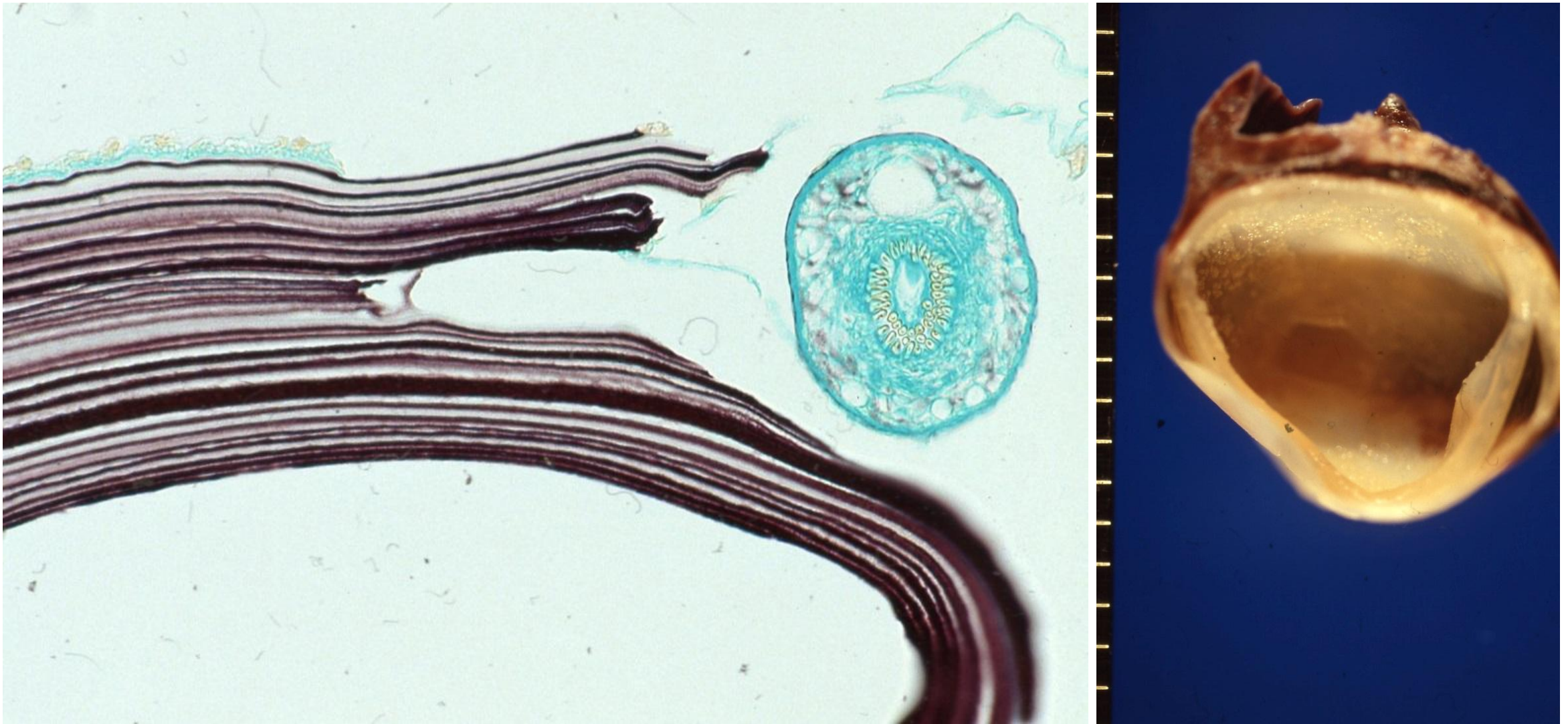No. 0 (front page). *Nocardia asteroides* seen in sputum cytology (Gram). Gram-positive filamentous and lamifying bacteria are clustered in the sputum. The bacteria show acid-fastness (right: sputum cytology, Ziehl-Neelsen).



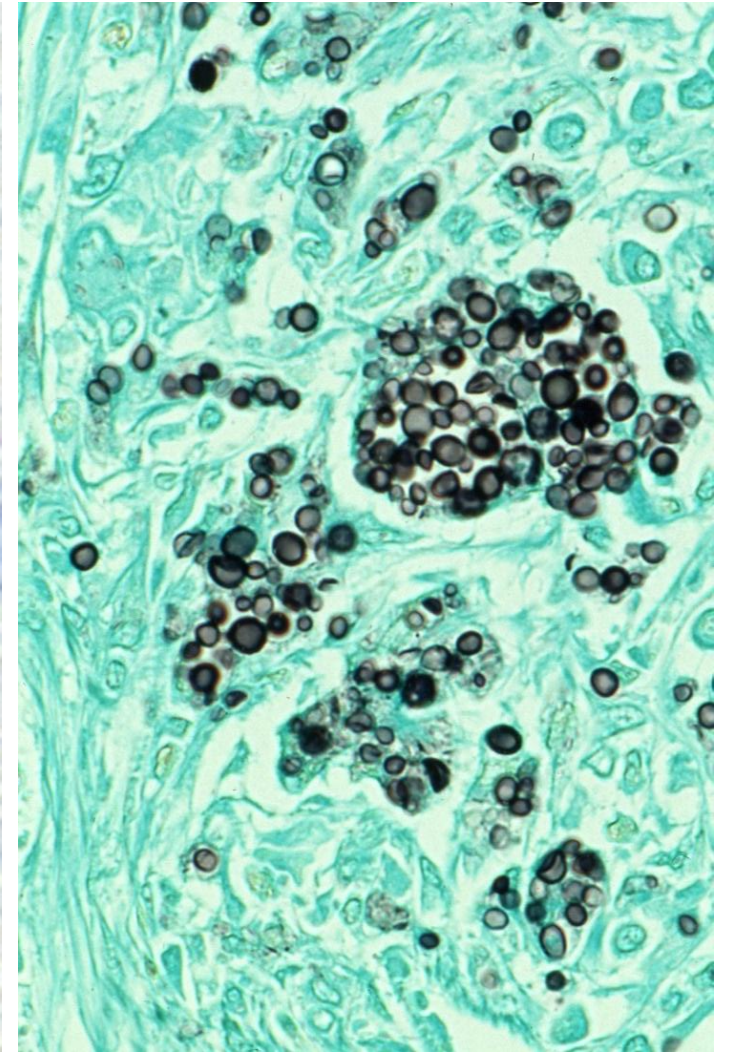
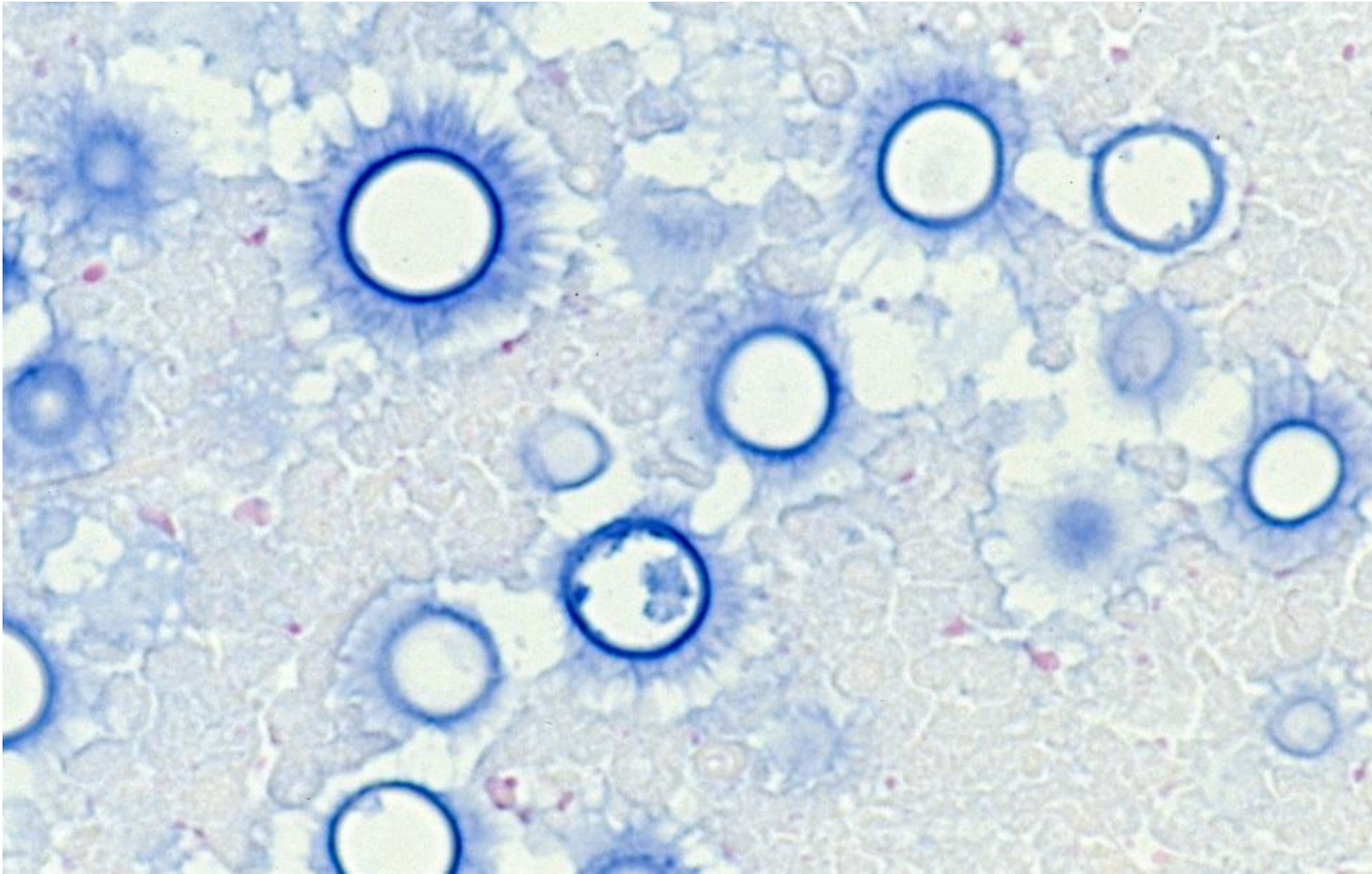
No. 1: Tick bite (H&E). The head portion of an adult tick is stuck into the dermis. Pairs of legs are associated in the anterior part of the body. Note the cut surface of the brain with neurons accumulated in the anterior and posterior poles. Peripheral nerves mainly project to the head of the body (right, H&E).



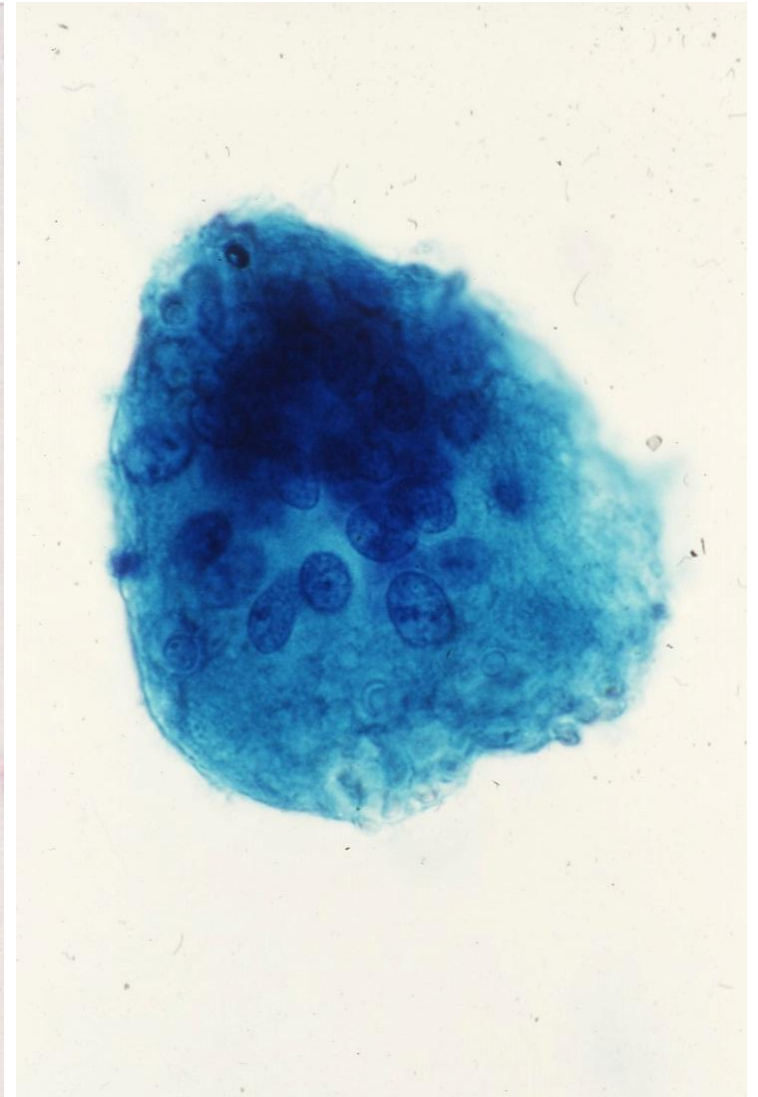
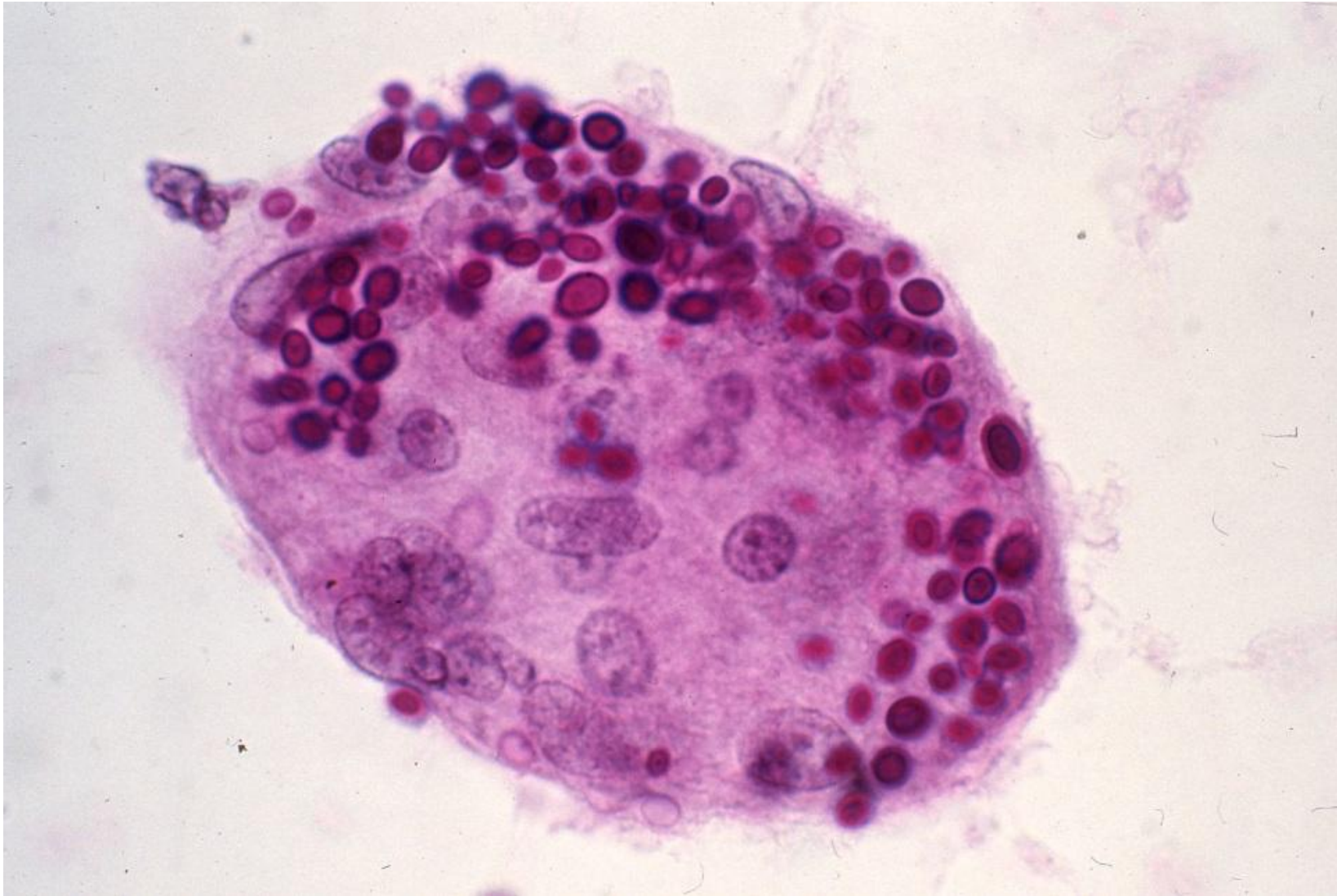No. 2: Myrmecia (a special form of verruca seen on the sole of children) (H&E). Large basophilic cytoplasmic inclusions and intranuclear homogeneous-type viral inclusions are noted. Immunostaining for the capsid antigen of **human papillomavirus** (HPV) demonstrates intranuclear viral infection (brown signals, right).



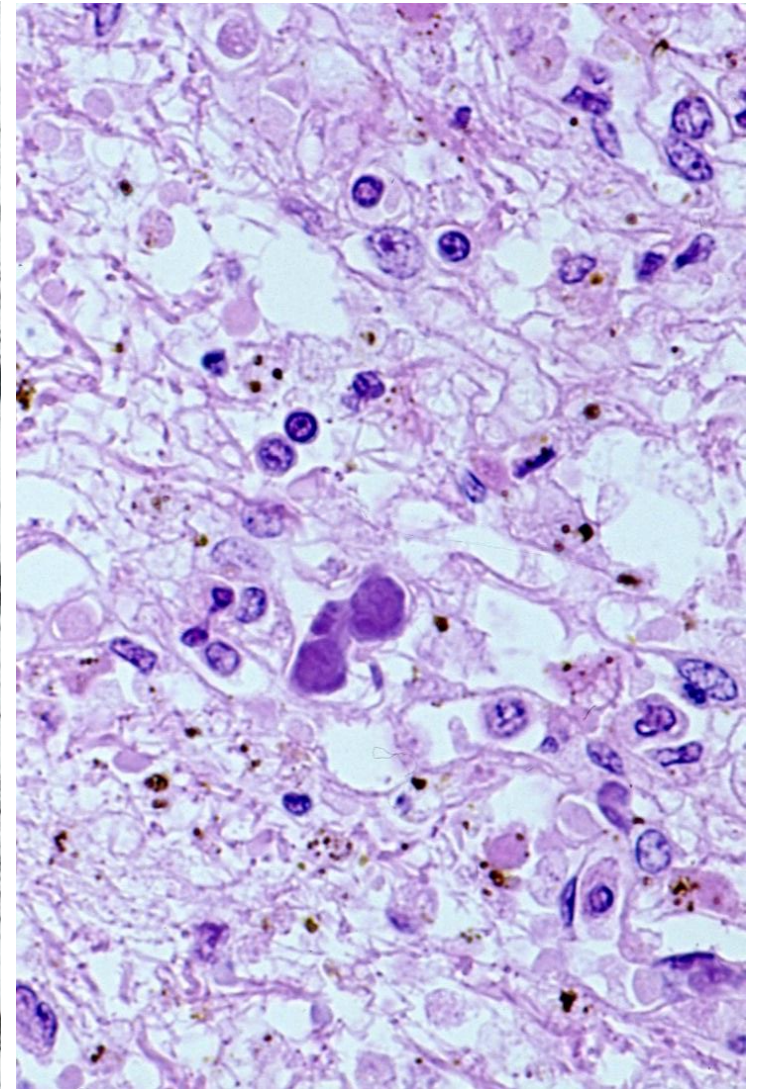
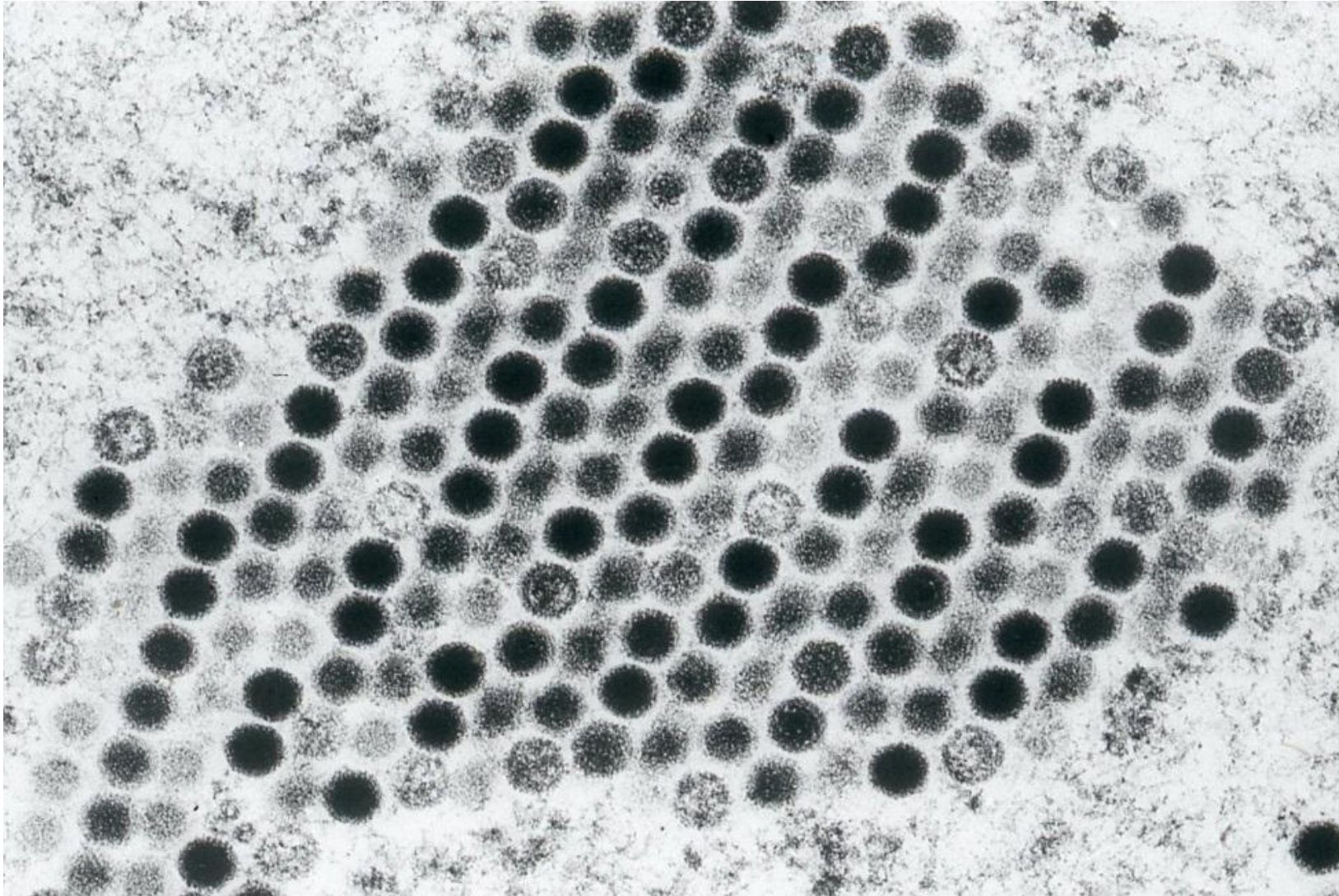
No. 3: Unilocular echinococcosis of the lung (Grocott). A thailand girl case. The wall of hydatid cyst shows beautiful lamellated structures in the Grocott-stained preparation. A protoscolex with birefringent hooks of *Ecchinococcus granulosus* is stained green. The protoscolex grows into a tapeworm in the intestine of the predators (dog and wolf). Grossly, a 5 cm-sized cyst formed in the lung contains 1 mm-sized fine grains corresponding to the protoscolex (right).



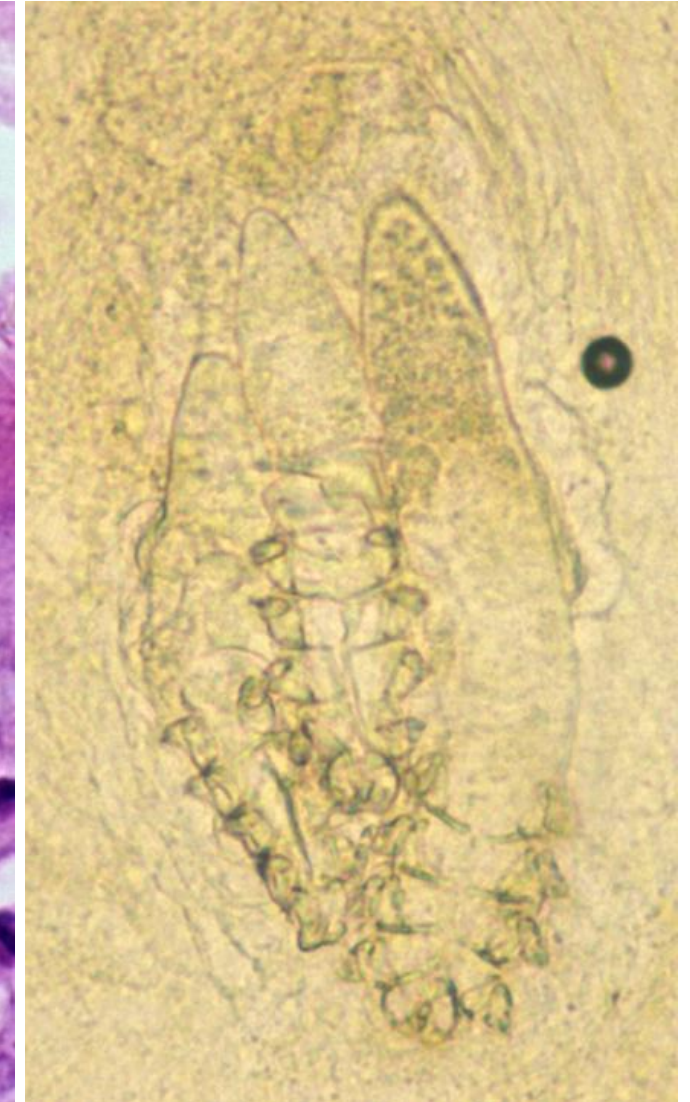
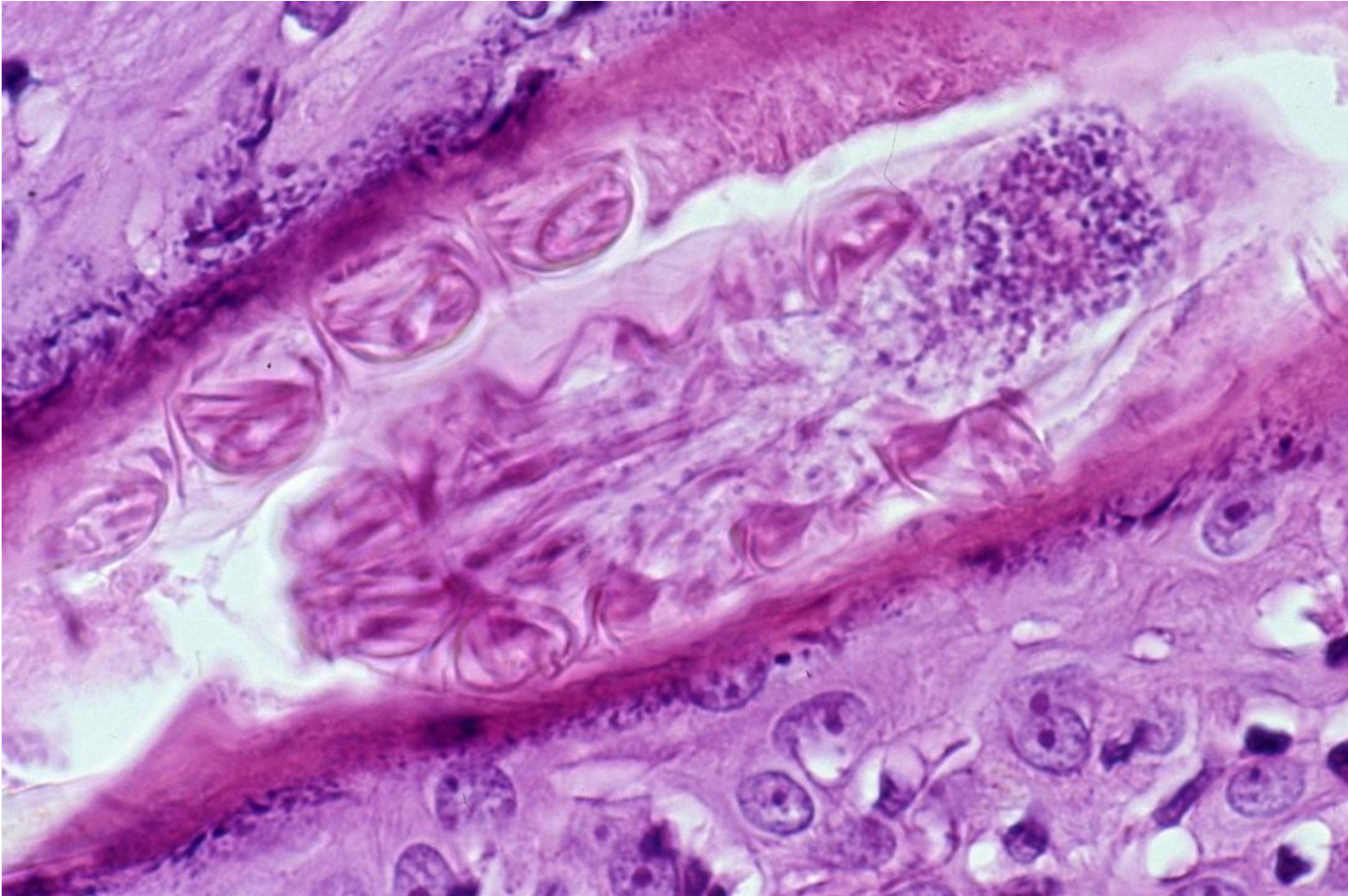
No. 4: Pulmonary cryptococcosis (Alcian blue). *Cryptococcus neoformans* forming alcianophilic thick capsules grow in the lung parenchyma of an immunosuppressed patient. In an immunocompetent individual, cryptococcal granuloma is formed, and the yeast forms of Grocott-positive *C. neoformans* are actively phagocytized by macrophages (right: Grocott).



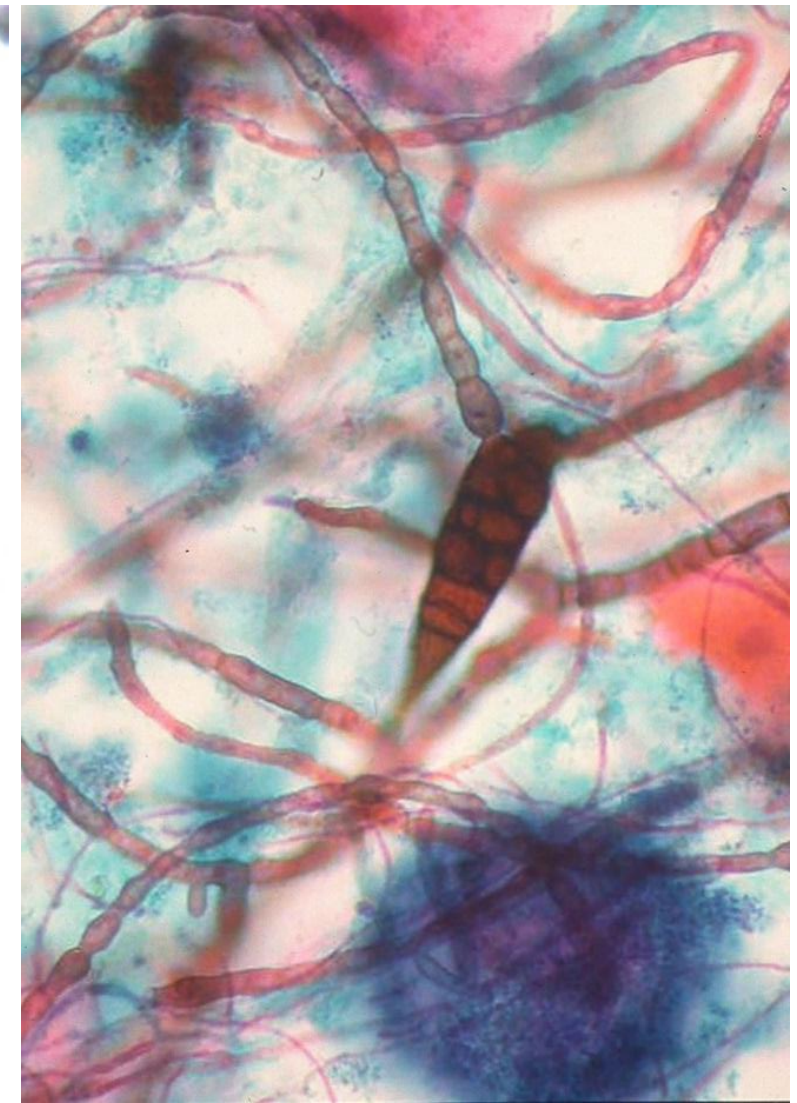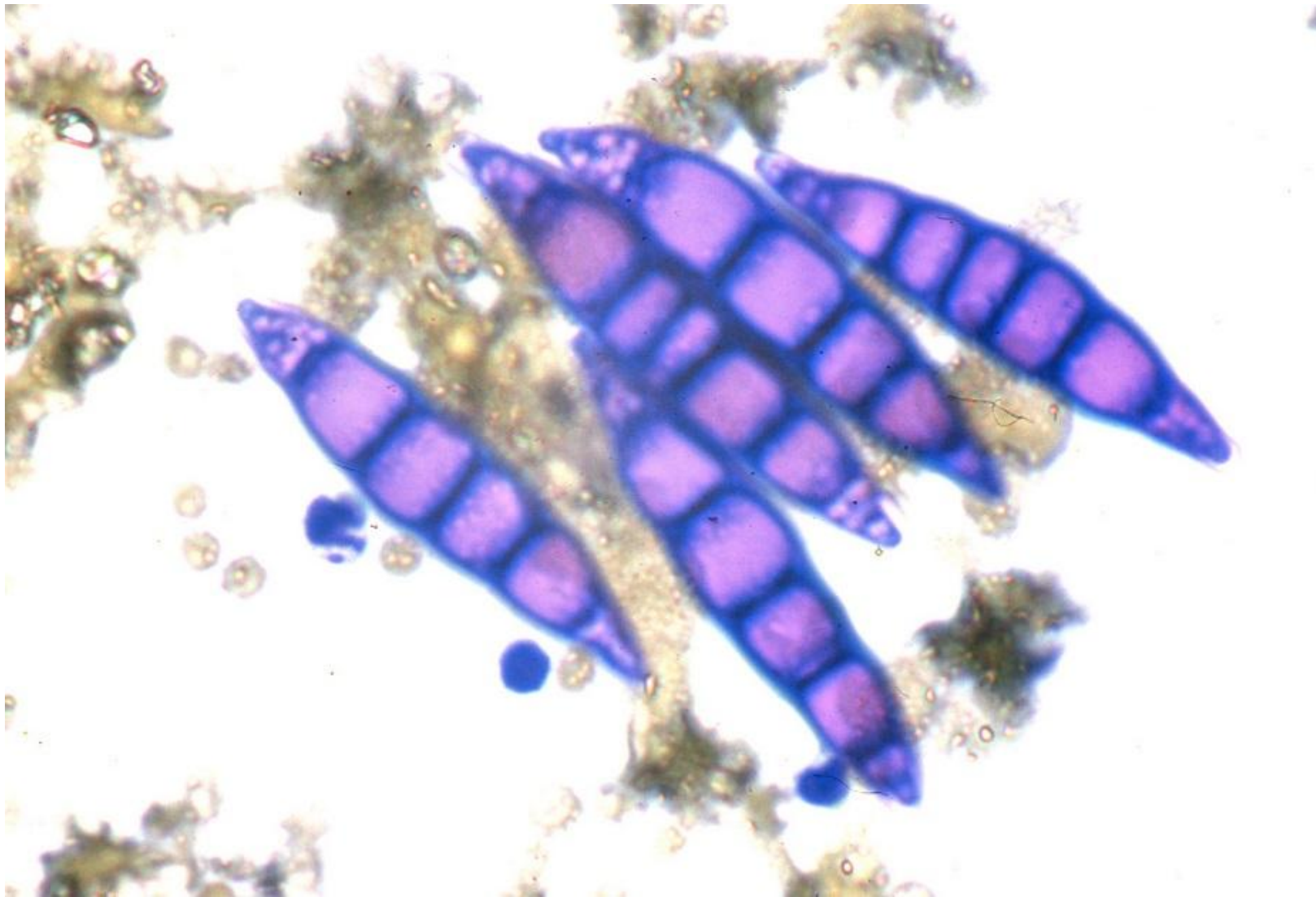
No. 5. Pulmonary cryptococcosis. Sputum cytology (PAS reaction). A multinucleated giant cell phagocytizes PAS-reactive yeasts of *Cryptococcus neoformans*. In the Papanicolaou-stained cytology specimen, the yeasts are transparent (sputum cytology, Papanicolaou).



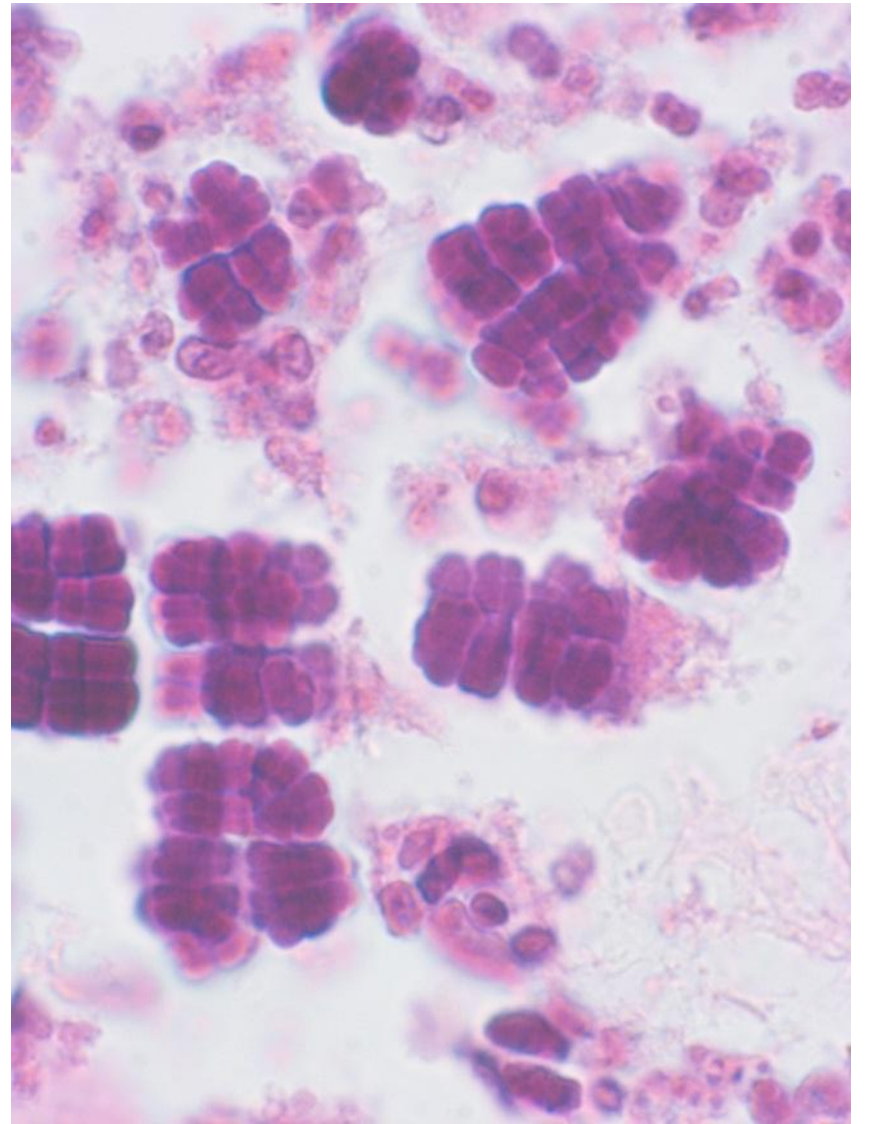
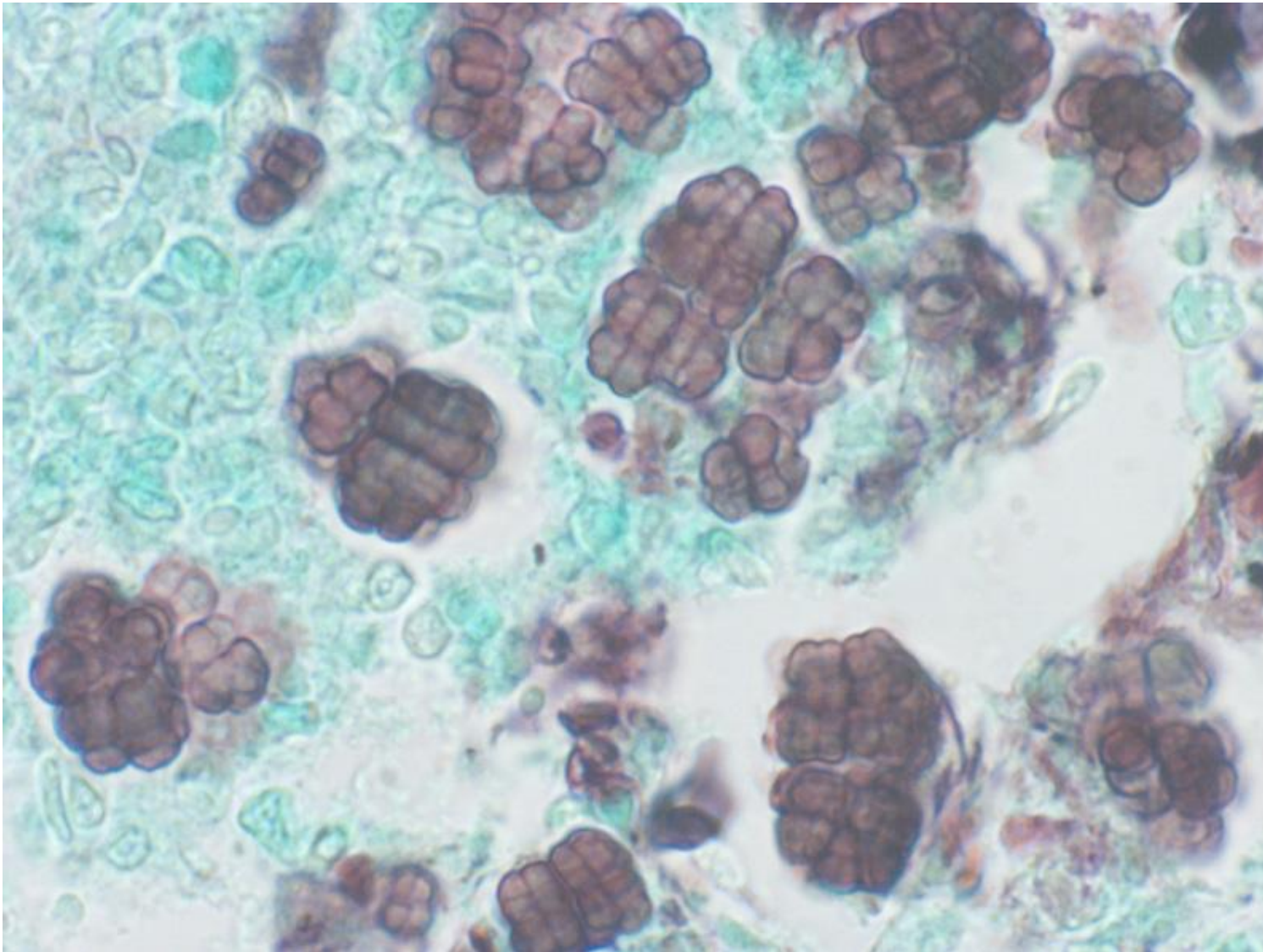
No. 6. Adenovirus pneumonia (electron microscopy). Adenoviral particles with a hexagonal shape are geometrically arranged in the nucleus. Light microscopically, epithelial cells with basophilic intranuclear inclusions are focally seen in the background of hemorrhagic necrosis (right: H&E).



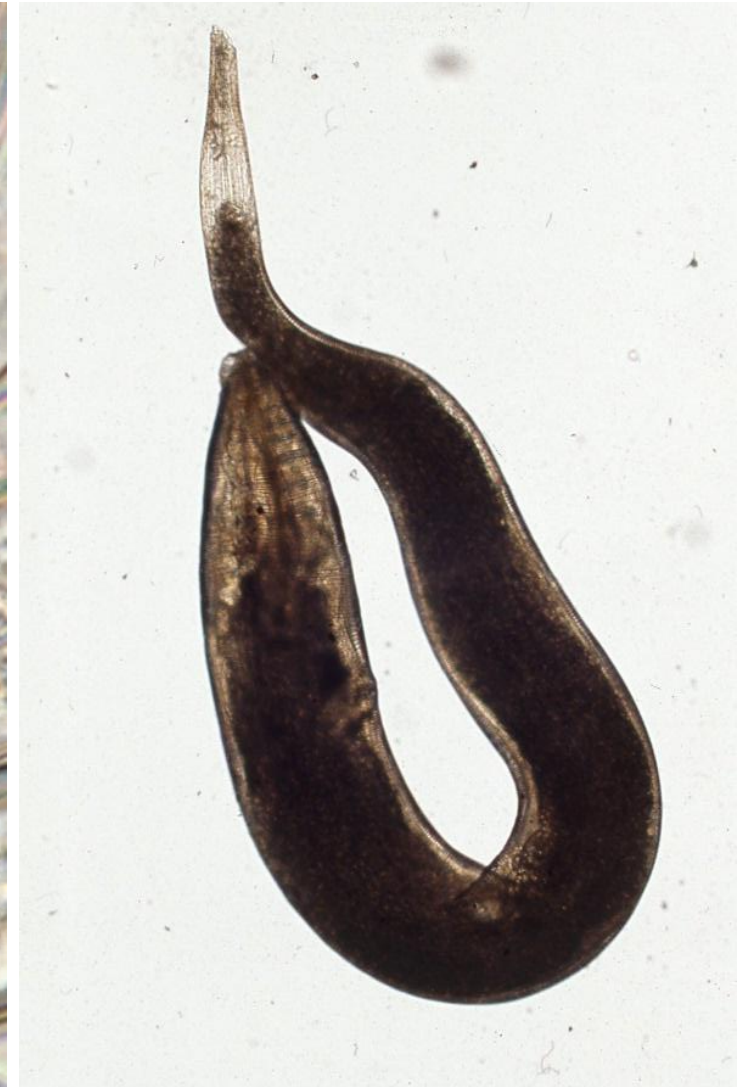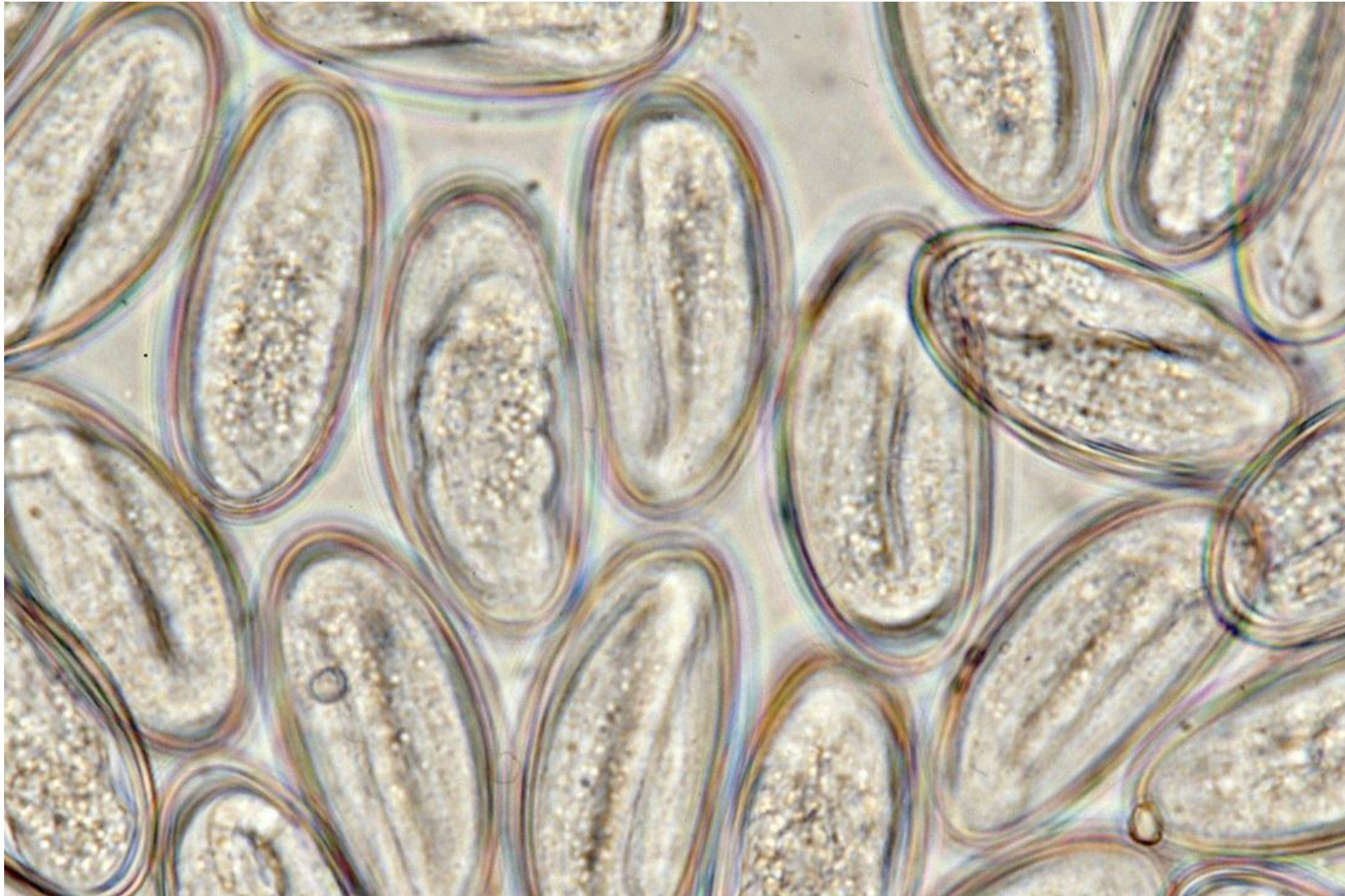
No. 7 : *Demodex folliculorum* (H&E). *D. folliculorum* is a normal resident of hair follicles on the sebaceous skin, particularly on the face. Four pairs of legs are observed. Right: Two adult mites are seen in the sebum squeezed from the facial hair follicle (unstained smear). Every healthy human adult has the mite in the lumen of the hair follicle on the face.



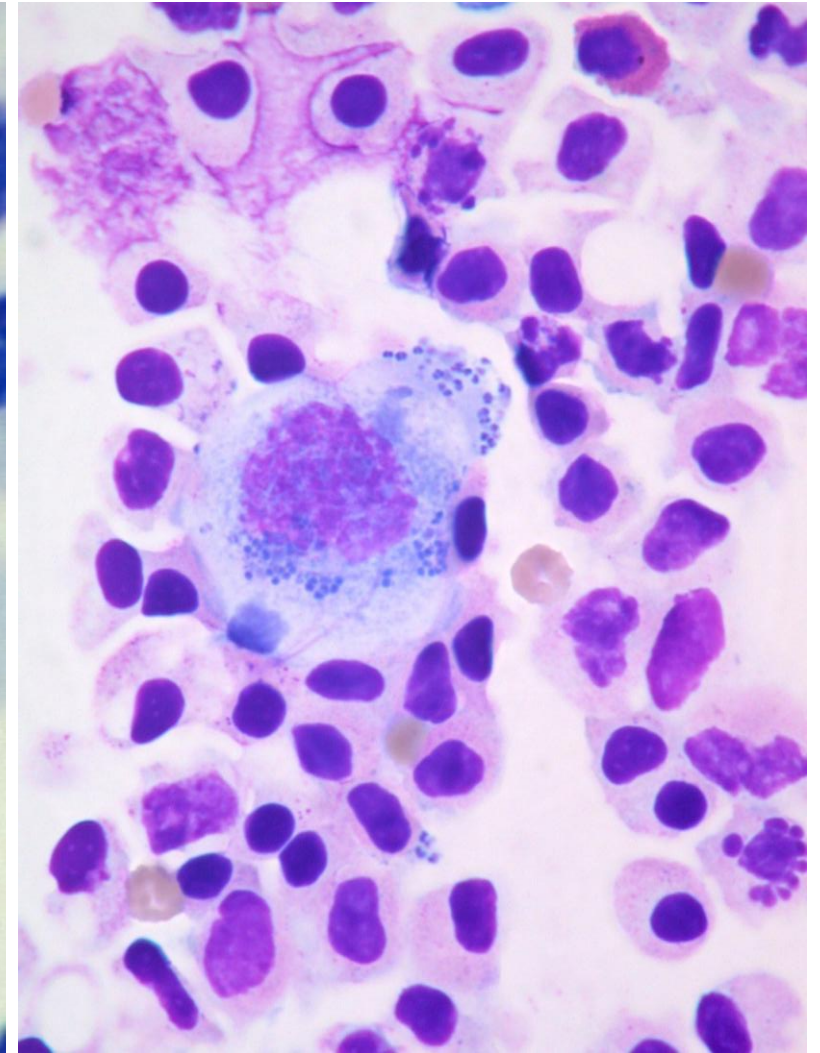
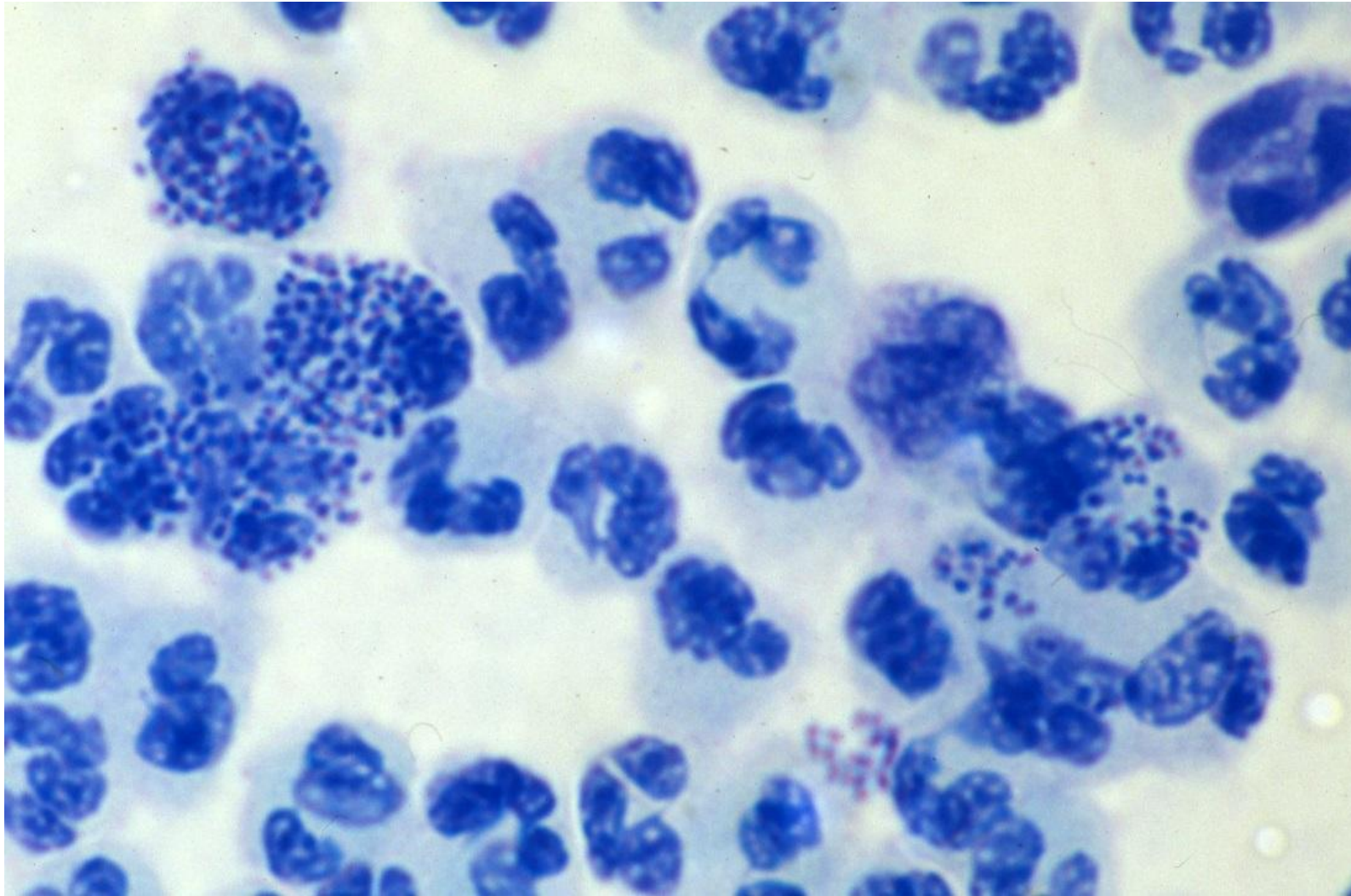
No. 8: *Alterinaria alternata* incidentally seen on the cervical smear preparation (May-Giemsa). *A. alternata*, a plant pathogen, represents an air-floating black fungus, and the conidial heads can be contaminated on the pathology specimens. Right: In the sputum, the brown-colored (pigmented) conidial head happens to show hypha formation, but the growth is non-pathogenic for the human (Papanicolaou).



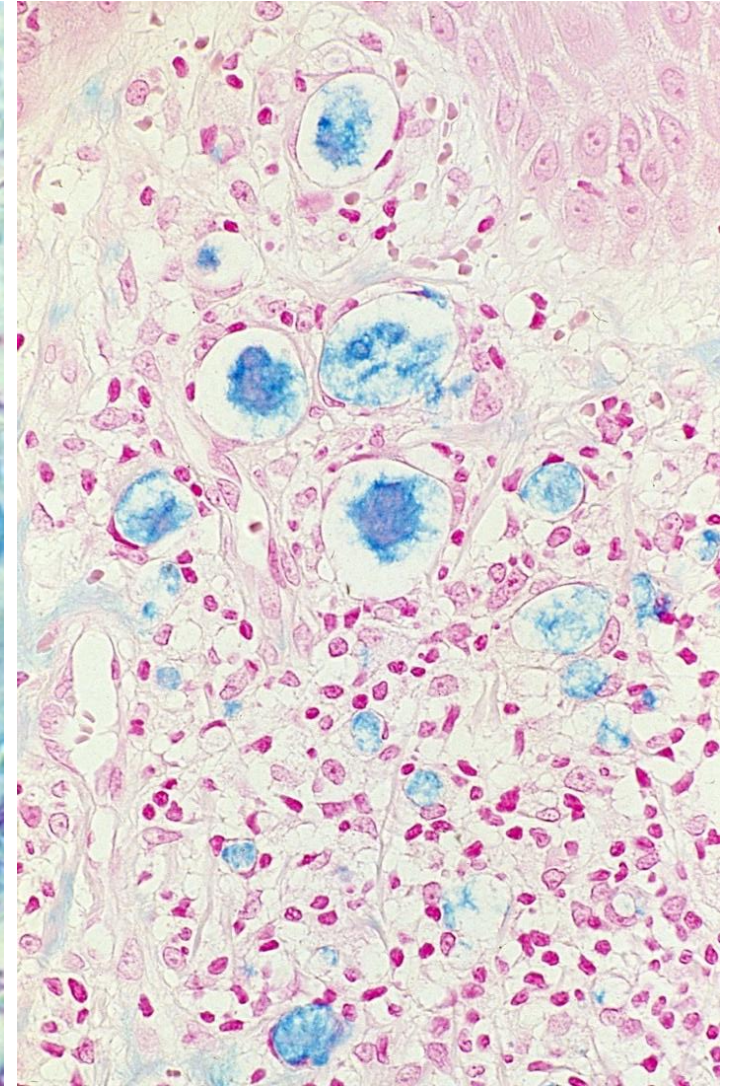
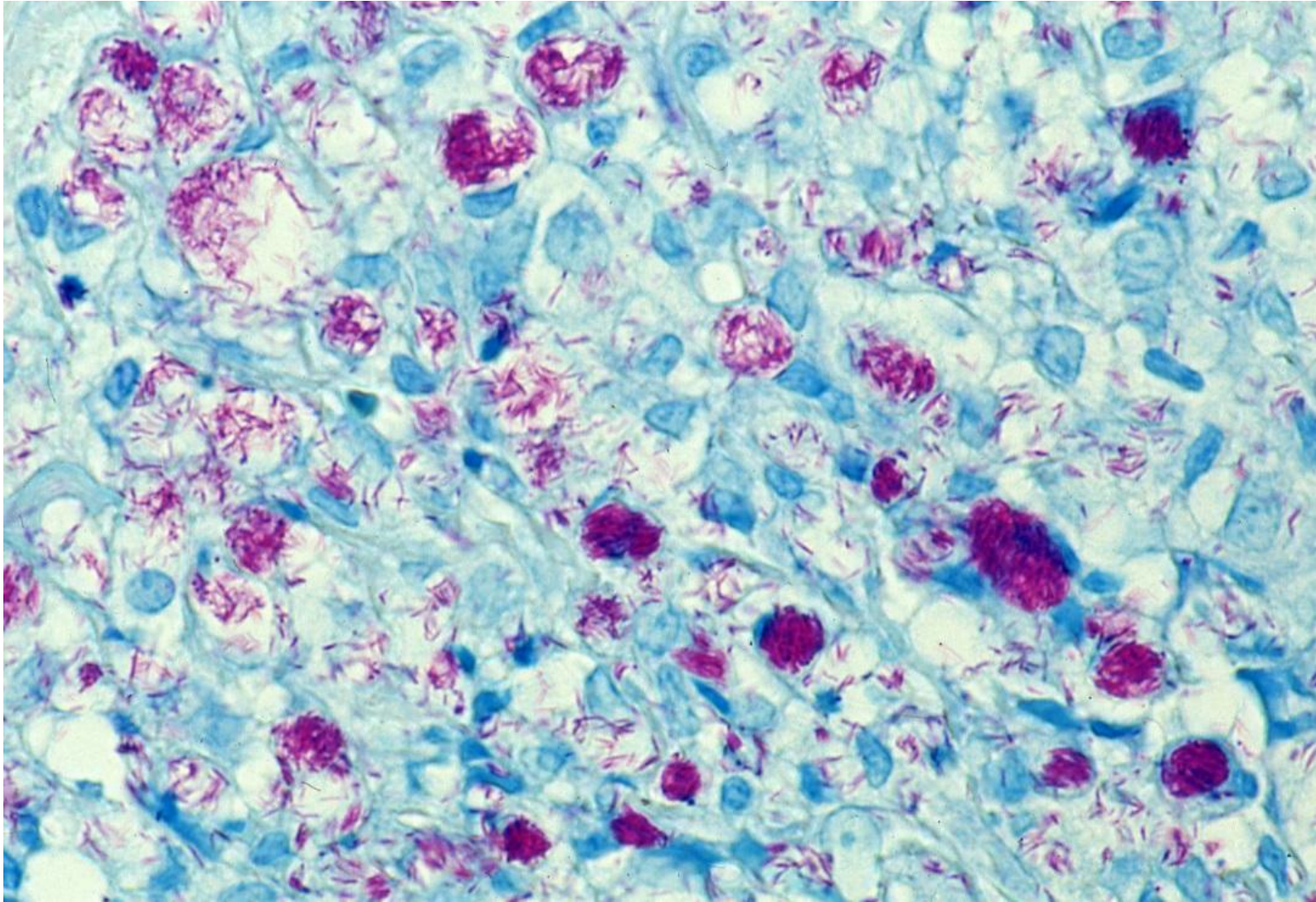
No. 9: *Sarcina* seen in the gastric ulcer base (Grocott). *Sarcina* organisms, Gram-positive cocci, occur in tetrads or packets of 8 or more, and have been isolated from the feces of healthy vegetarians. *Sarcina* has been found in patients with a history of gastric outlet obstruction or delayed gastric emptying. *Sarcina* may be non-pathogenic, and should be distinguished from yeast fungi because of the reactivity with PAS and Grocott stains. H&E appearance is shown in the right panel.



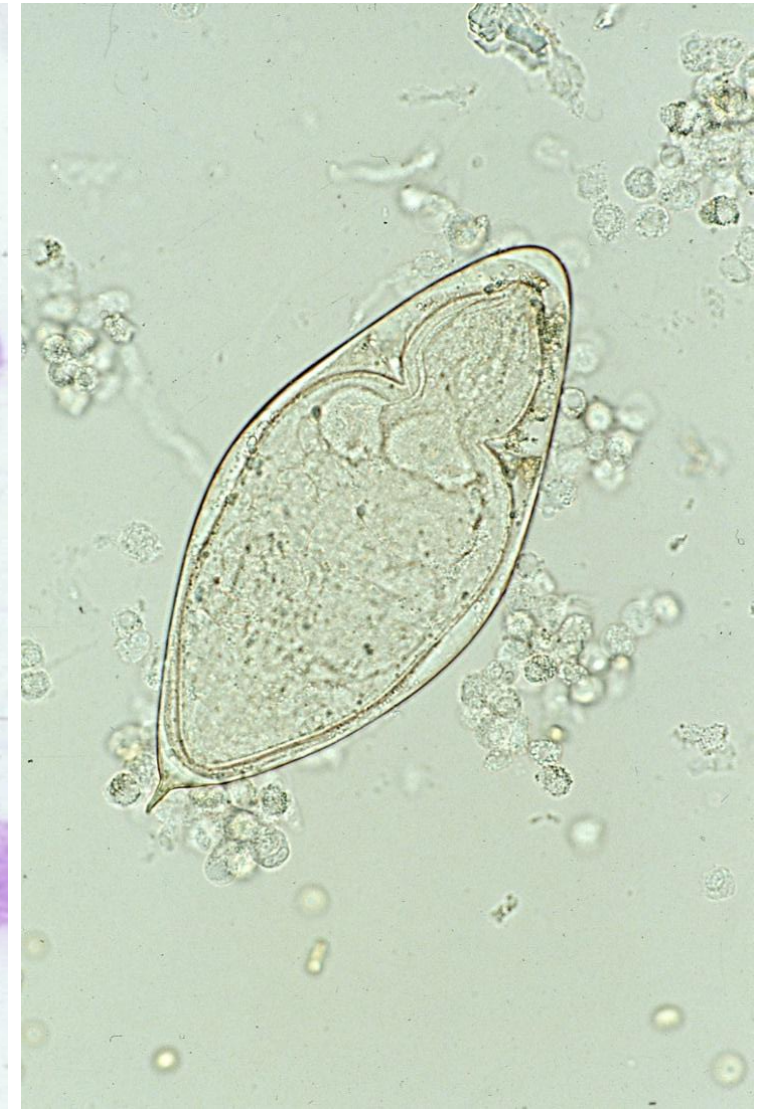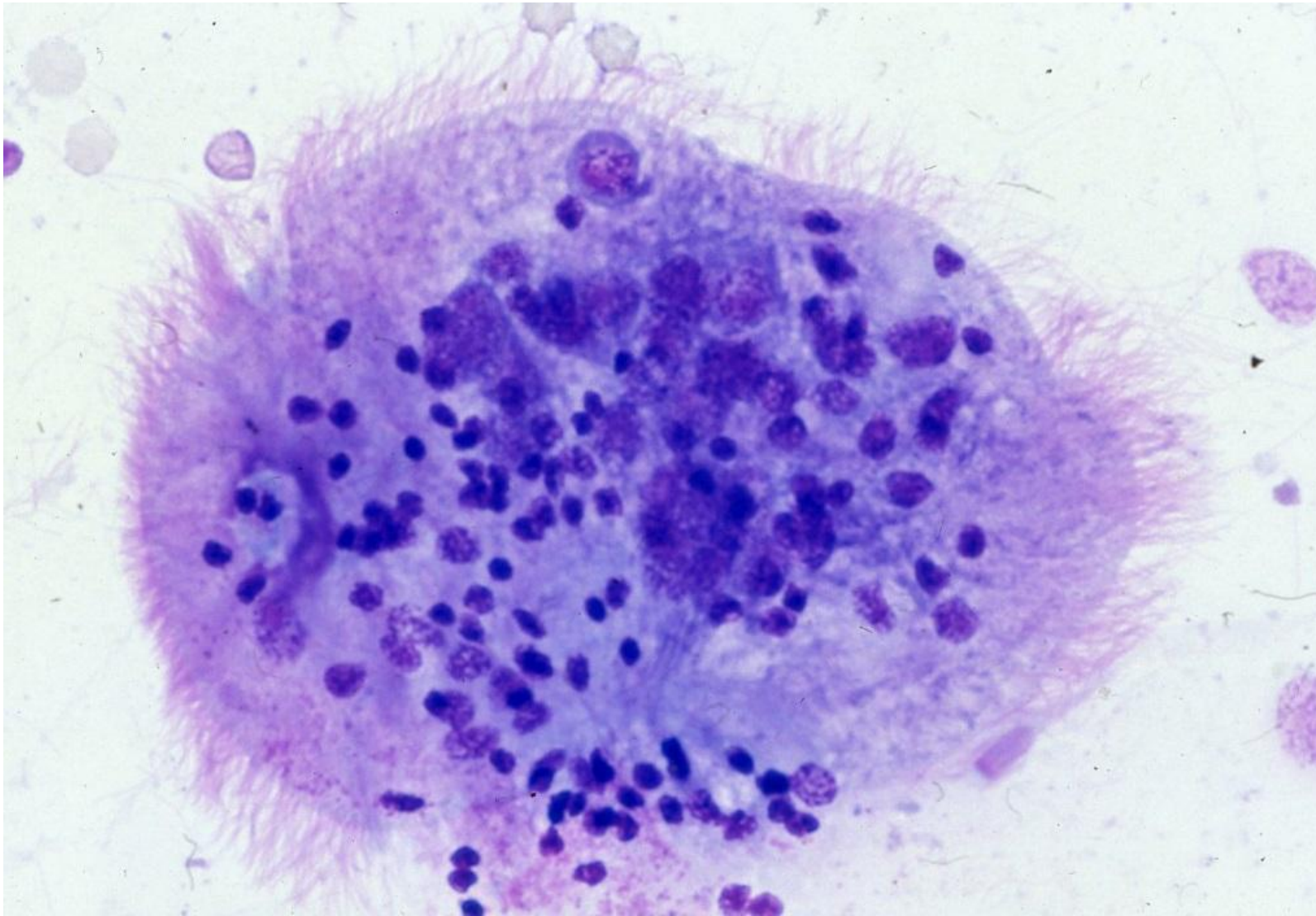
No. 10: Eggs of *Enterobius vermicularis* (unstained preparation). A female adult worm was found on the vulva of 4 y-o girl (right panel). During stereo microscopic observation, the eggs were artificially hatched due to the pressure caused by the cover slip. The ova are asymmetrical in shape. The larvae were moving within the eggs, even 4 days after formalin fixation!



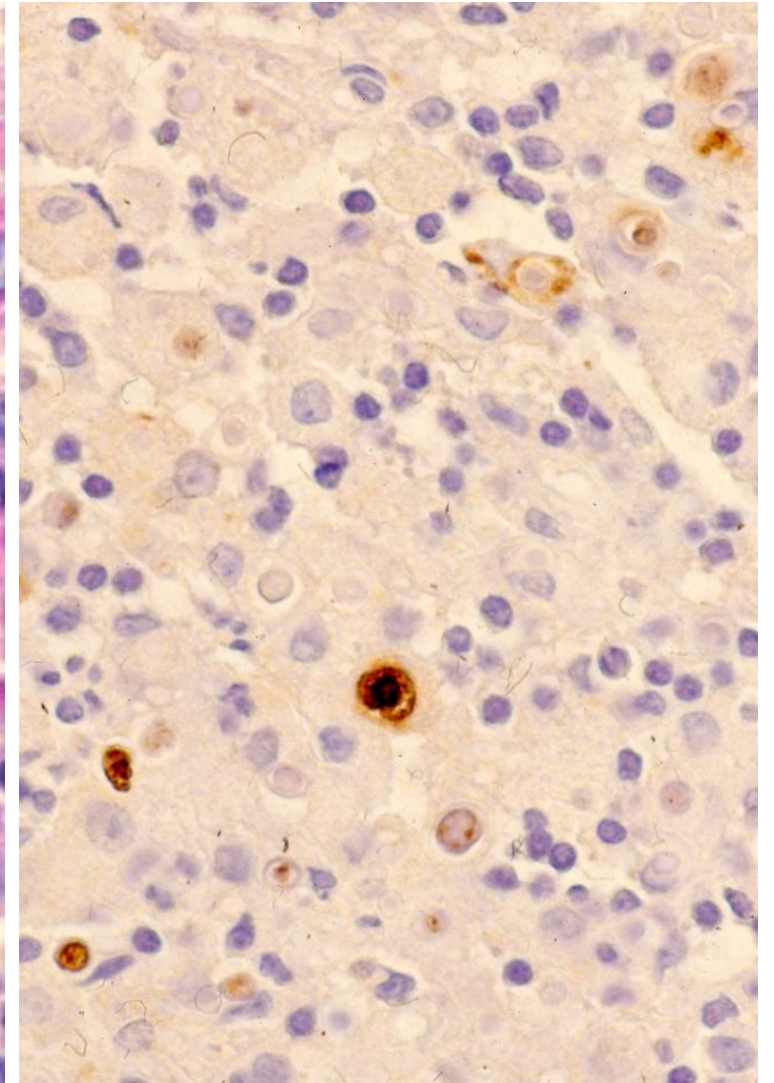
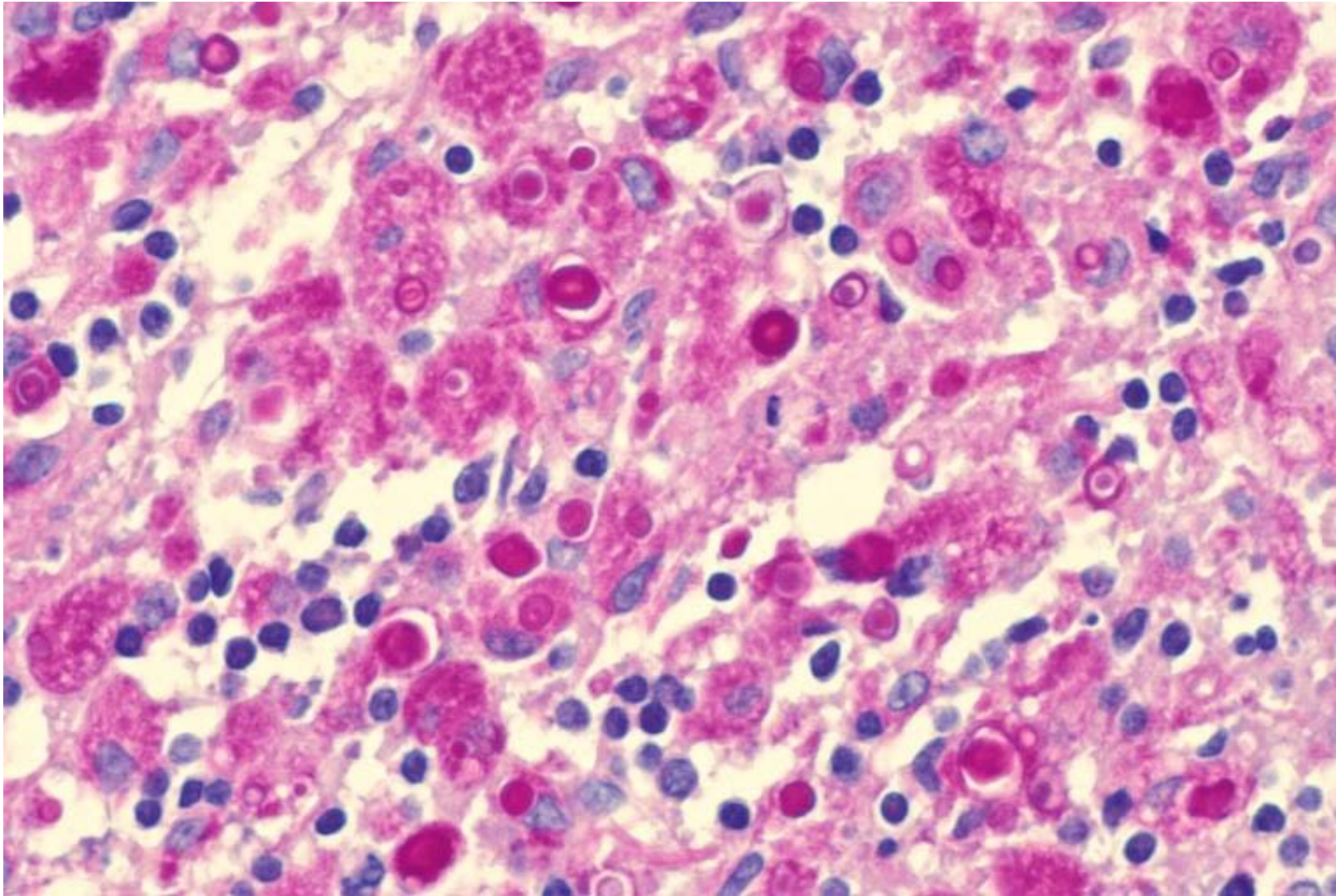
No. 11: *Neisseria gonorrhoeae* in urethral discharge (methylene blue). Diplococci are phagocytized by neutrophils, confirming the diagnosis of gonorrhoea, a representative sexually transmitted infection. In the urine cytology (right: Giemsa stain), the cocci are clustered around the squamous cell of urethral origin, explaining the affinity of gonococci to the urethral mucosa.



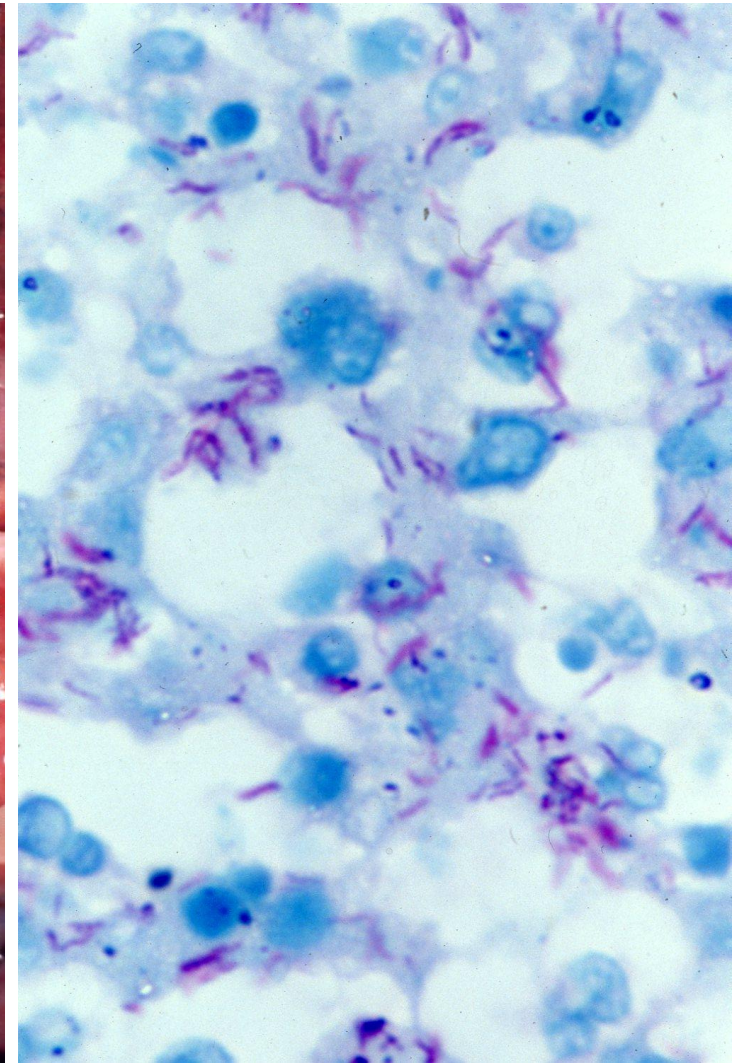
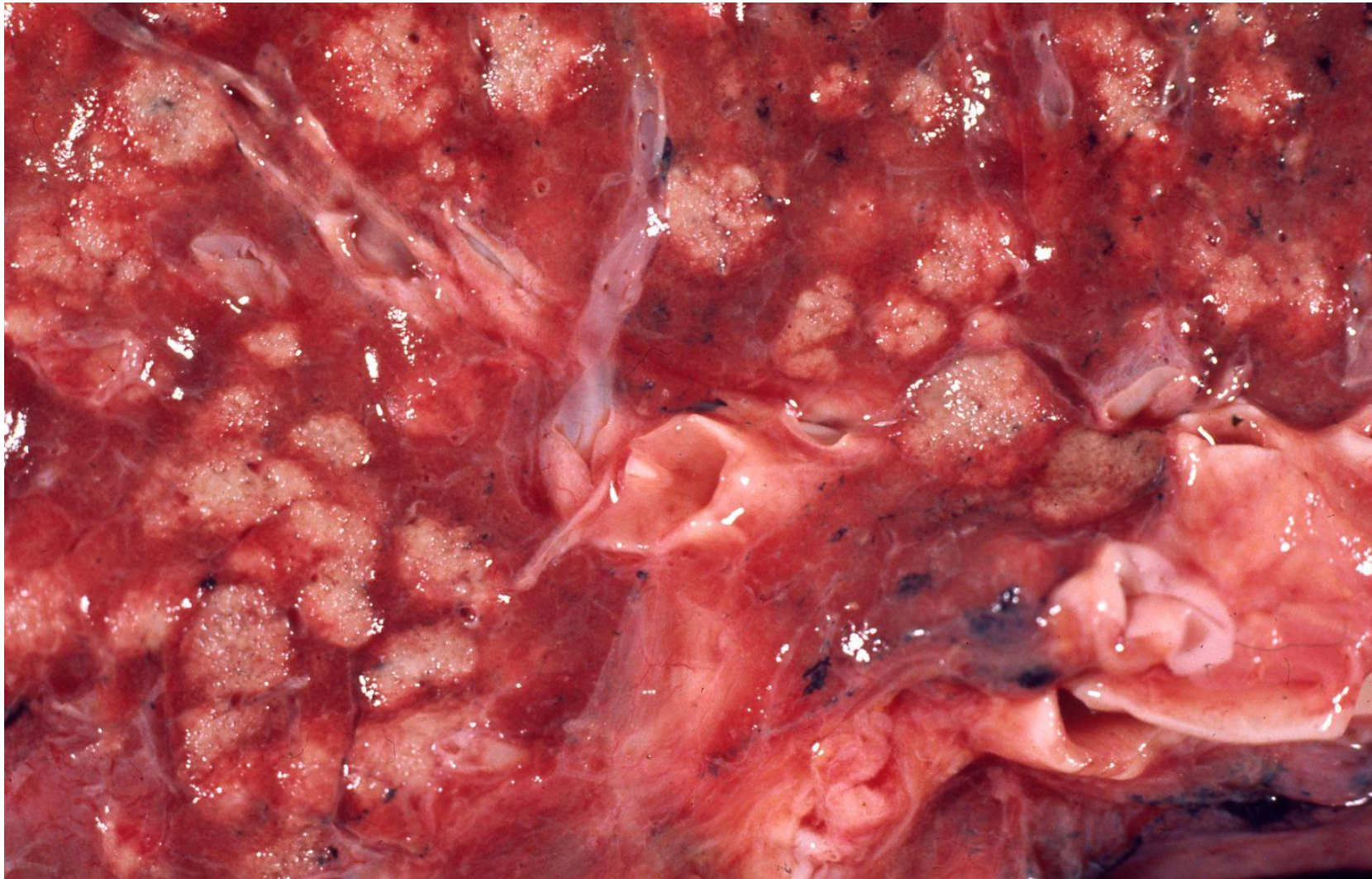
No. 12: Lepromatous leprosy (Ziehl-Neelsen, Fite method). Skin biopsy shows numbers of acid-fast bacilli growing in the cytoplasm of macrophages (lepromatous cells). The round-shaped clusters of *Mycobacterium leprae* in the lepromatous cells are called globi. Right: the globi are stained blue with colloidal iron stain, indicating accumulation of hyaluronic acid in the foamy cells.



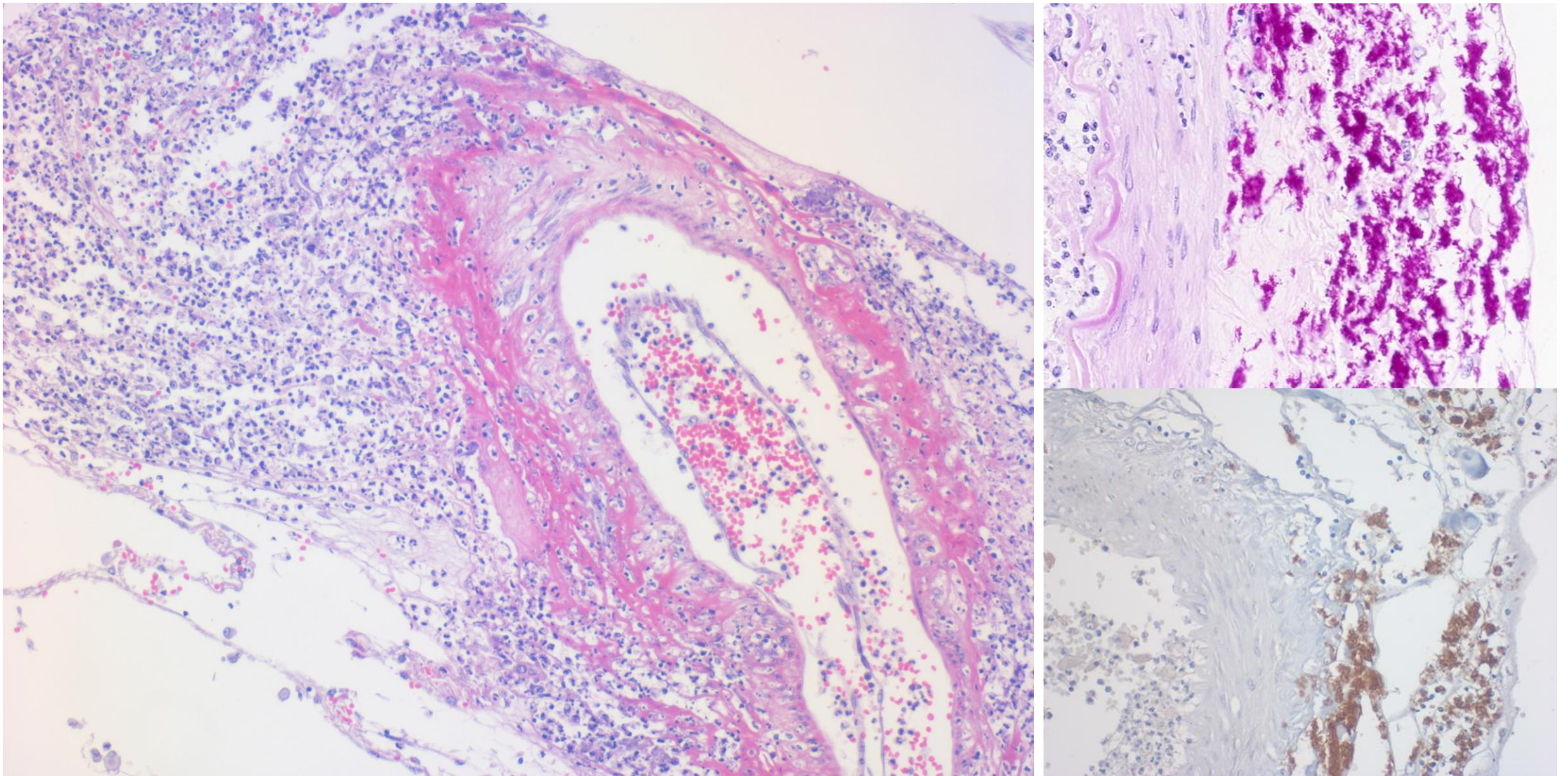
No. 13: A **miracidium** hatched from the ovum of *Schistosoma haematobium* in the urine (May-Giemsa). Infection occurred in Kenya. The miracidium contains numbers of nuclei and is lined by flagellae. The miracidium infects the snail in the water to produce cercariae. A spined ovum containing the miracidium in hematuria is demonstrated in the right panel (unstained preparation).



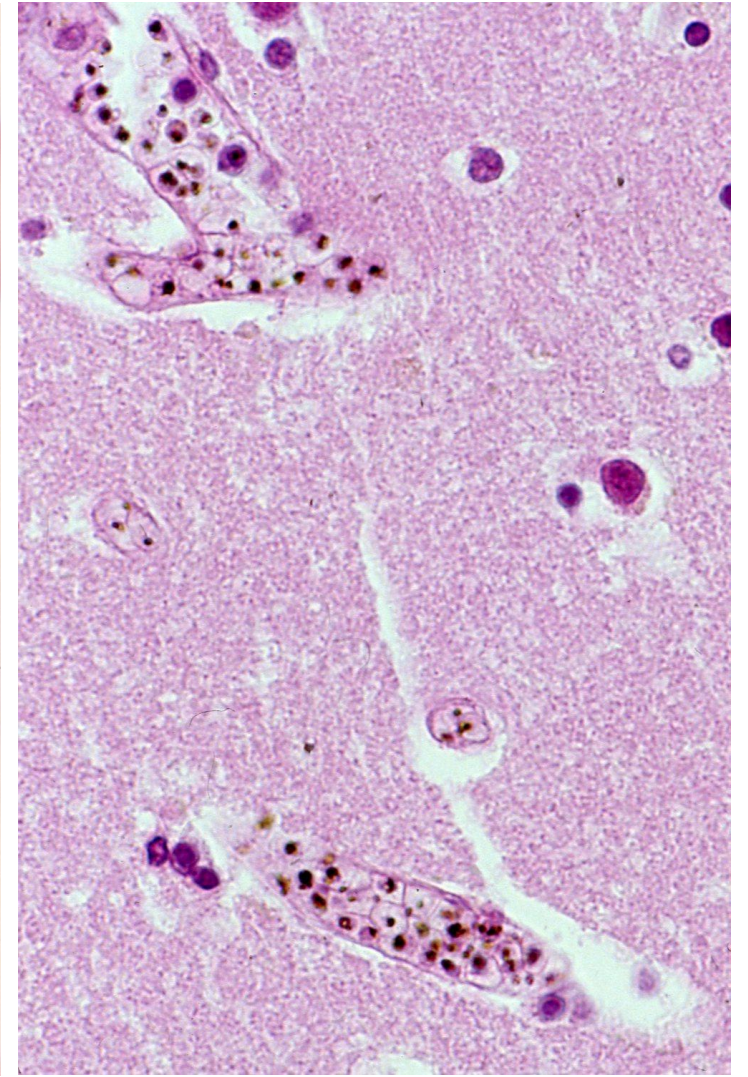
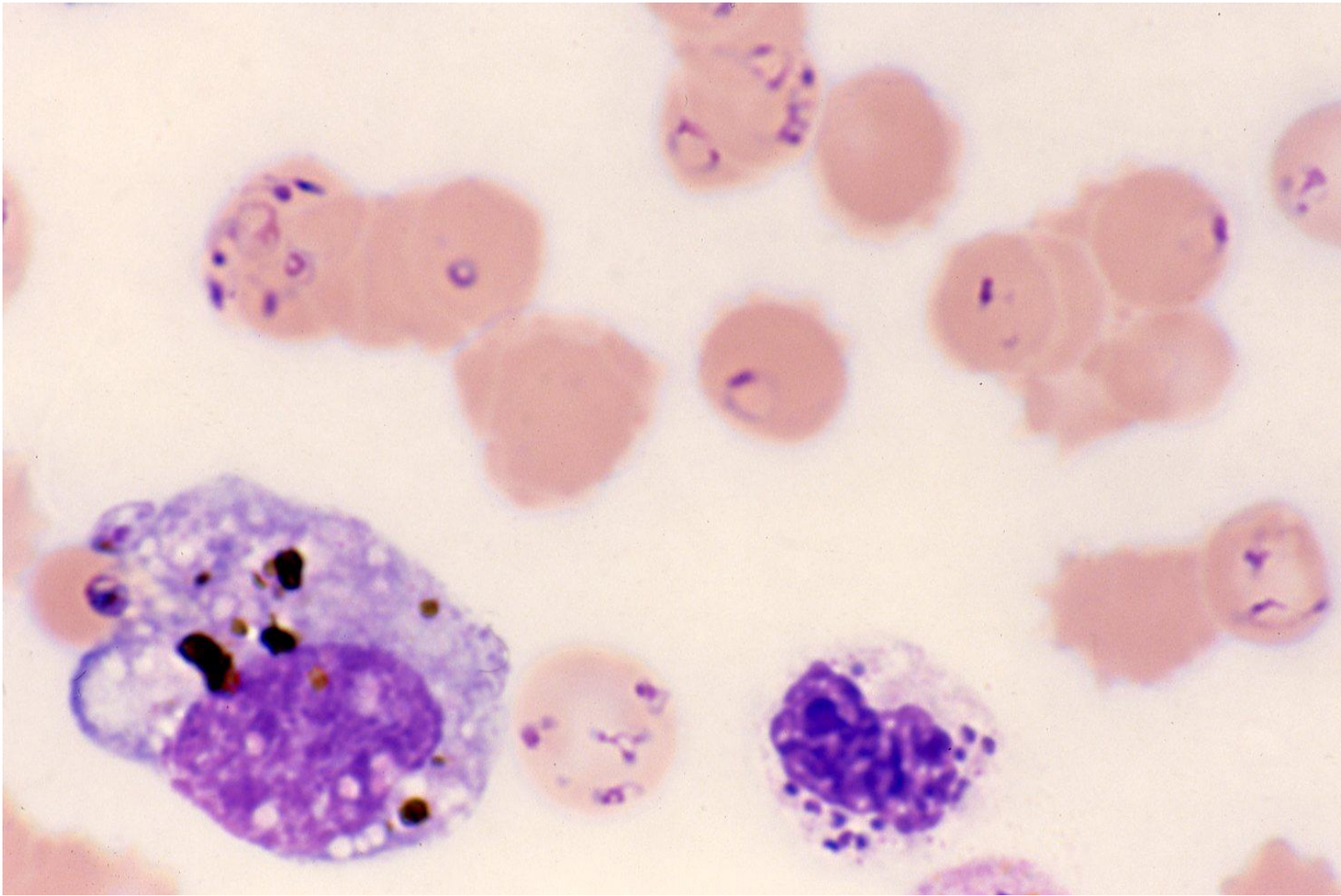
No. 14: malacoplakia (PAS reaction). Rectal biopsy shows a xanthogranulomatous lesion with **Michalis-Gutmann bodies**. The M-G bodies represent magenta-stained globules in the cytoplasm of macrophages. *E. coli* antigens are demonstrated in the M-G bodies (right: immunostaining for *E. coli* antigens). Malacoplakia is a special form of *E. coli* infection, mainly seen in the large intestine and urinary bladder.



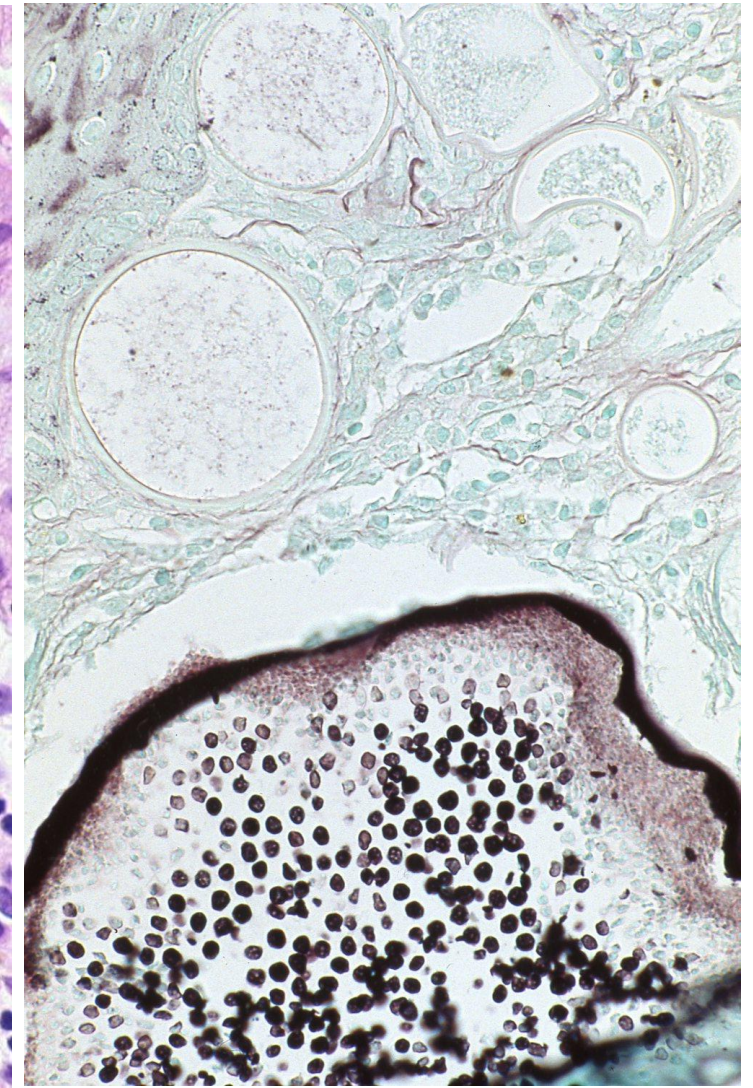
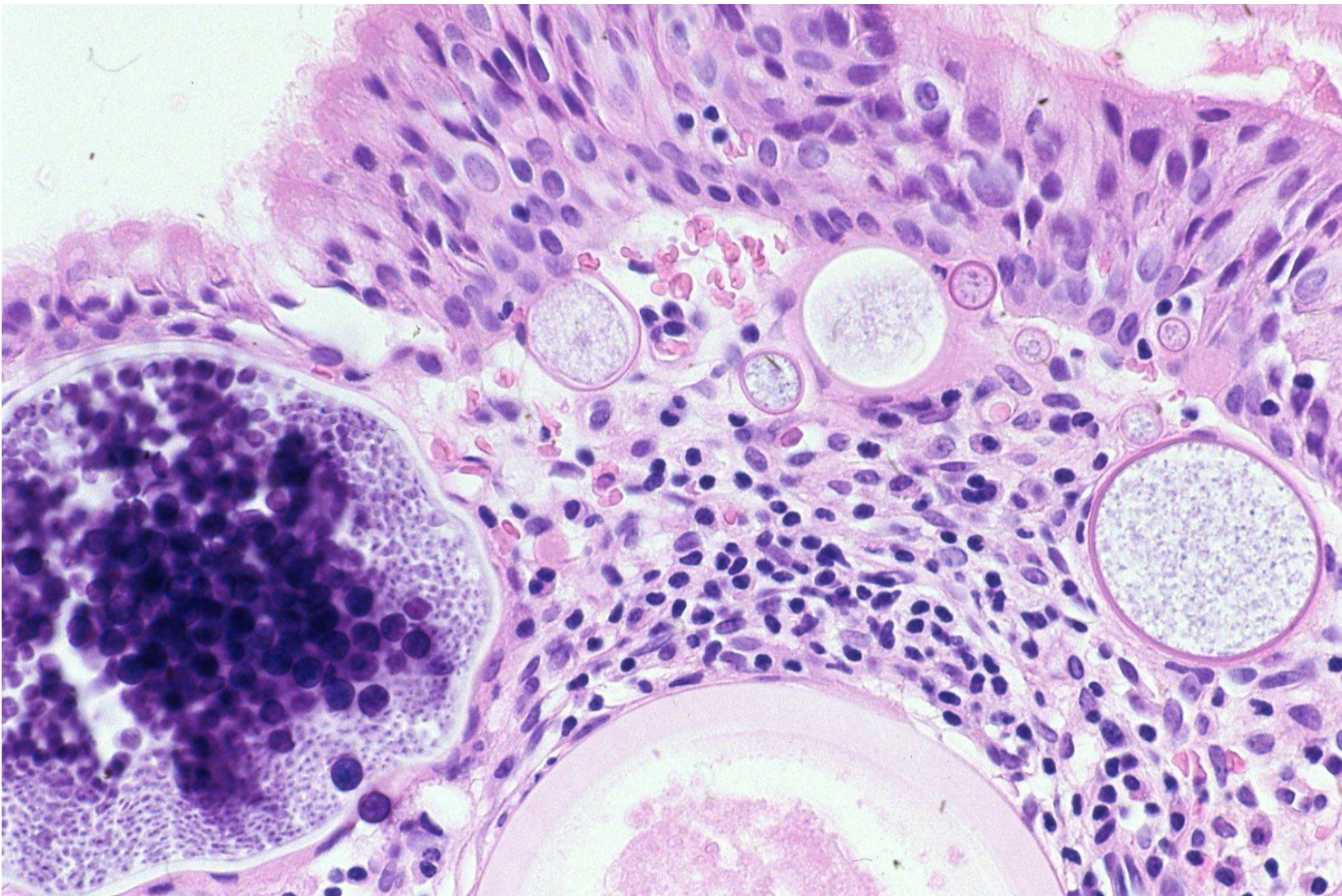
No. 15: Gross appearance of **exudative tuberculosis** seen after chemotherapy with steroid hormones against acute myeloid leukemia. Opportunistic infection of *Mycobacterium tuberculosis* is highly biohazardous. Microscopically, numbers of acid-fast bacilli are seen in the cytoplasm of macrophages (right: Ziehl-Neelsen). It should be noted that the photographing the cut surface of the lung gives a serious risk of airborne transmission of *M. tuberculosis* for the autopsy executor and assistants.



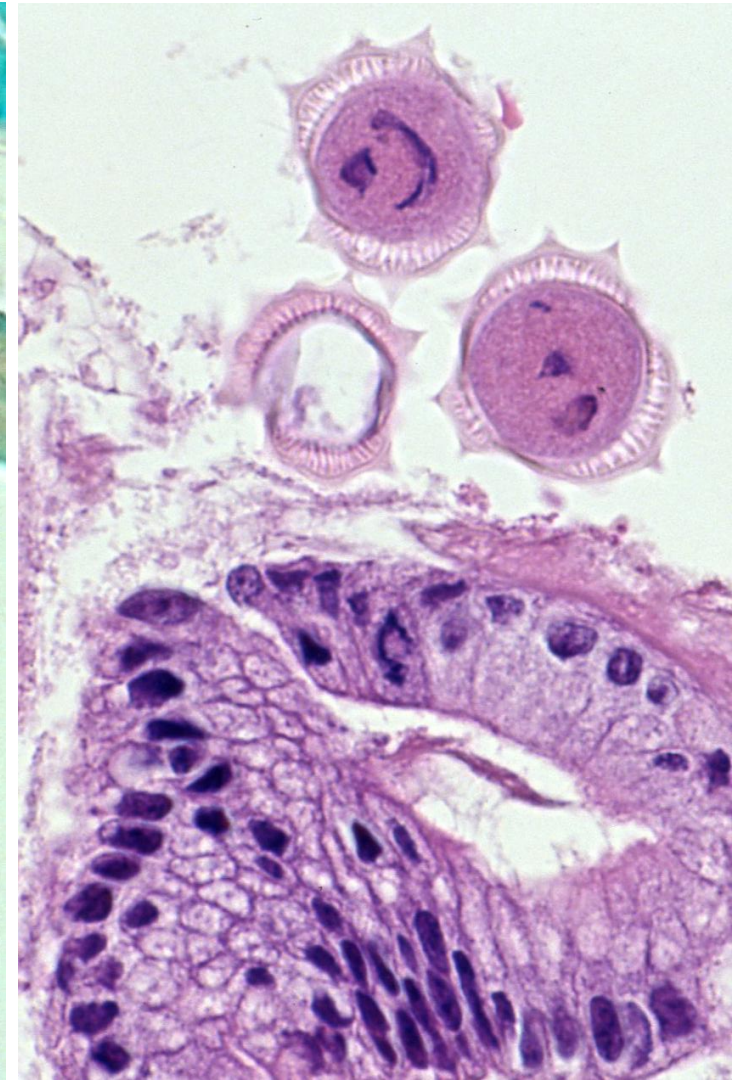
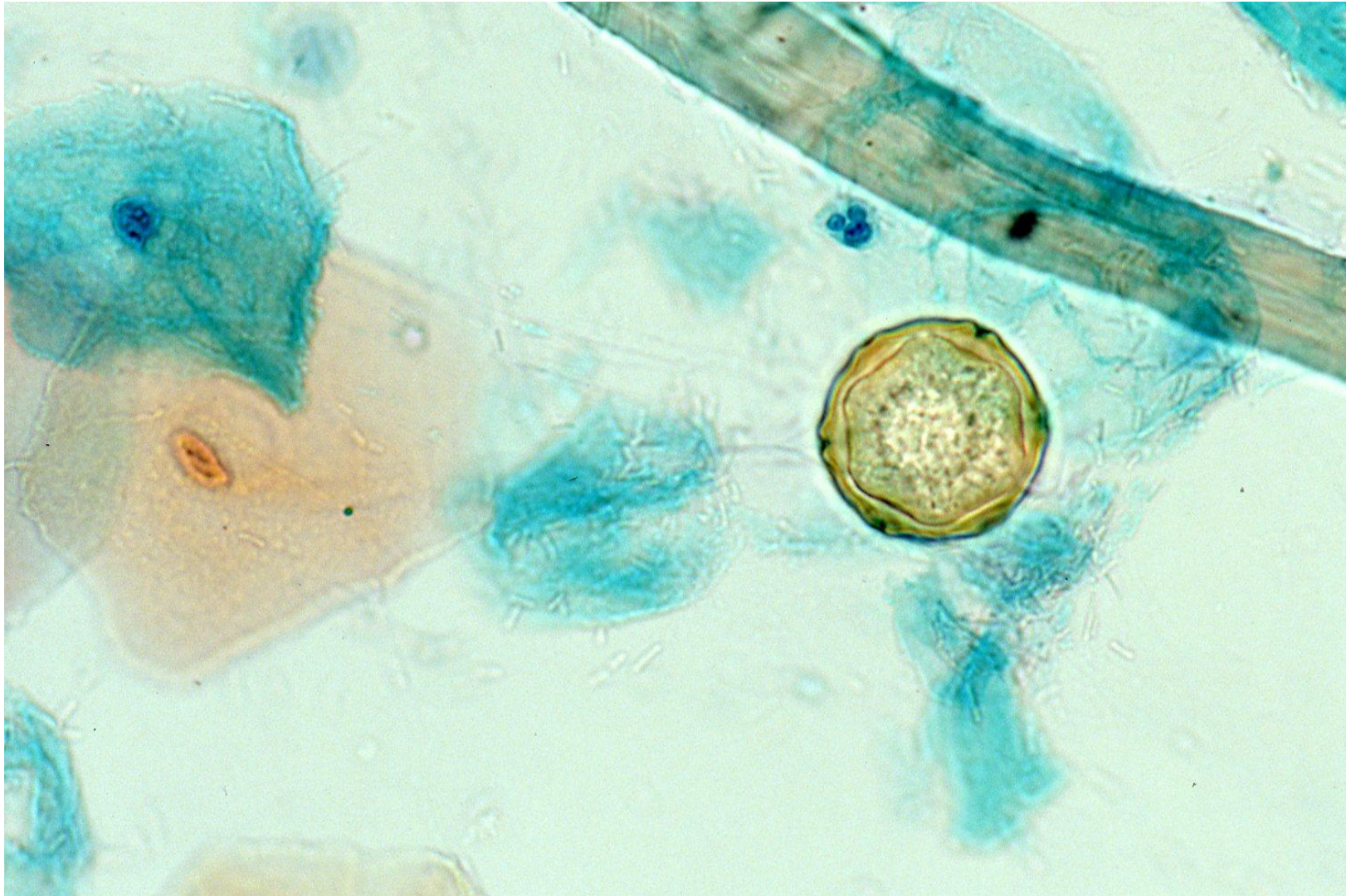
No. 16: Necrotizing vasculitis of Askanazy type seen in **tuberculous meningitis** (H&E). Fibrinoid necrosis with lymphocytic reaction is evident in the meningeal artery branch. The right panels display Ziehl-Neelsen stain (top) and immunostain for MPT64, a marker of *Mycobacterium tuberculosis* (bottom). The Askanazy-type angiitis is caused by massive infection of *M. tuberculosis* in the meningeal space.



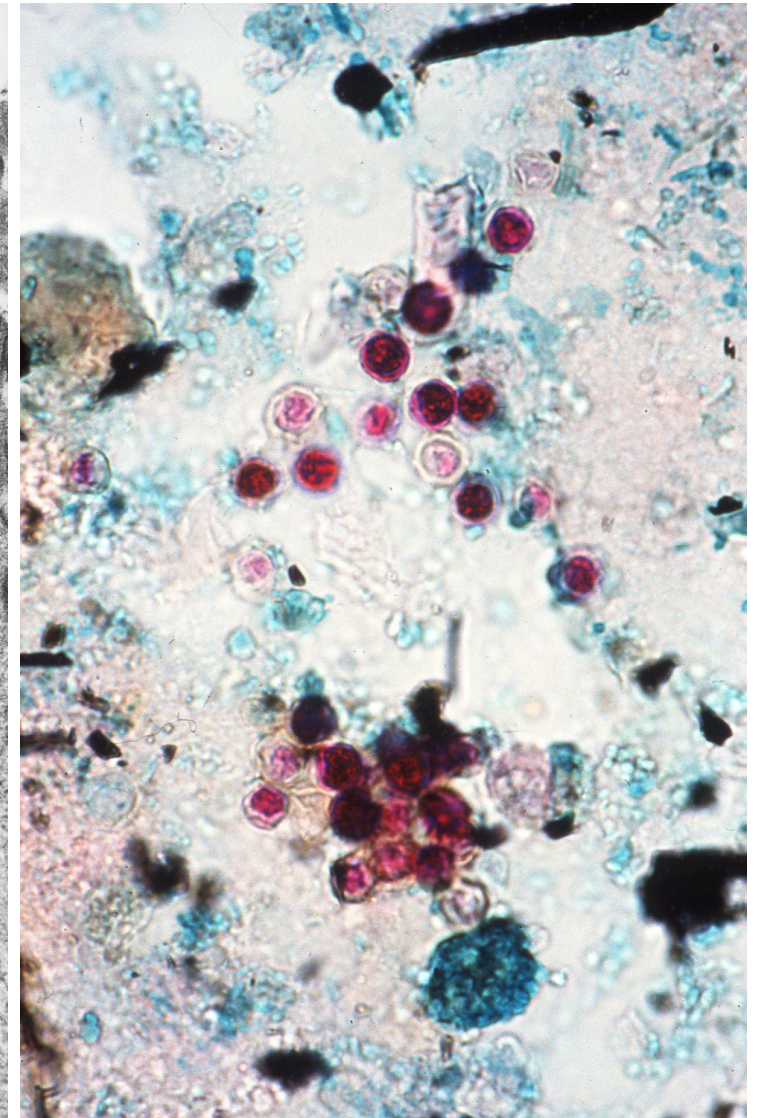
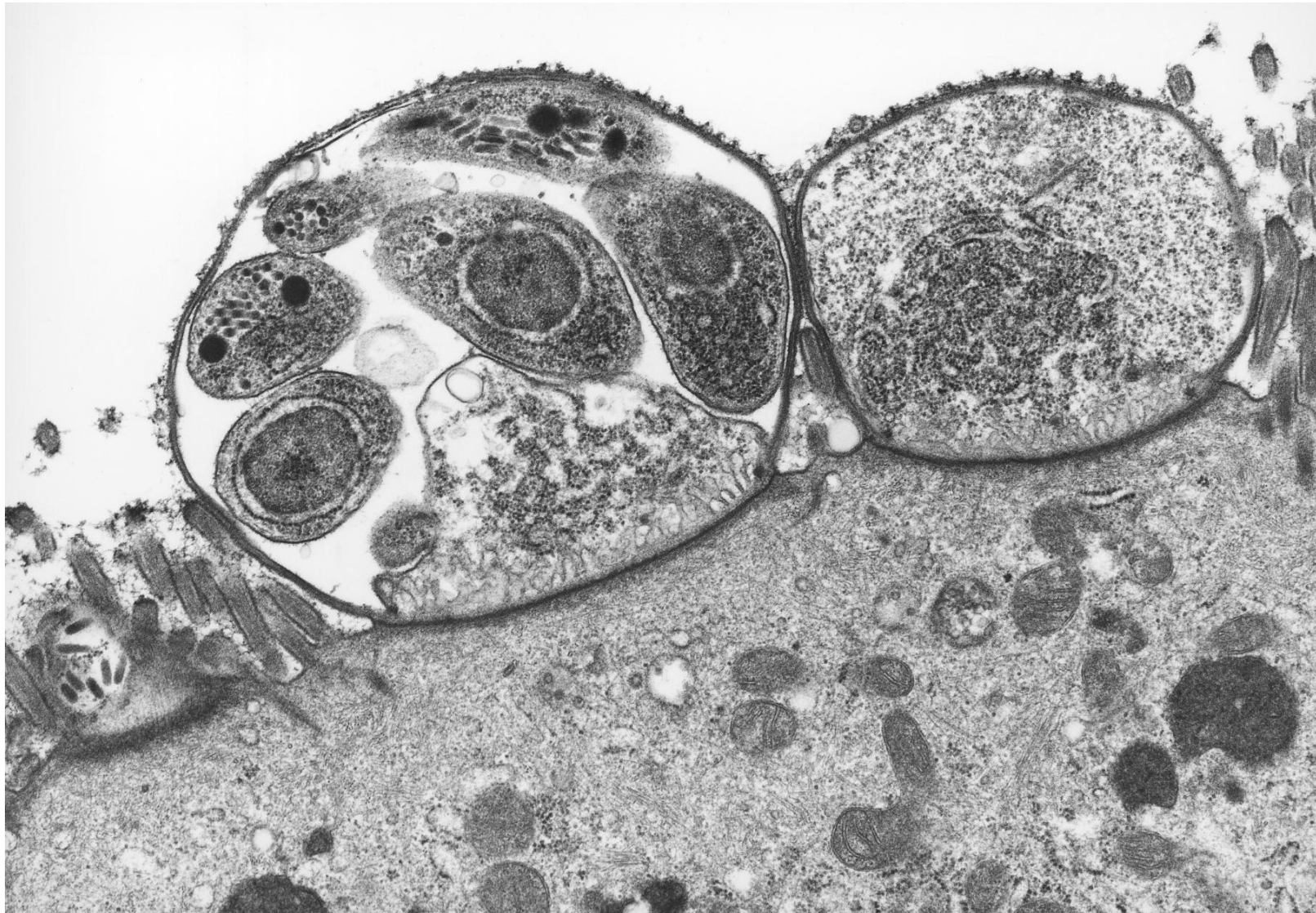
No. 17: Falciparum malaria (May-Giemsa). Infection of *Plasmodium falciparum* mediated by Anopheles mosquito is endemic in tropical areas, particularly in south Saharan Africa. Ring bodies are seen in red blood cells in the peripheral blood. High percentage of the red blood cells is infected, and single red blood cell contains two or more ring bodies. Black malaria pigment is seen in the cytoplasm of a monocyte. Right: The brain at autopsy reveals impaction of infected red blood cells with malaria pigment in the capillary lumen (H&E). The **cerebral malaria** is the main cause of death in this tropical fever.



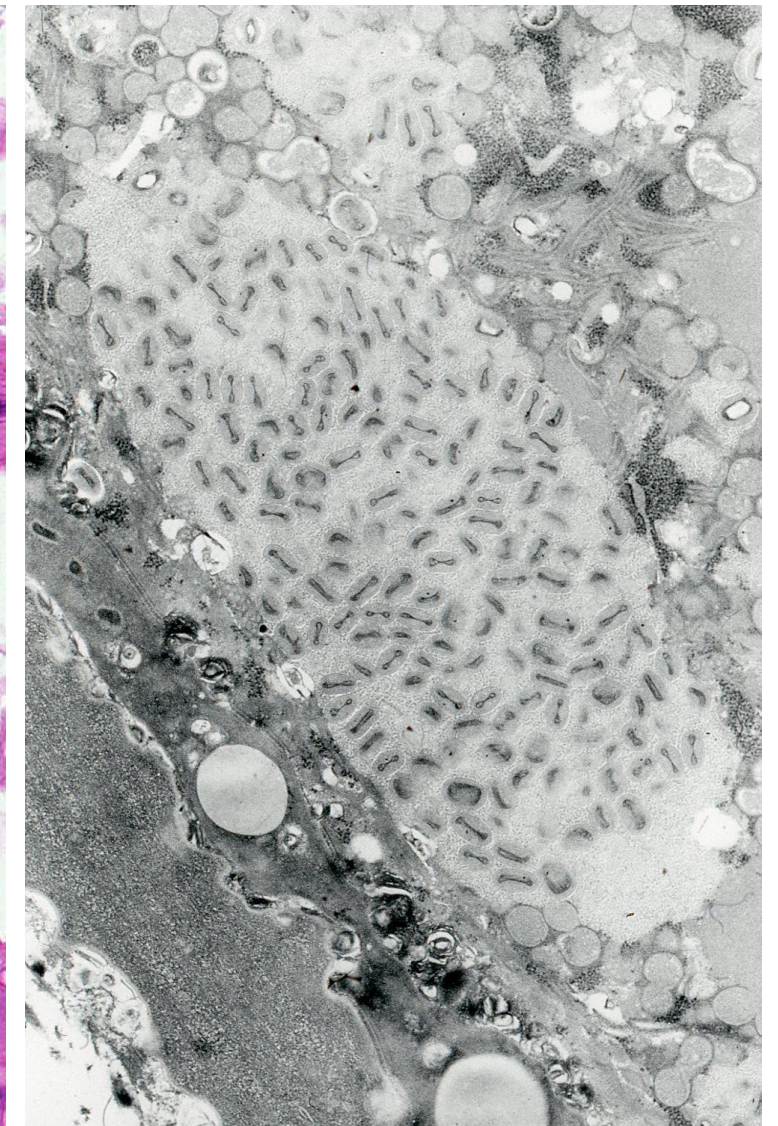
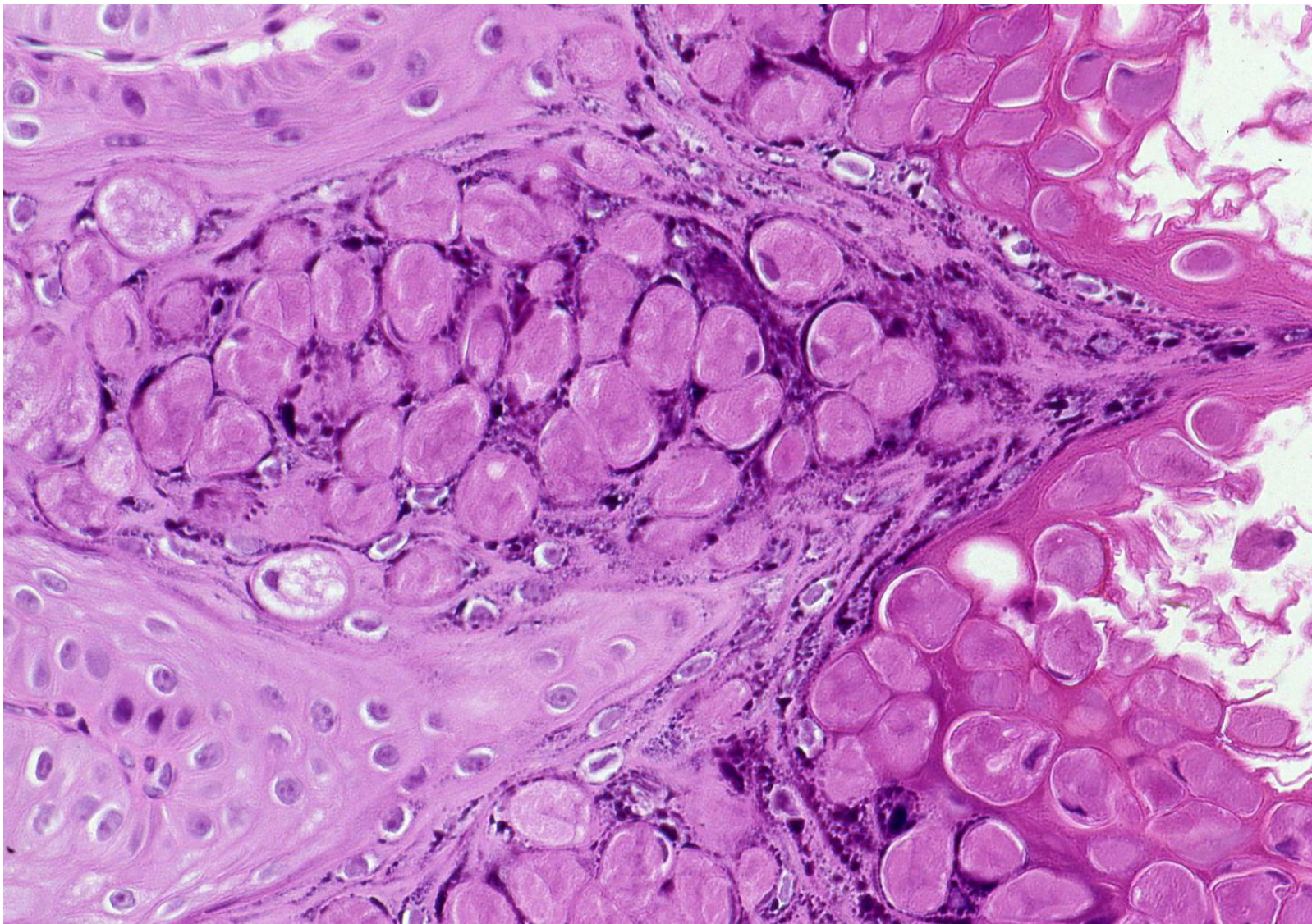
No. 18: *Rhinosporidium seeberi* infection (**rhinosporidiosis**) seen in a Bangladeshi (H&E). Biopsy from the nasal mucosa shows sporangia of varying sizes (10-350 μm). The large sporangium contains numbers of basophilic endospores and is positively stained with Grocott stain (right). Immature (small-sized) sporangia are devoid of endospore formation and Grocott-negative. Recent study has disclosed that the *R. seeberi* belongs to *Mesomycetozoea*, an organism categorized between the animal and algae.



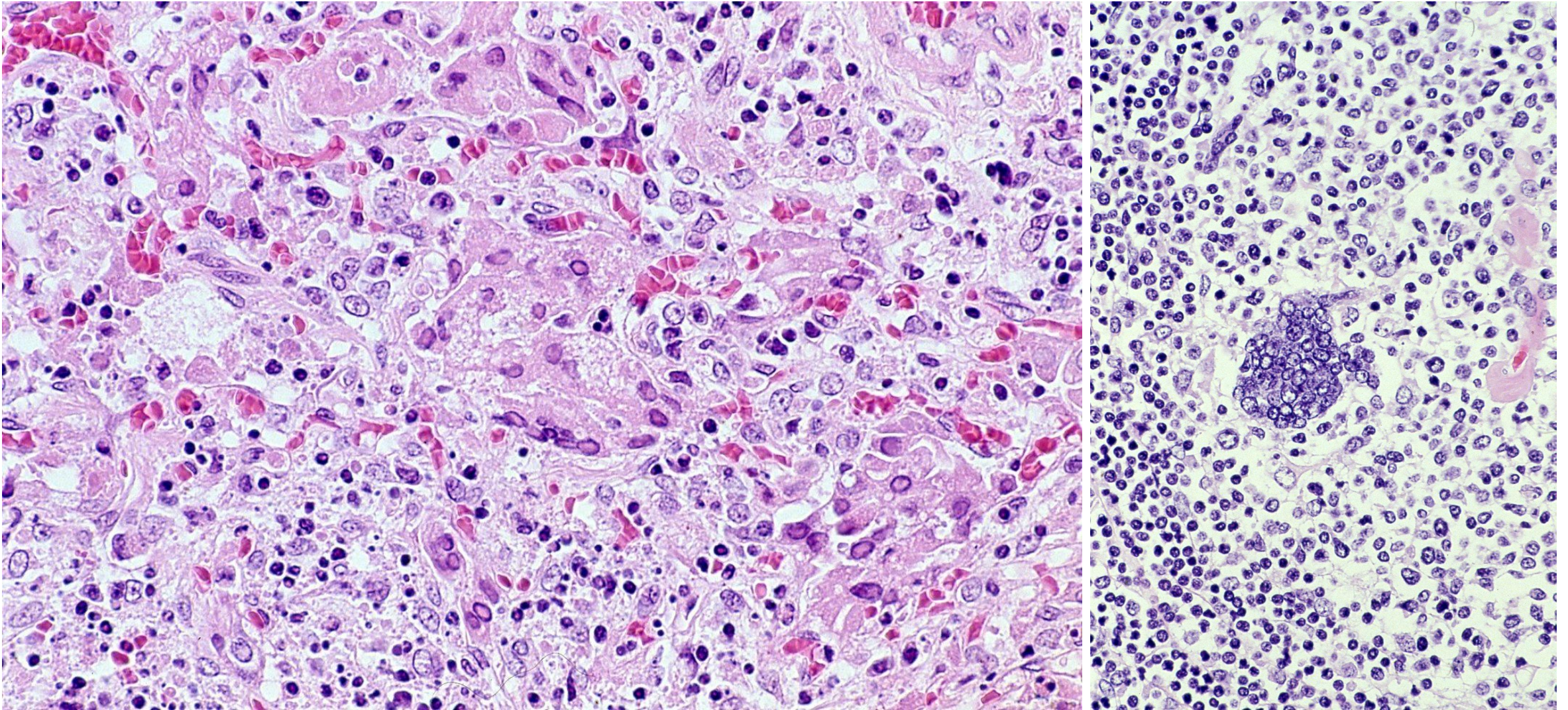
No. 19: A **pollen** contaminated onto cervical smear cytology (Papanicolaou). A round-shaped, 20-40 nm-sized and yellowish brown-colored pollen has a doubled structure of the exine (the outer cuticle) and the intine (the internal body). Spiculated pollens are also observed on the gastric biopsy specimen (right: H&E). The pollens are exogenous contaminants during the preparation of the pathology specimens.



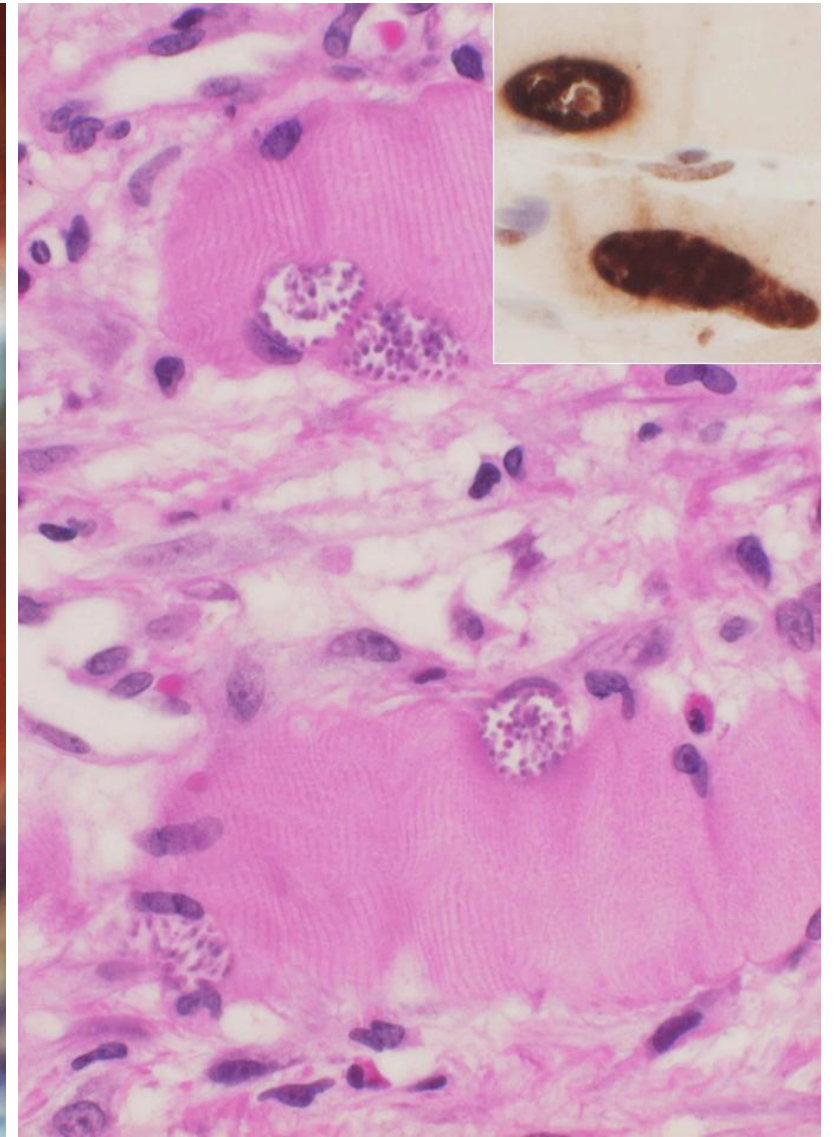
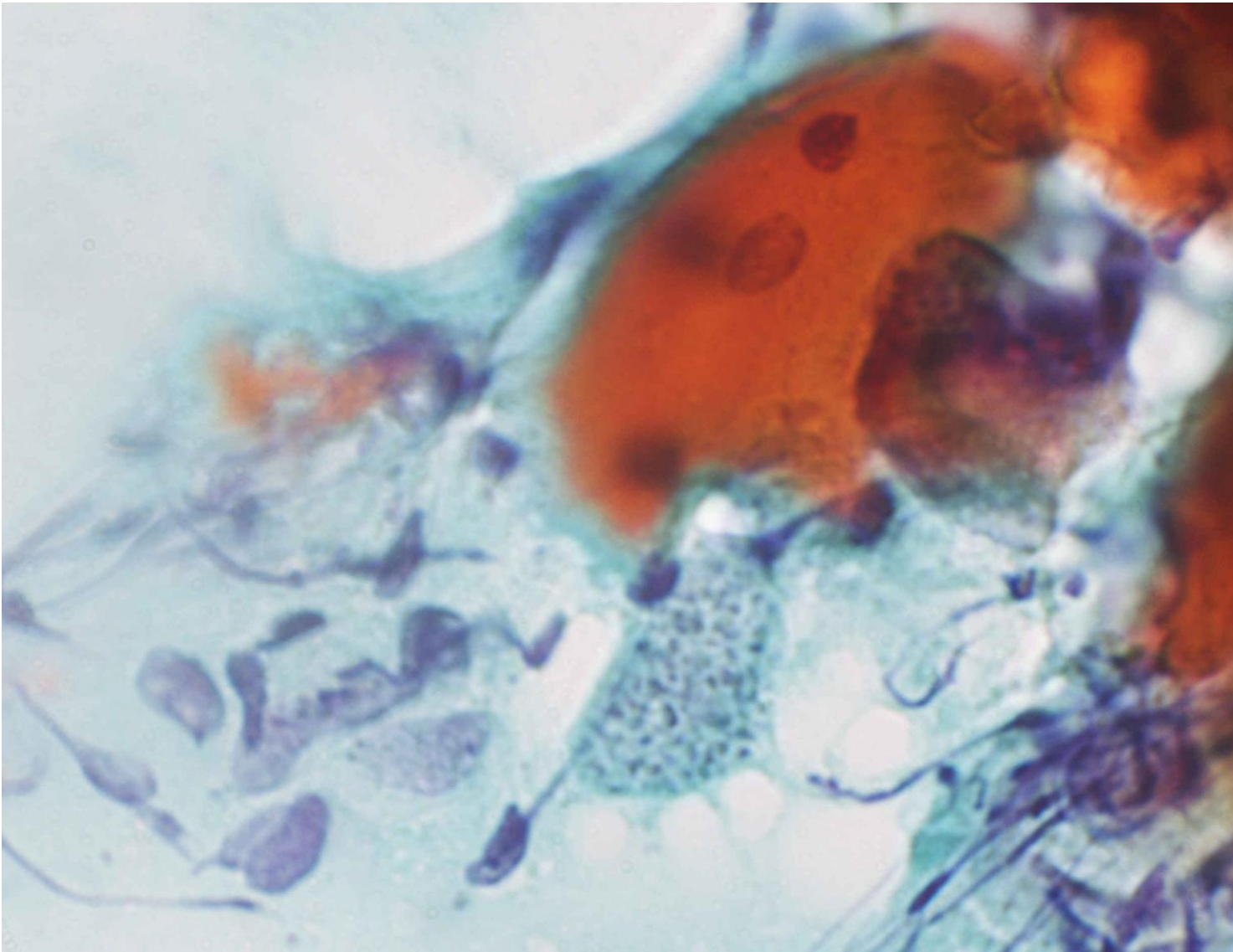
No. 20: *Cryptosporidium parvum* infection (**cryptosporidiosis**) of the ileal mucosa (electron microscopy). *C. parvum* infects the microvilli of the intestinal epithelial cells. The trophozoite and merozoite are observed. The merozoite contains asexually produced multiple meronts, and the meronts disseminate to other epithelial cells. Oocysts, formed after sexual reproduction, are excreted into the feces, and they are acid-fast (right: diarrheal stool, Ziehl-Neelsen).



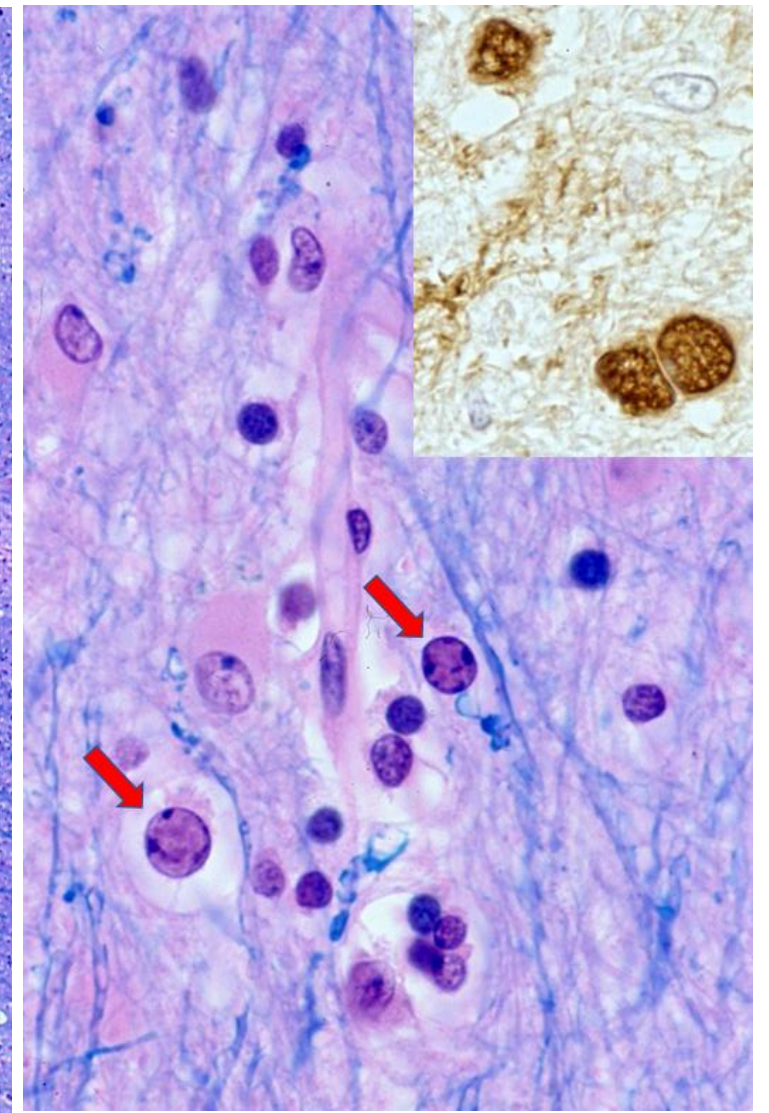
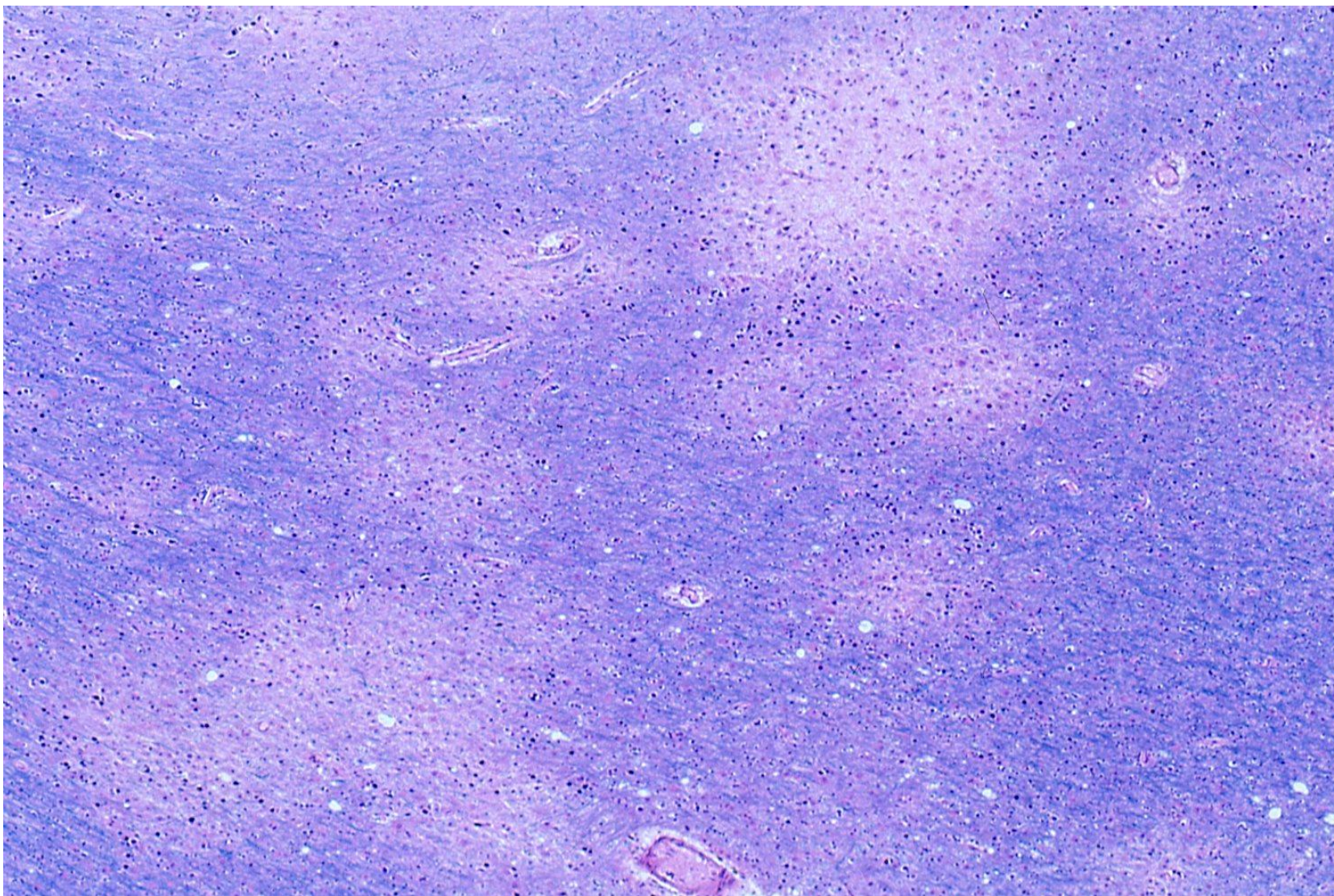
No. 21: Molluscum contagiosum (H&E). Molluscum contagiosum is a pediatric wart caused by infection of molluscum virus, a kind of pox DNA virus. In the adult, the warts are sexually transmitted. Infection mainly occurs in the hair follicle, and the formation of large eosinophilic intracytoplasmic inclusions is characteristic. The inclusions turn to be basophilic on the surface. Ultrastructurally, the cytoplasm is filled with largest-sized virions with peripheral envelopes and central array-shaped nucleoids (right). Their size is comparable with *Chlamydia*.



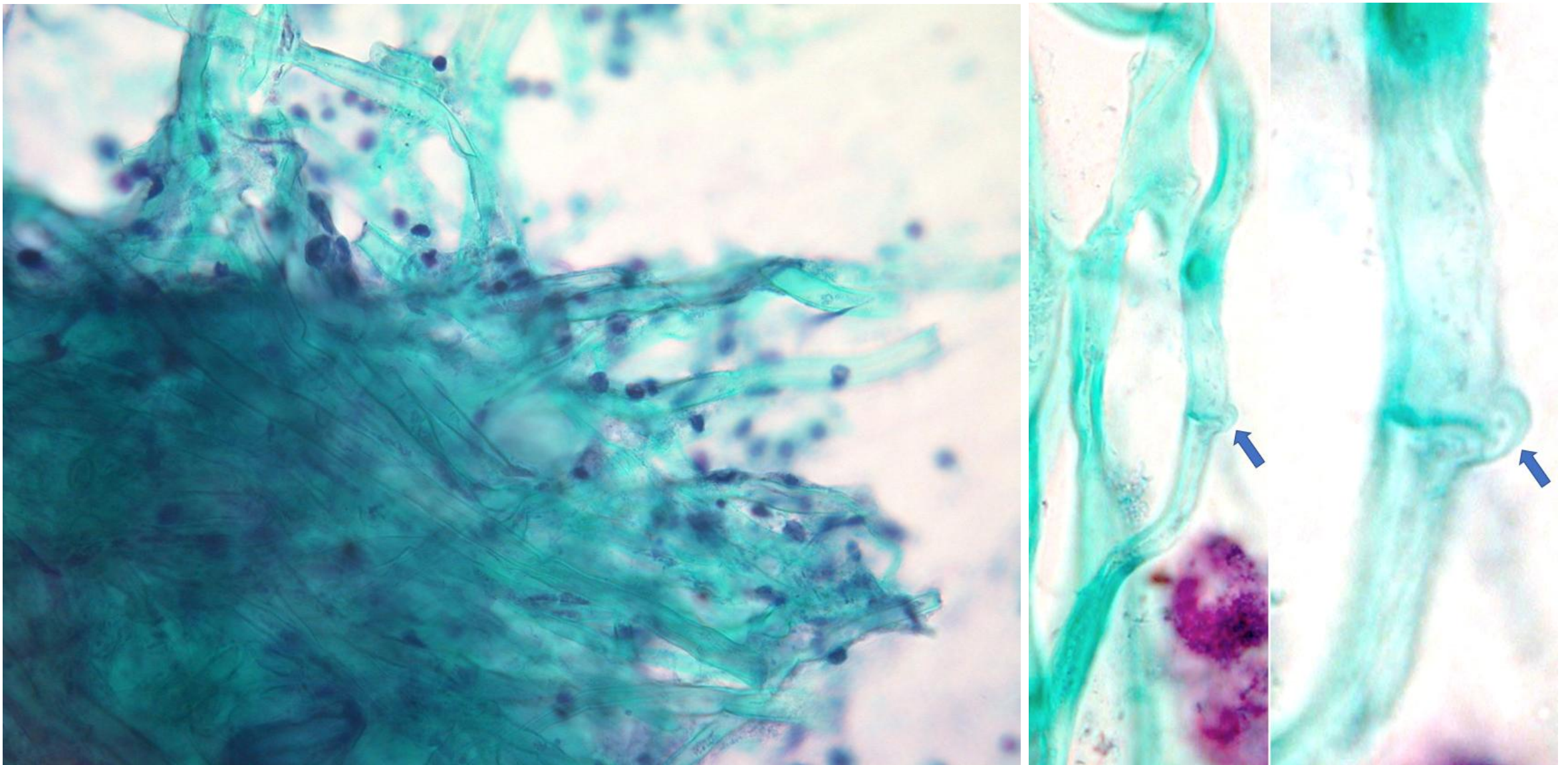
No. 22: Measles pneumonia (H&E). The autopsied lung reveals interstitial pneumonia called giant cell pneumonia. Type II alveolar epithelial cells show multinucleation and intranuclear measles viral inclusion body formation. Lymphocytic infiltration is associated. Right: In the lymph node, formation of multinucleated Warthin-Finkeldey giant cells without nuclear inclusions is characteristic (H&E).



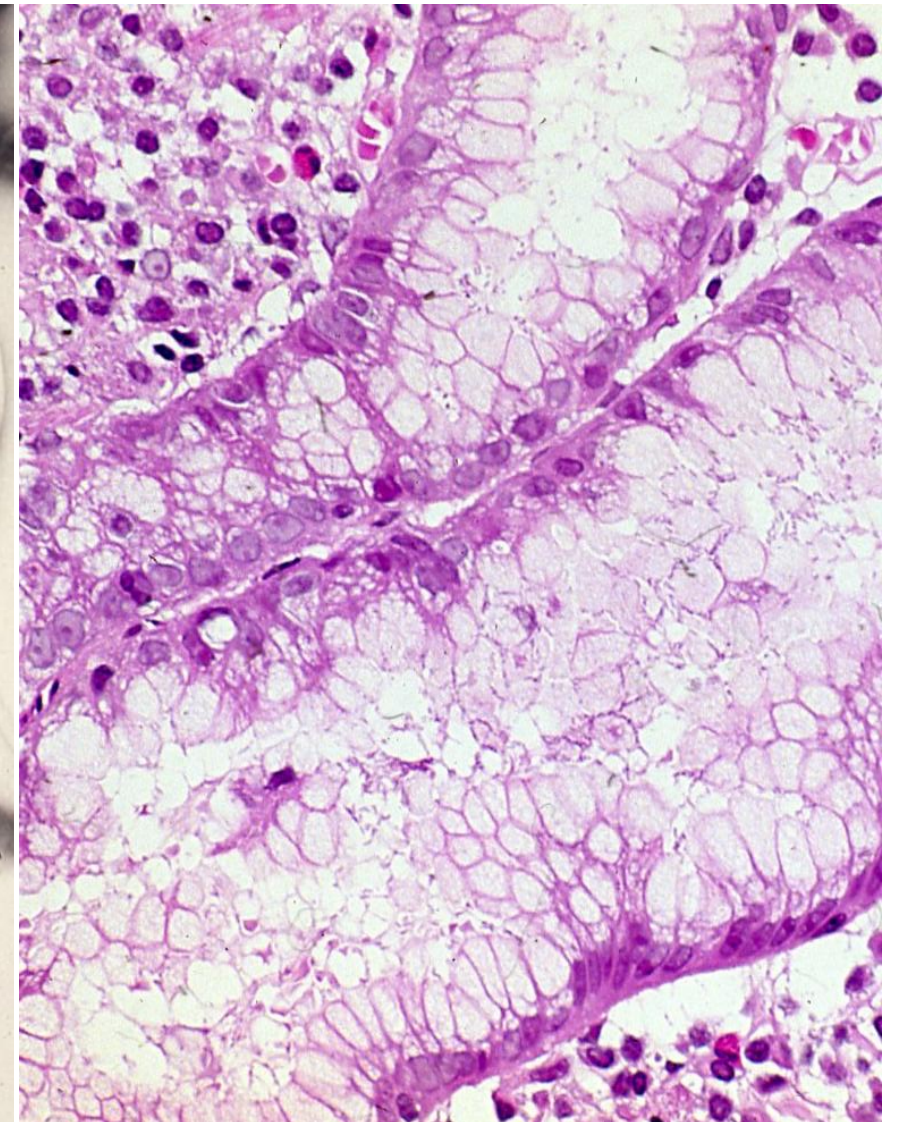
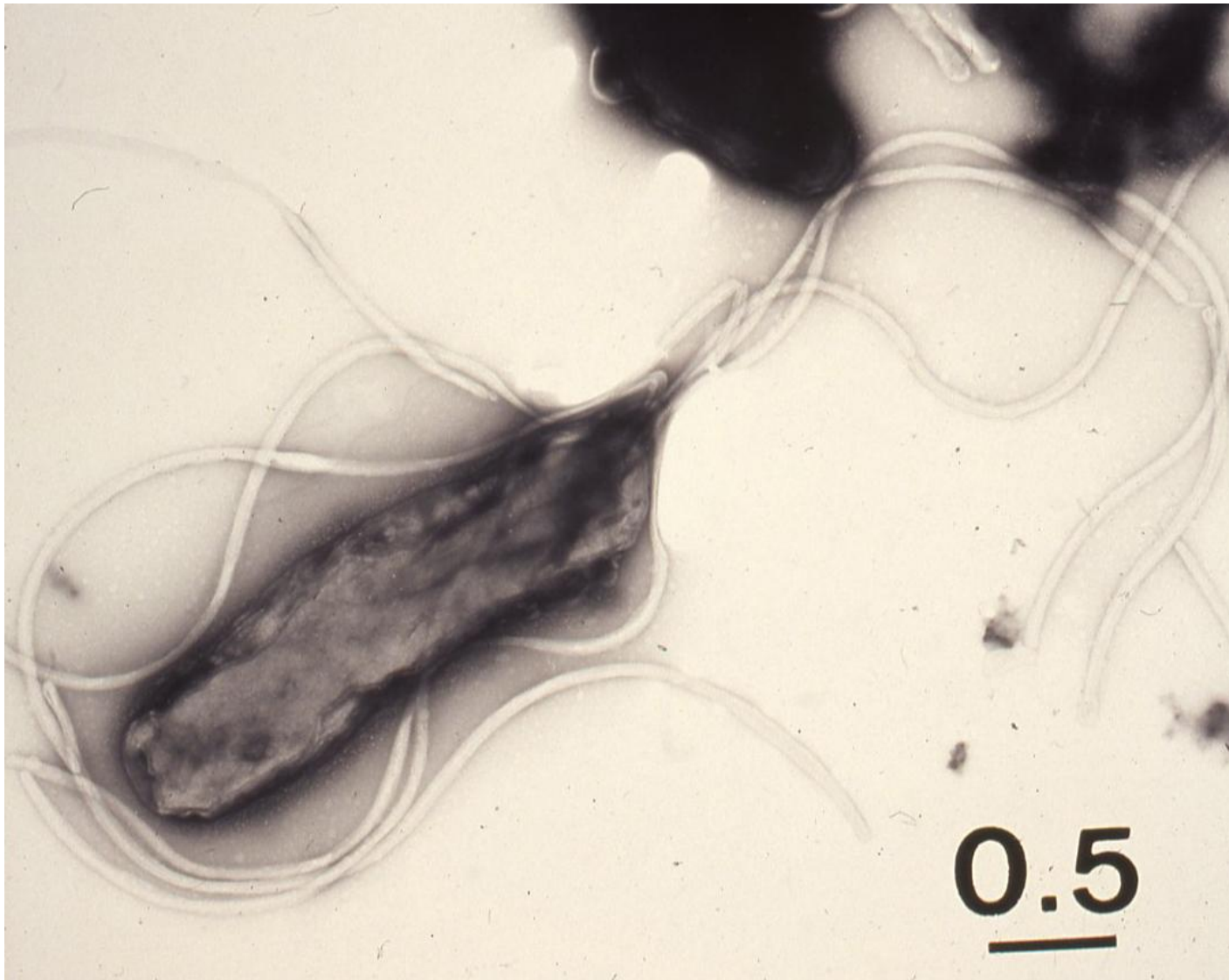No. 23: *Toxoplasma myositis* (aspiration cytology: Papanicolaou). An adult patient under steroid therapy complained of pain in the neck muscle. Aspiration cytology reveals a pseudocyst filled with basophilic granules (tachyzoites), adjacent to the orange-stained regenerative striated muscle cell. Right: Biopsy specimen also shows pseudocysts in the cytoplasm of the muscle cells (H&E). Inset exhibits the positivity of *Toxoplasma gondii* antigen by immunostaining.



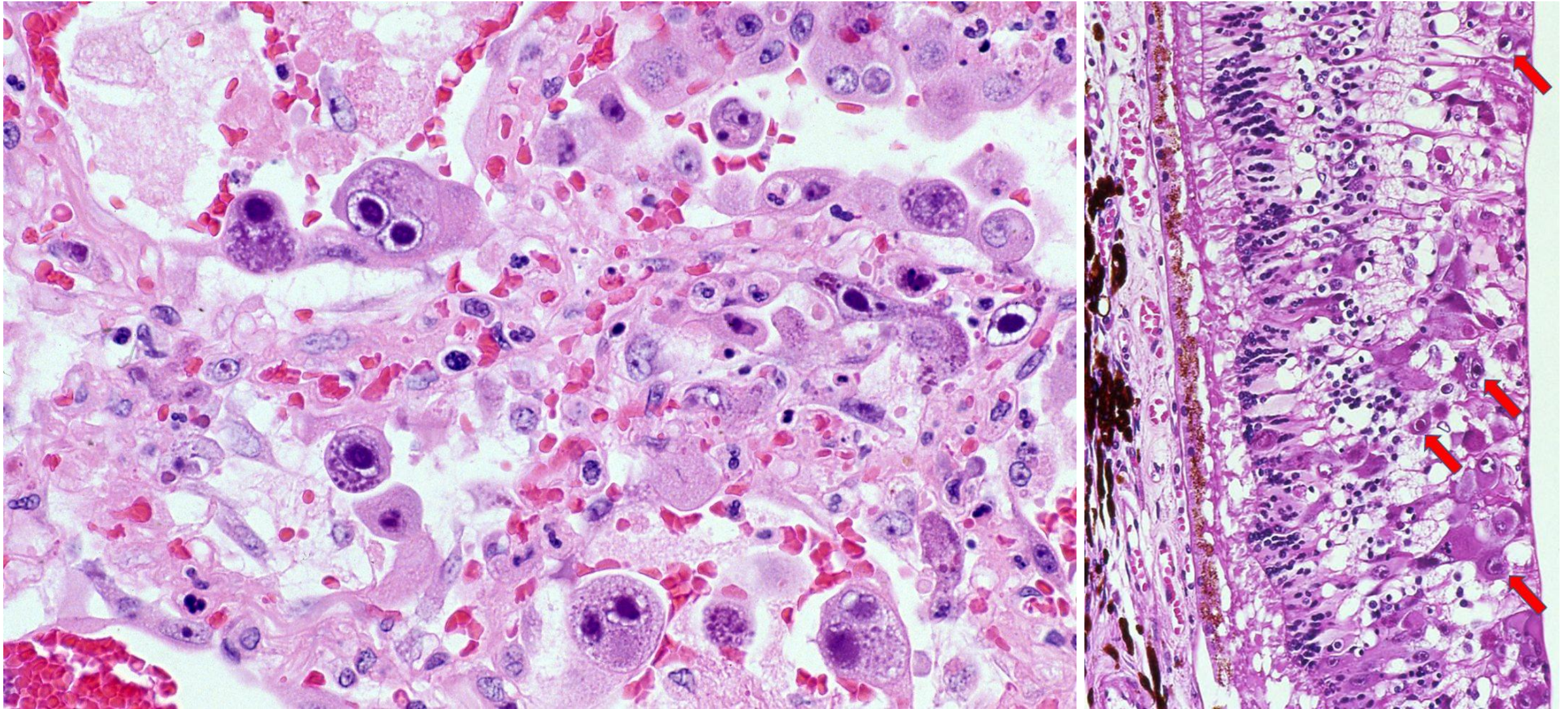
No. 24: Progressive multifocal leukoencephalopathy (LFB-HE). A lethal brain lesion seen in an adult patient under steroid treatment. Demyelinated lesions showing decreased blue color are multifocally noted in the white matter of the brain. The normal myelinated fibers are stained blue. Right: Oligodendroglial cells, normally giving myelination, have viral intranuclear inclusions (arrows) (LFB-HE). Inset exhibits JC viral antigens in the nuclei of oligodendroglia (Immunostaining for JCV antigens).



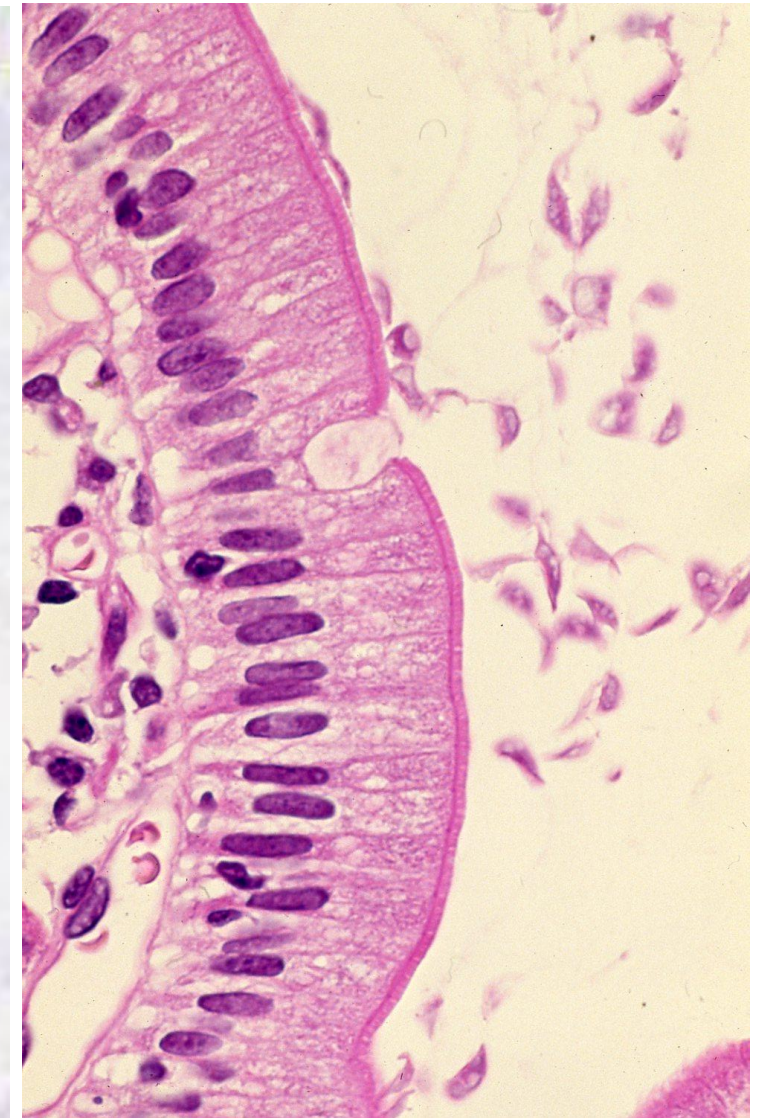
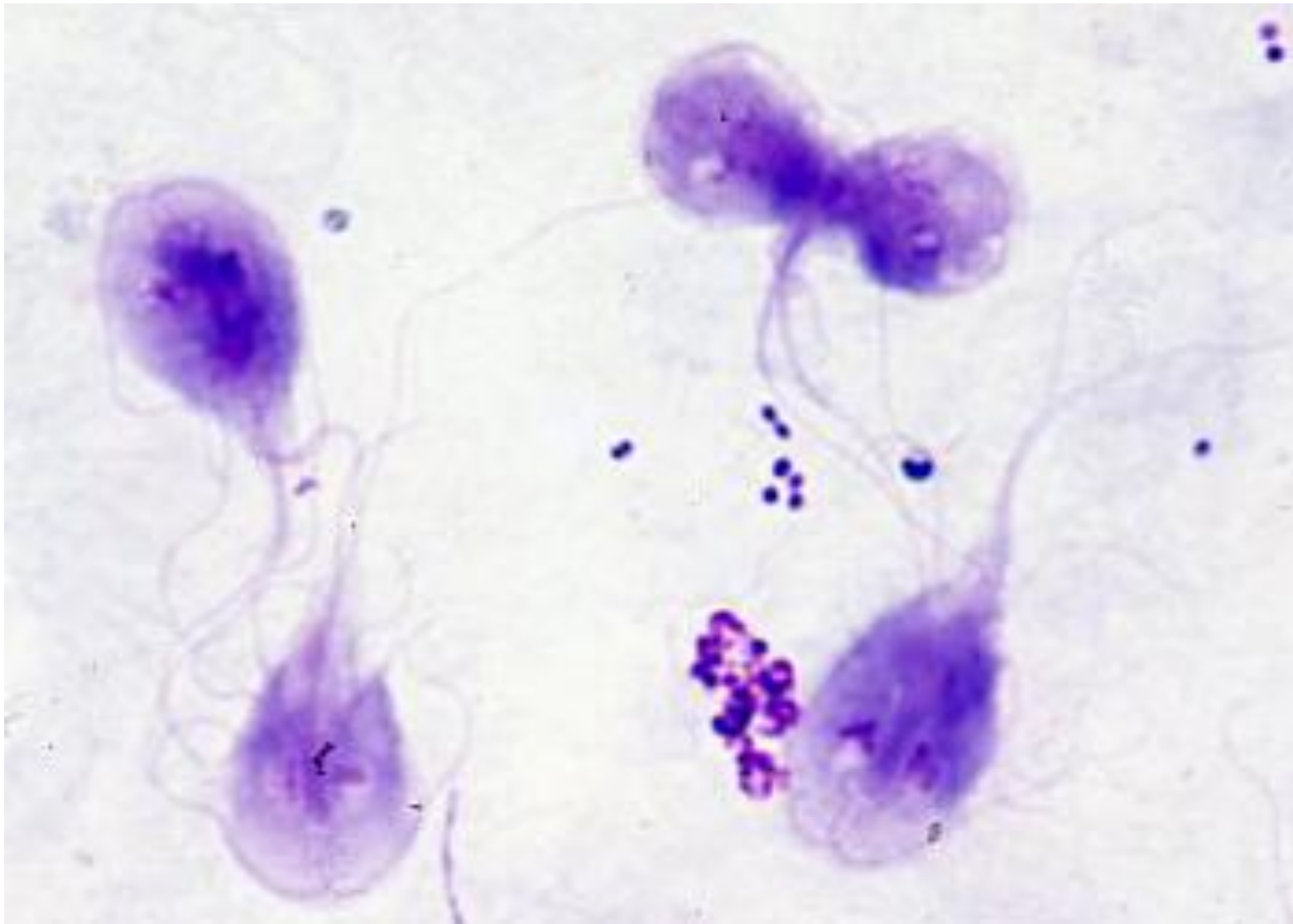
No. 25: Aspiration of mushroom (sputum cytology, Papanicolaou). Aspiration pneumonia is an important cause of death of aged individuals in Japan. The sputum cytology happens to contain a piece of aspirated mushroom, microscopically quite resembling *Aspergillus* hyphae. Close examination discloses clamped septa with clamped connections (arrows), identifying the origin of the mushroom cells (right: Papanicolaou).



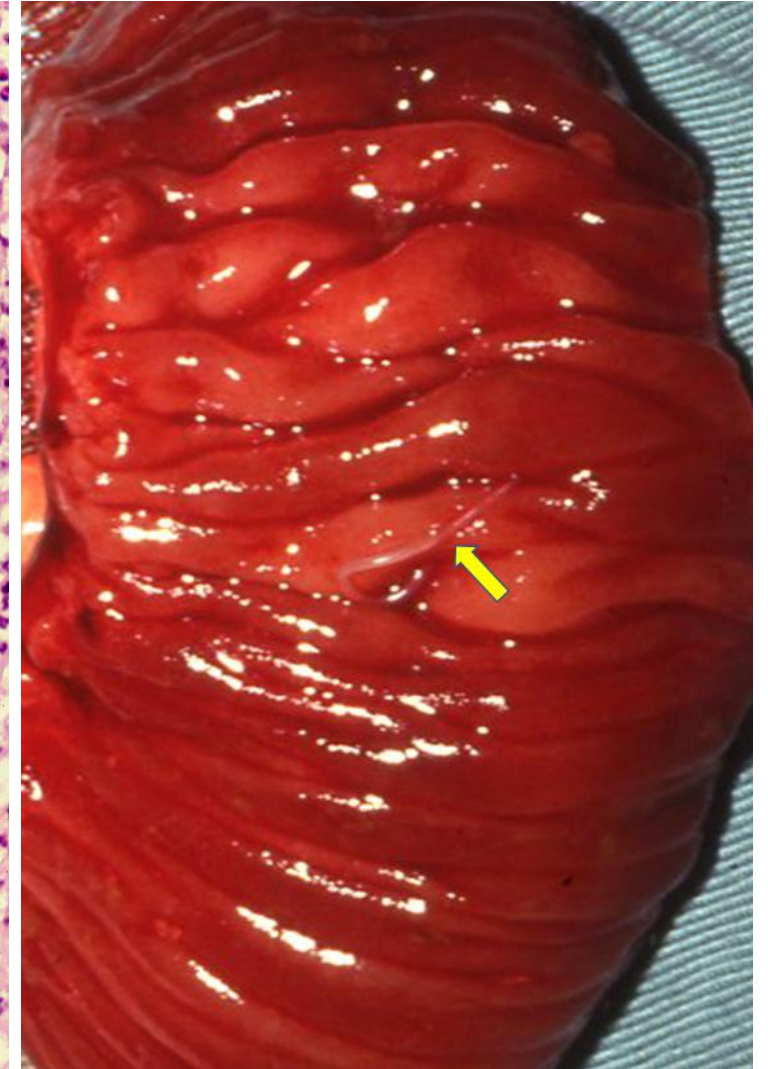
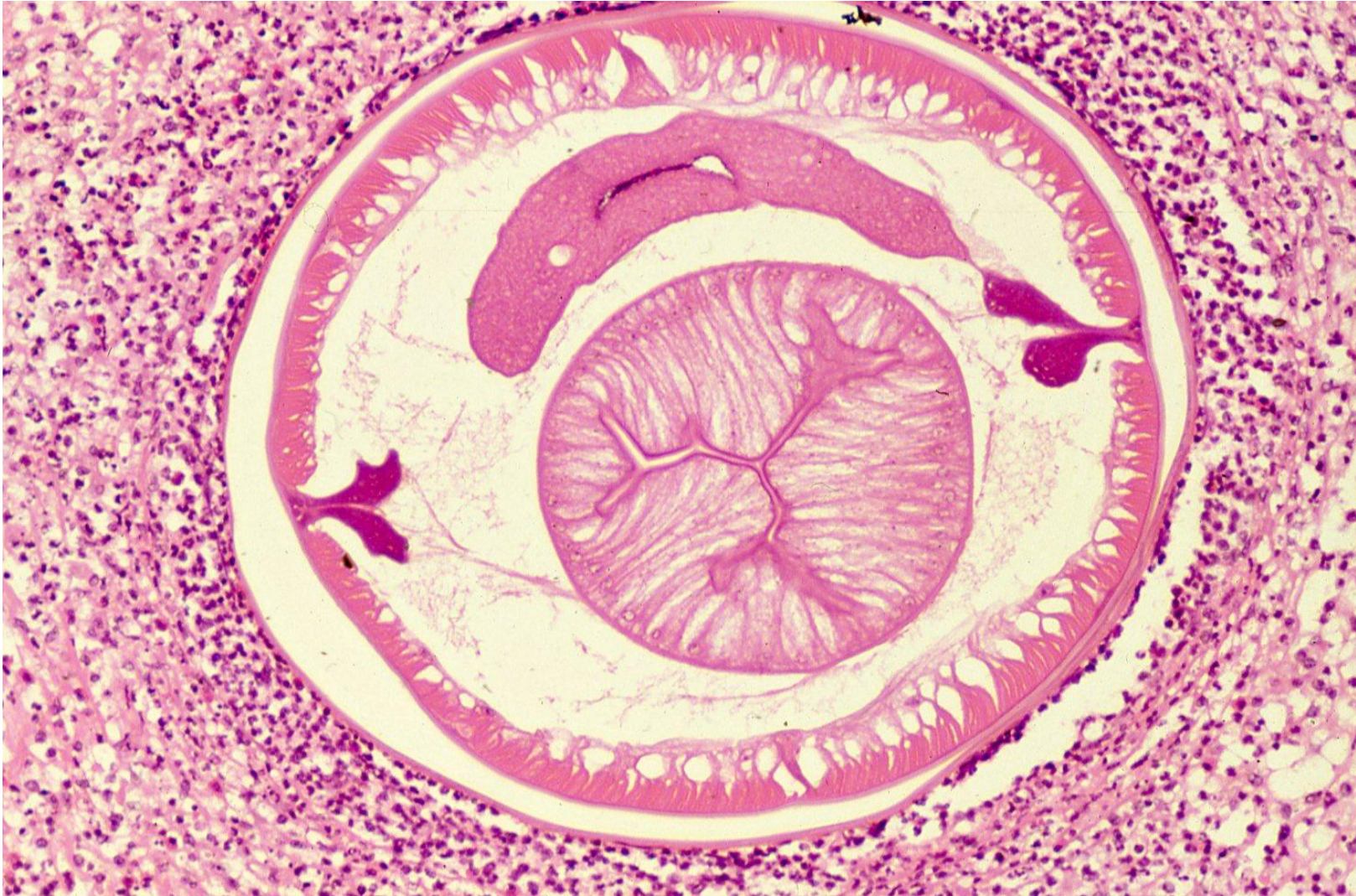No. 26: *Helicobacter pylori* infection of the gastric mucosa (negative staining in electron microscopy). A total of 6 flagellae are seen at one pole of the 3 μm -long spiral bacterium. The bacteria move quickly by using helicopter-like motion of the flagella. Right: Gastric biopsy reveals infection of basophilic *H. pylori* cells on the surface mucous columnar epithelial cells, provoking chronic active gastritis (H&E).



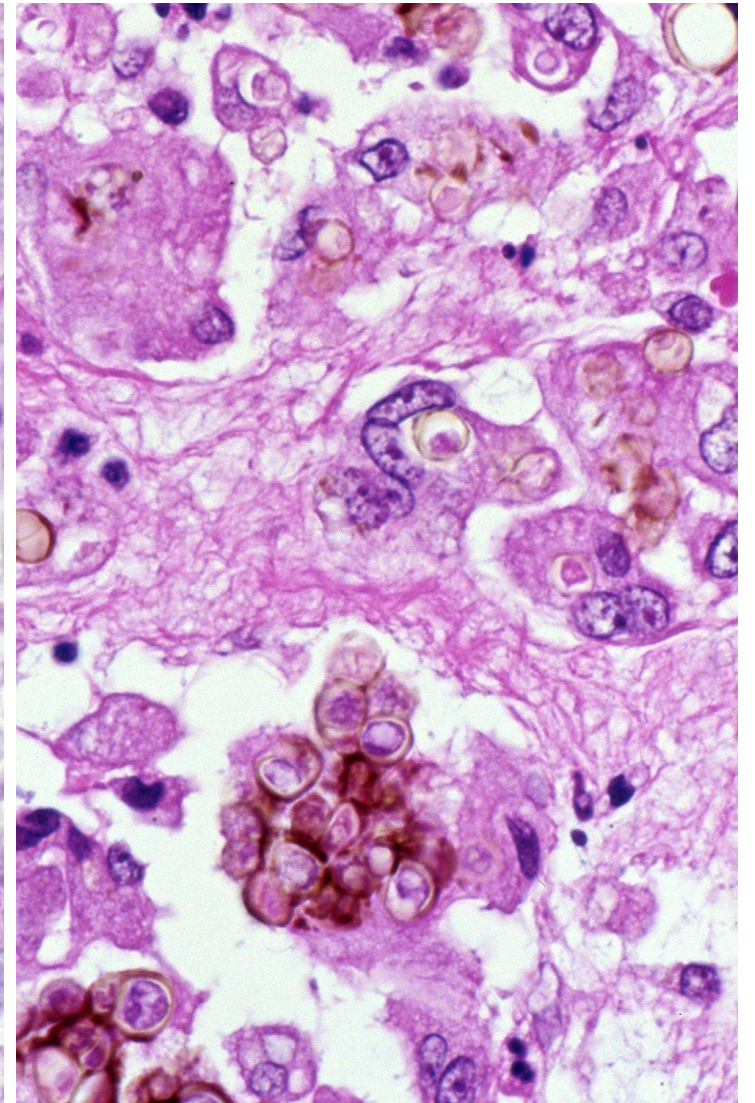
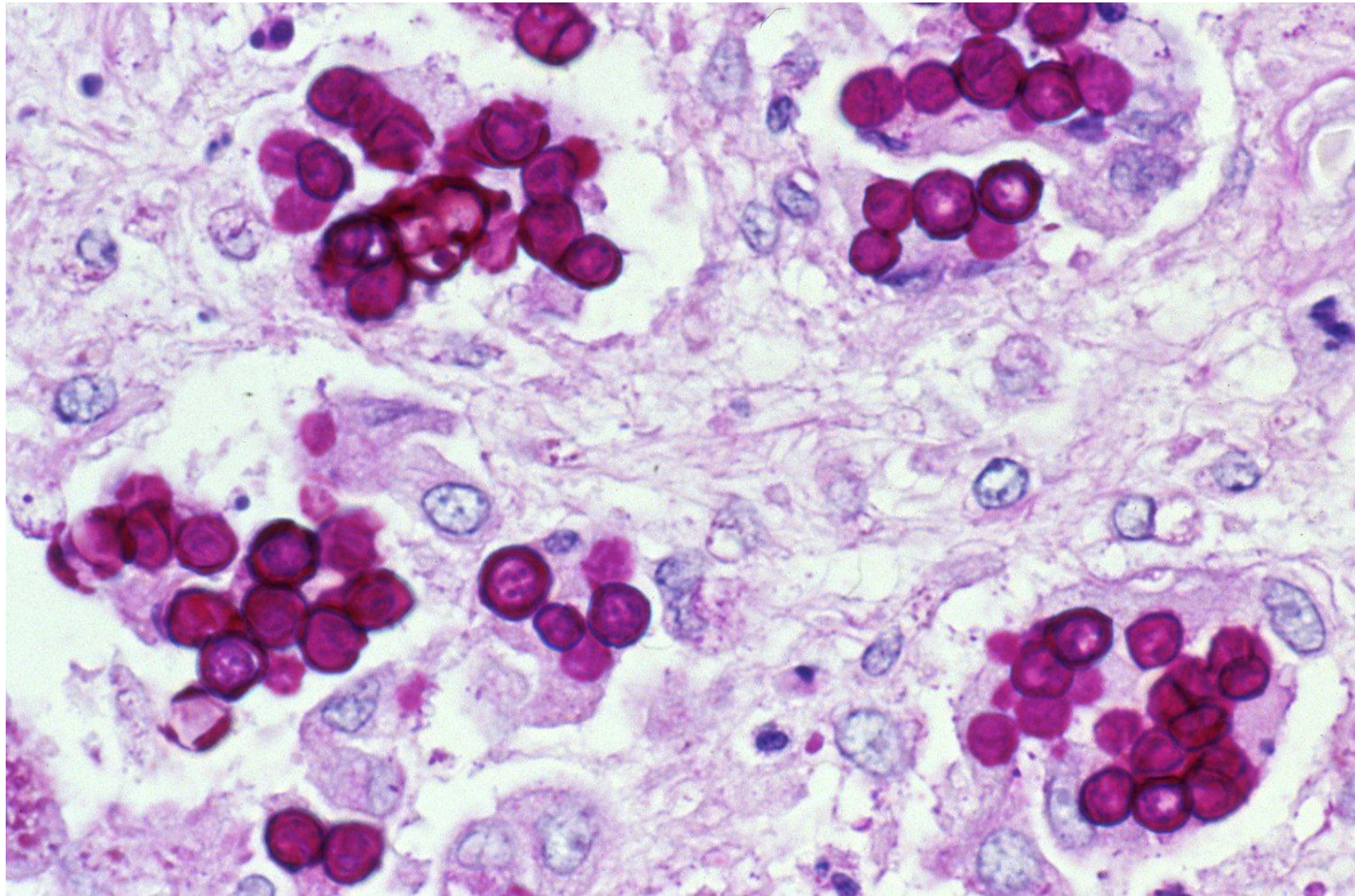
No. 27: Cytomegalovirus infection causing opportunistic interstitial pneumonia (H&E). Intranuclear basophilic inclusions are seen in the enlarged type II pneumocytes. "Owl eye appearance" is noteworthy. Cytoplasmic granular inclusions are also associated. Right: retinal infection of CMV in an AIDS patient (arrows indicate viral inclusions in neurons) (H&E). Retinal CMV infection causes progressive blindness.



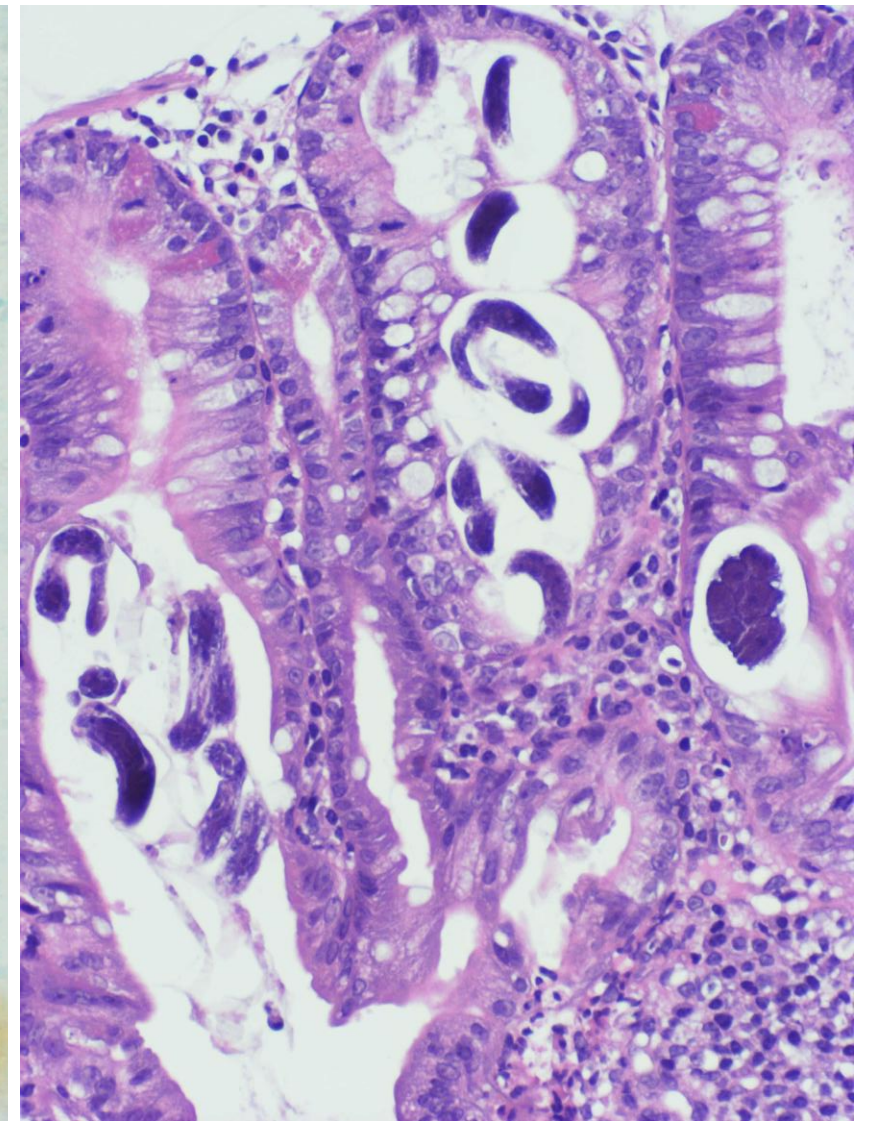
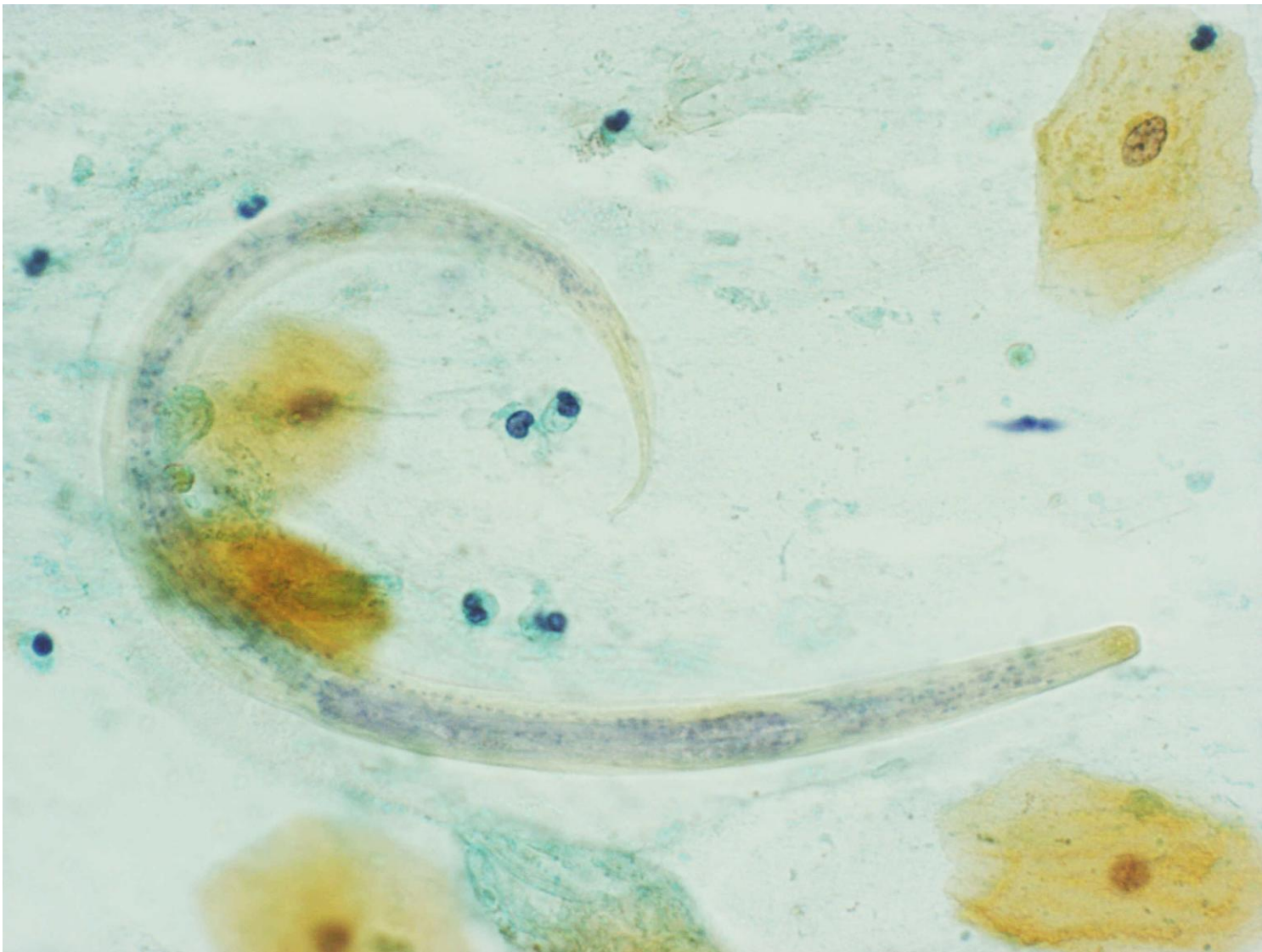
No. 28: ***Giardia lamblia*** infection in the bile (May-Giemsa). Flagellated trophozoites of *G. lamblia* (*G. duodenalis*) are co-infected with coccidial bacteria in the bile. Two symmetrically arranged nuclei are observed. Right: Duodenal biopsy reveals infection of crescent-shaped protozoa on the mucosal surface (H&E). *G. lamblia* commonly infects the duodenum and gallbladder.



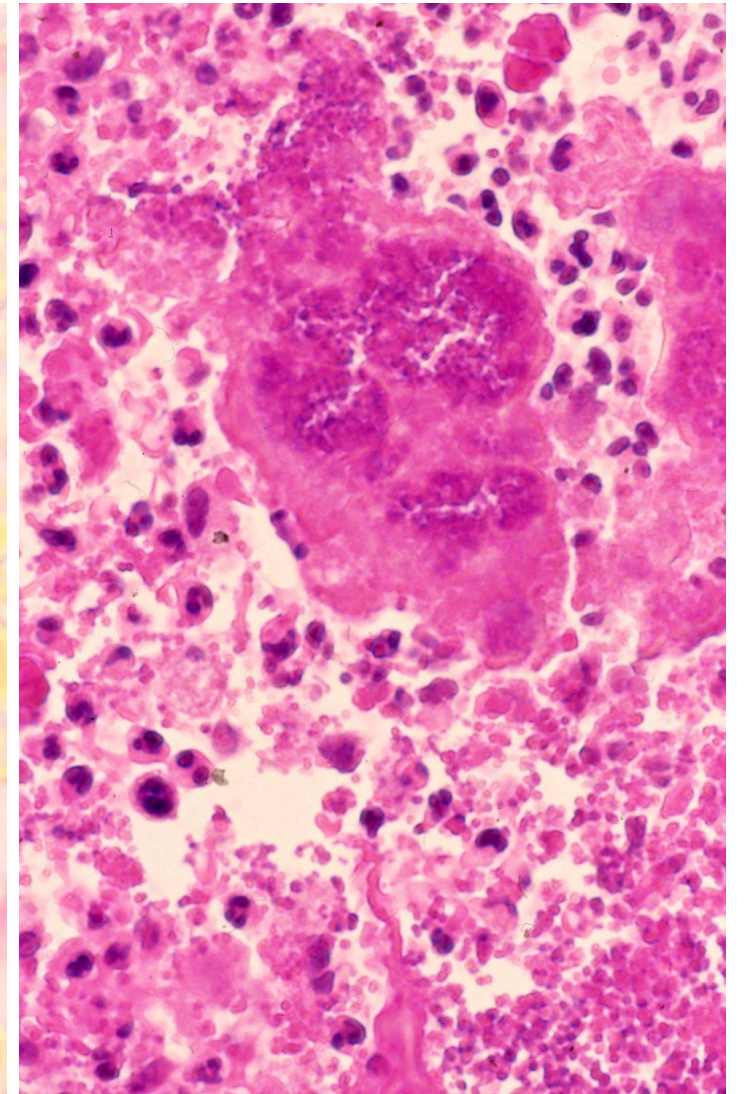
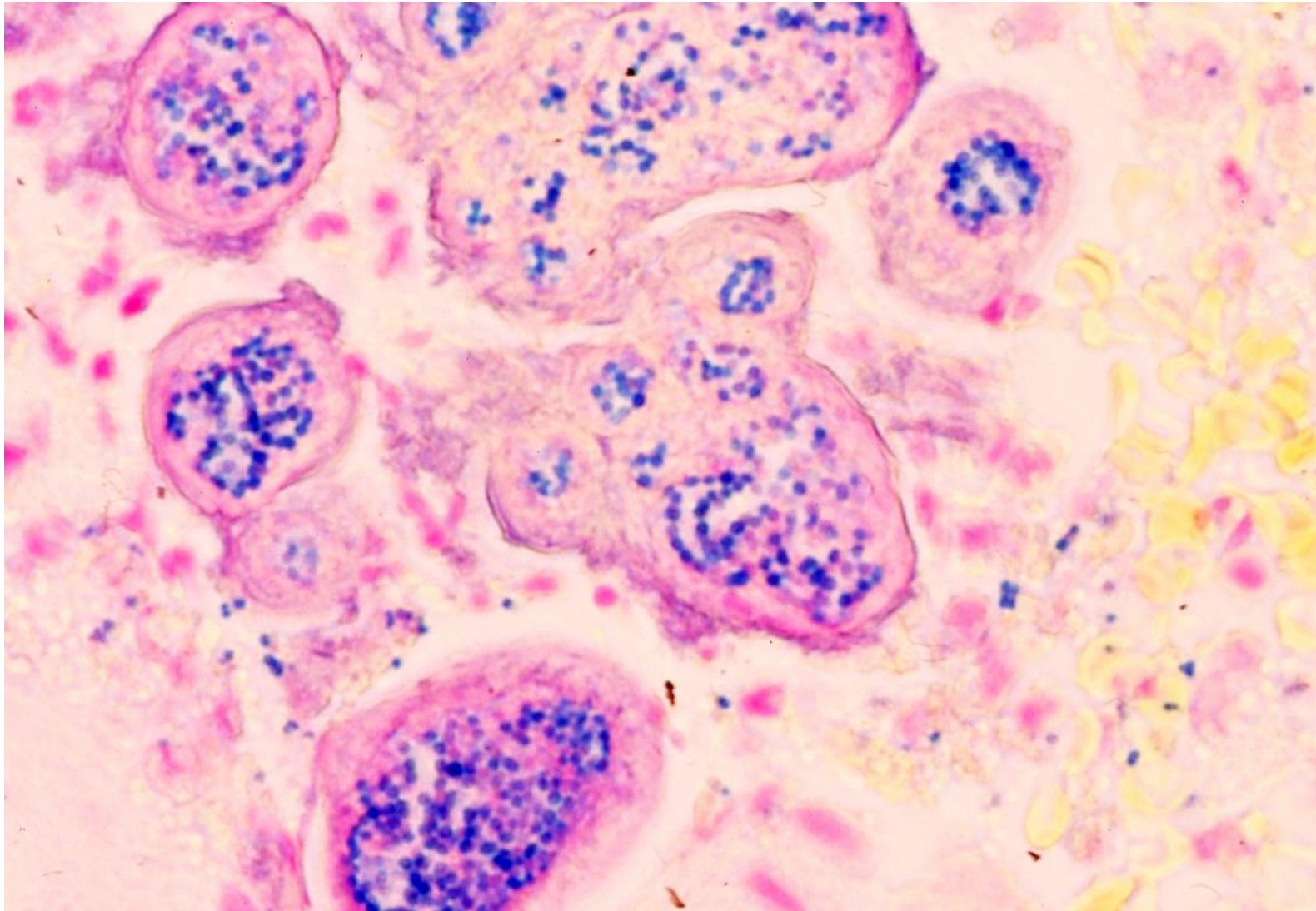
No. 29: Intestinal anisakiasis. The cut surface of the body of *Anisakis simplex* seen in the submucosal layer of the small intestine. Well-developed muscular coat, gut, Renett cell (an elongated eosinophilic structure) and a pair of clover-shaped lateral chords are observed. Eosinophilic reaction is evident around the nematode. Right: a thread-like white-colored, and 3 cm-long nematode is stuck in the hyperemic and edematous gut mucosa (arrow) (gross appearance).



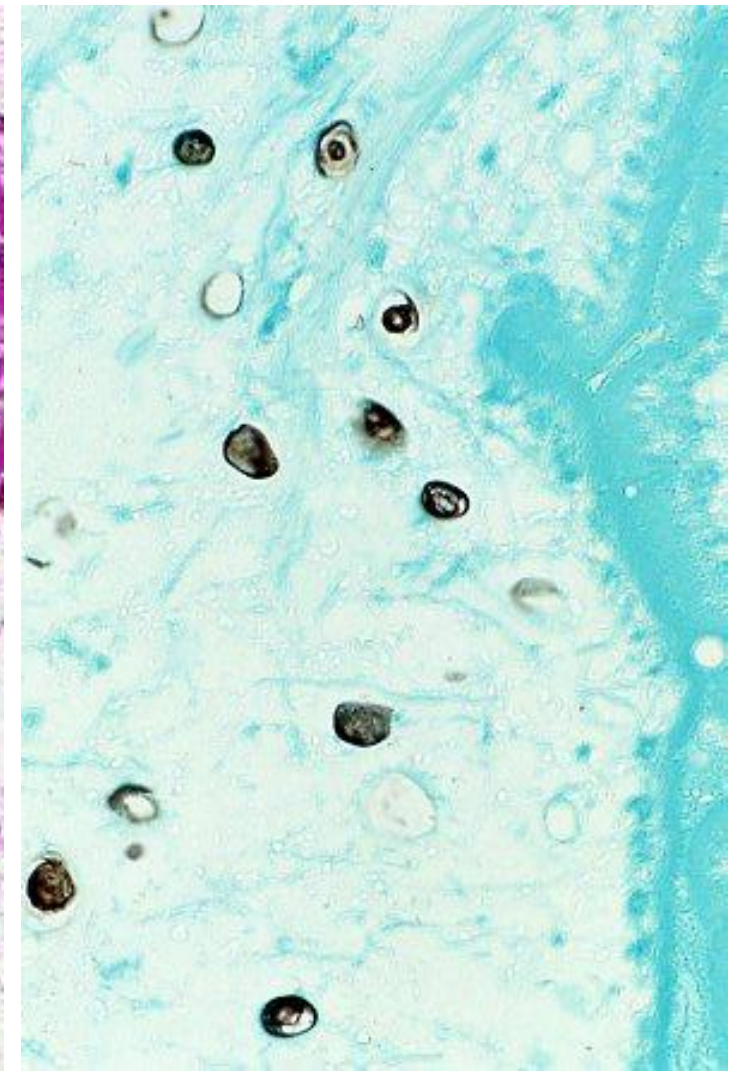
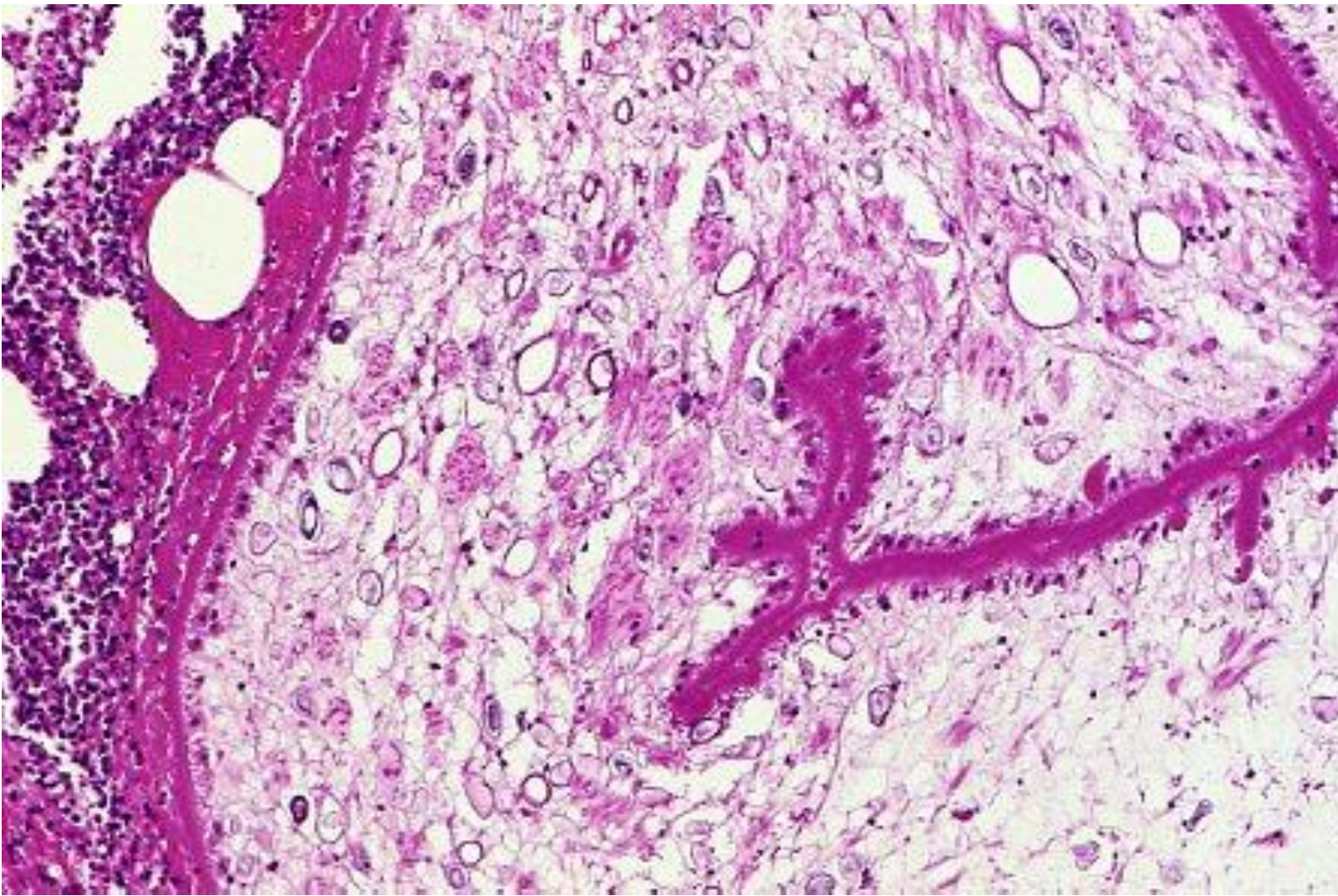
No. 30: Chromomycosis (PAS reaction). Numbers of PAS-reactive sclerotic cells are seen in the cytoplasm of macrophages located at the site of the artificial A-V shunt for hemodialysis. Right: the sclerotic cells contain brown-colored melanin pigment (H&E). The cut surface of the excised skin nodule is black-colored grossly, because of heavy infection of pigmented fungi.



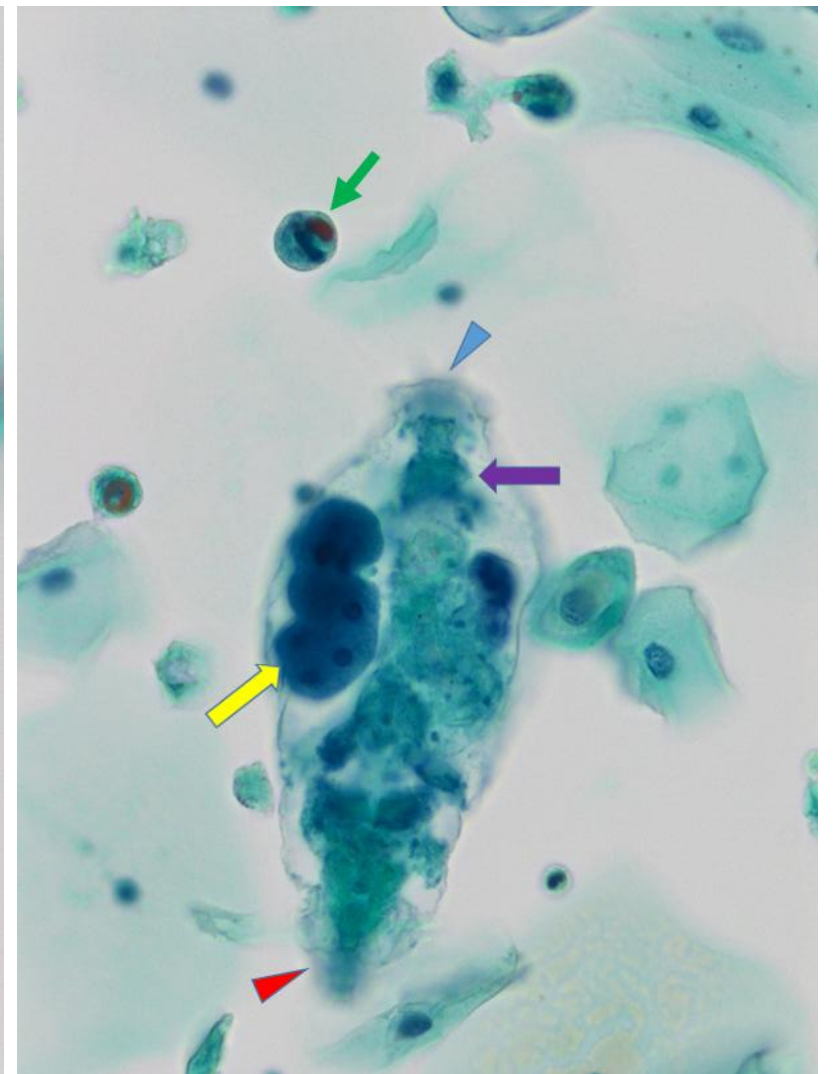
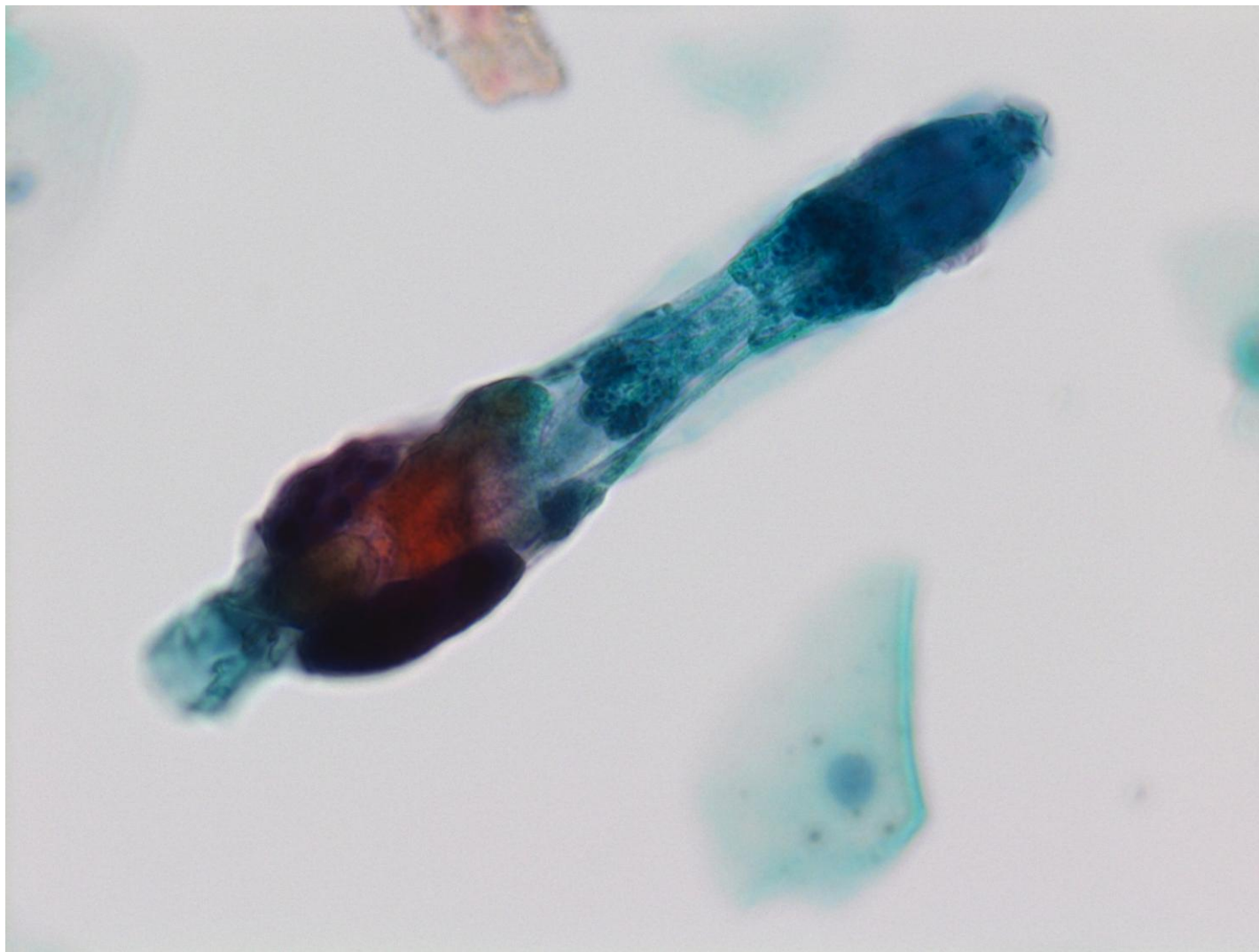No. 31: Disseminated strongyloidiasis. A disseminated larva, about 200 nm in length, seen in the sputum cytology sampled from an adult male patient with adult T-cell leukemia (ATL) after chemotherapy (Papanicolaou). Under the immunocompromised condition, larvae of *Strongyloides stercoralis* may lethally disseminate to the whole body to appear in the sputum, urine and ascites. Right panel demonstrates female adults of *S. stercoralis* heavily infected in the biopsied duodenal mucosa of another patient with ATL (H&E).



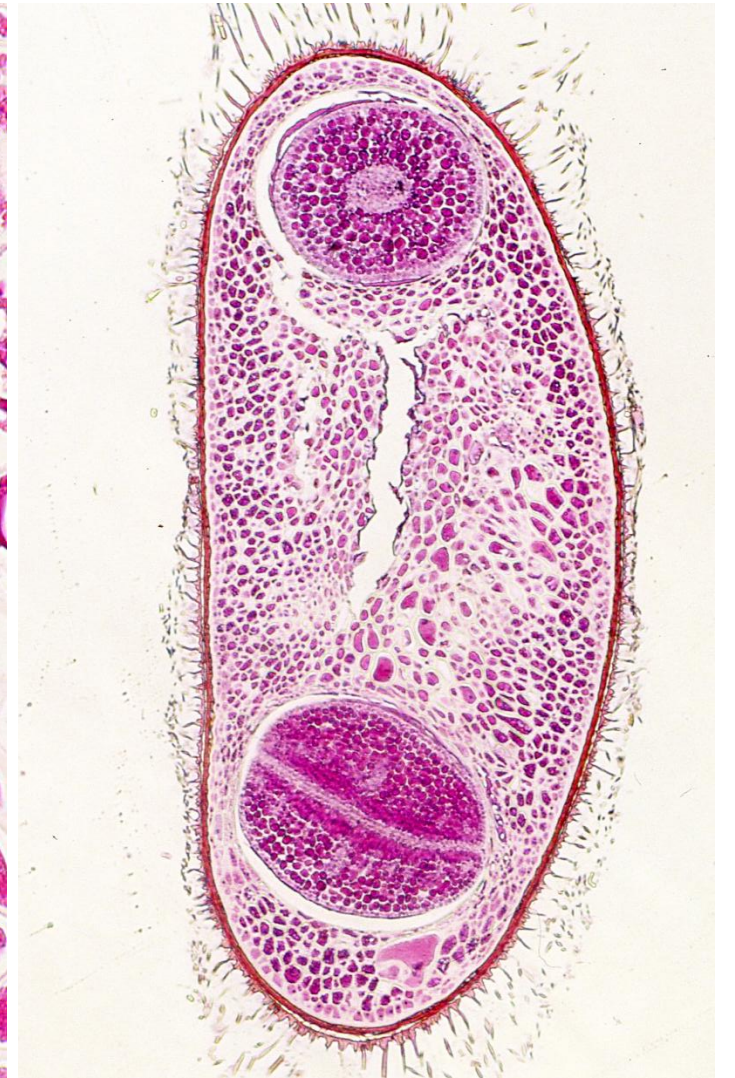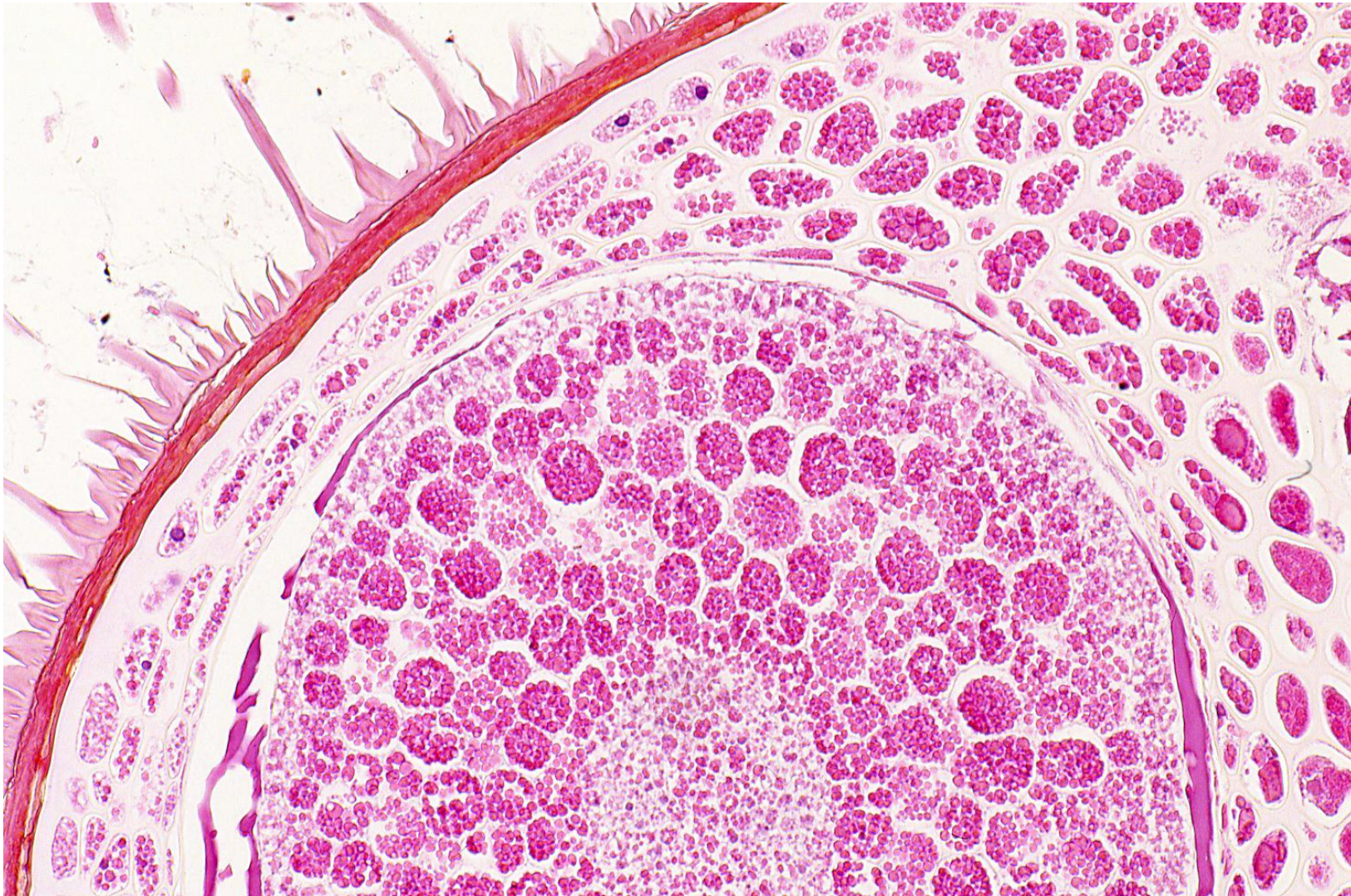
No. 32: Staphylococcal botryomycosis of the skin (Gram). Botryomycosis is a special form of chronic pyoderma mainly formed in the extremities. Botryo- means the grape. Grains may be excreted from the fistula. The white-colored grain consists of Gram-positive cocci (***Staphylococcus aureus***) and eosinophilic matrix (Splendore-Hoeppli material). Right: The grain is surrounded by neutrophilic exudation (H&E).



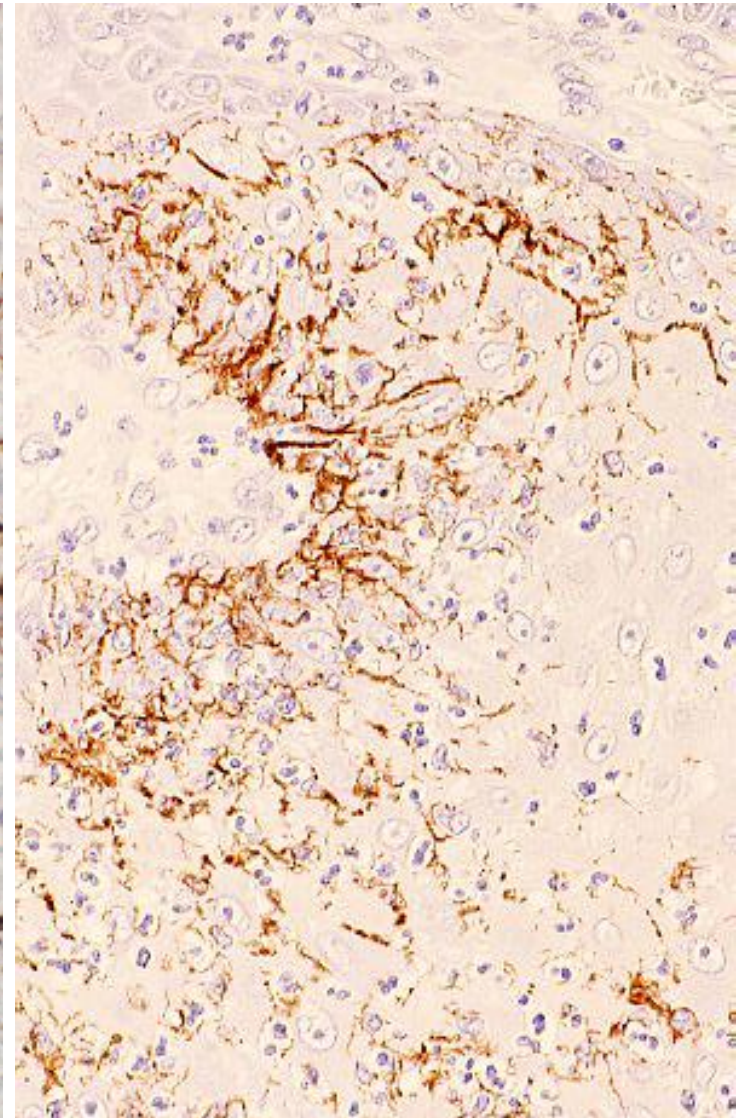
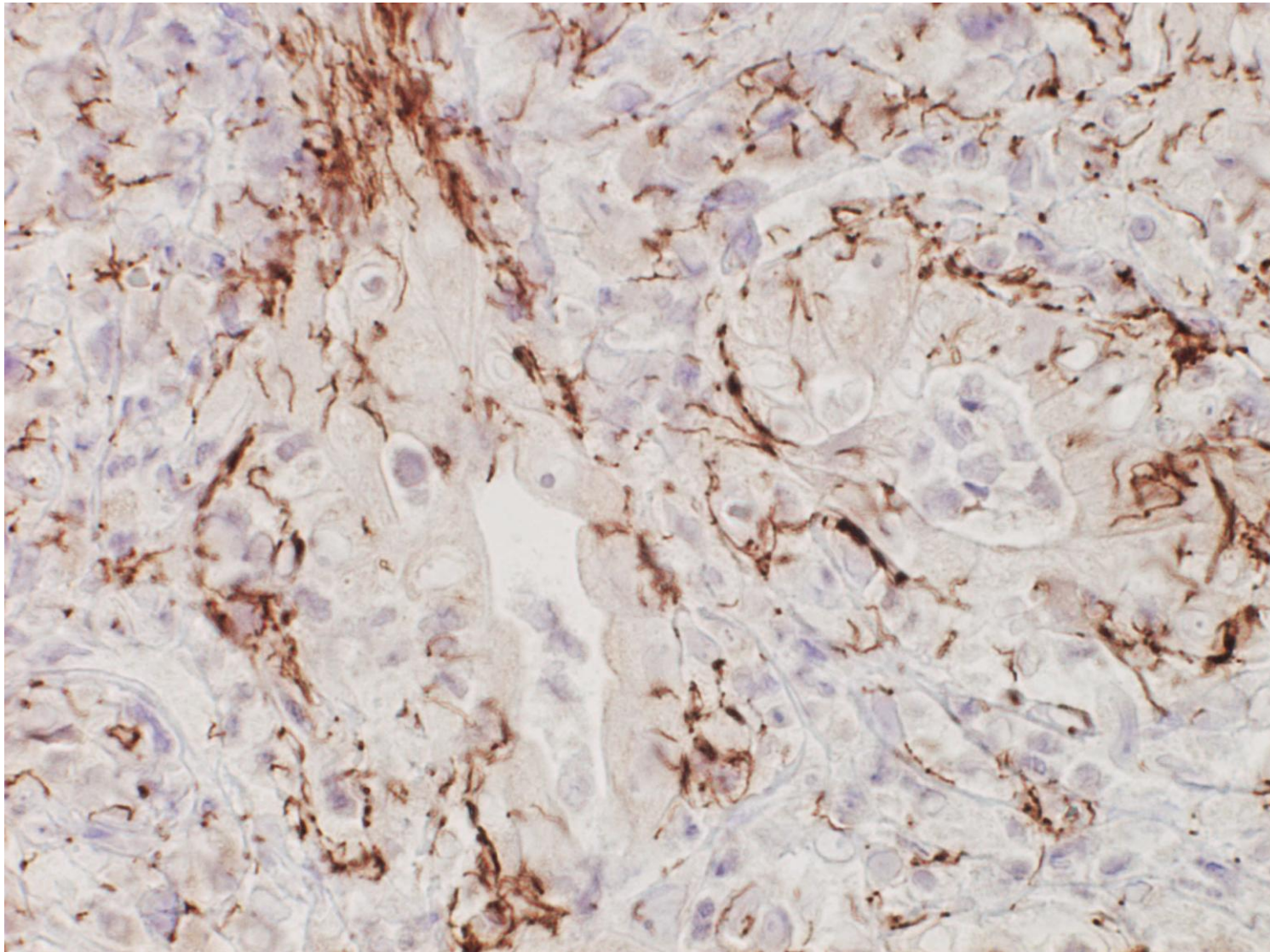
No. 33: Creeping disease by *Sparganum mansoni* infestation (H&E). *S. mansoni* is a larva (plerocercoid) of *Spirometra erinacei*, a tapeworm of the dog and cat. The first intermediate host is the cyclops, and the second intermediate hosts are snake, frog, natural hen/rooster, etc. Taking the raw meat of the second intermediate host provokes a slowly moving painless nodule in the skin. The plerocercoid is string-shaped, non-segmented and white colored worm, 5 mm to 60 cm in length. Microscopically, there are no gut and gonads, and calcareous body formation in the body matrix is common in the cestode species. Right: von Kossa stain detects calcareous bodies black.



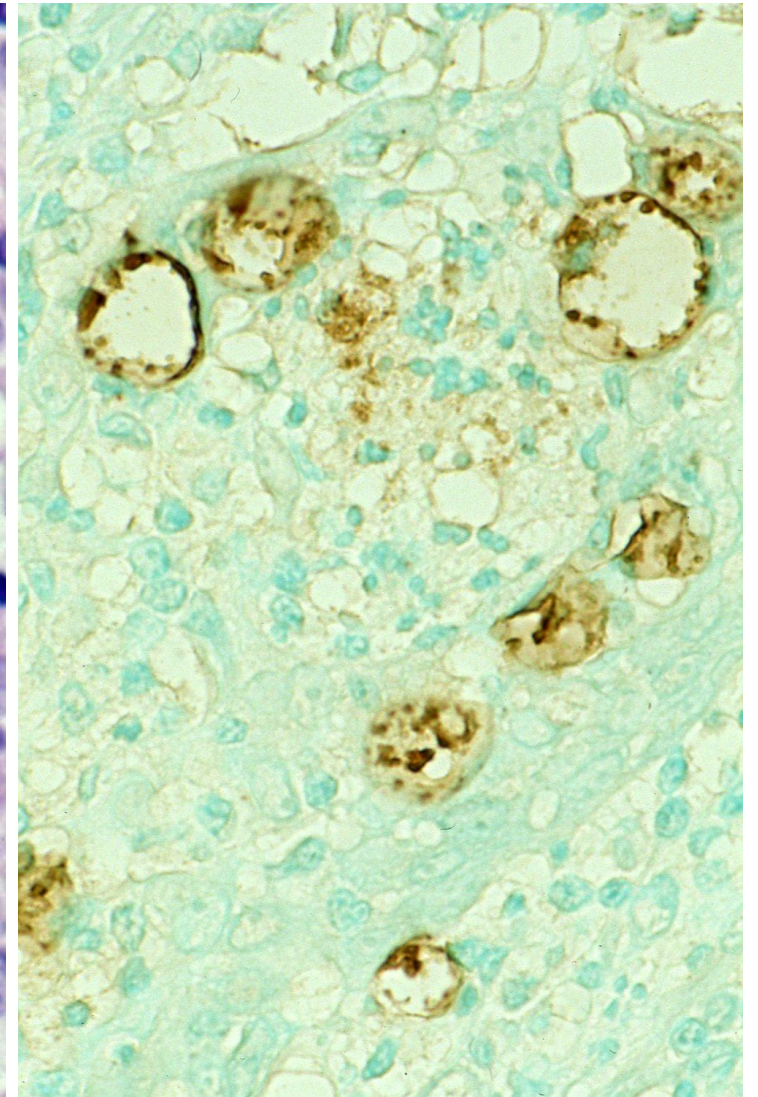
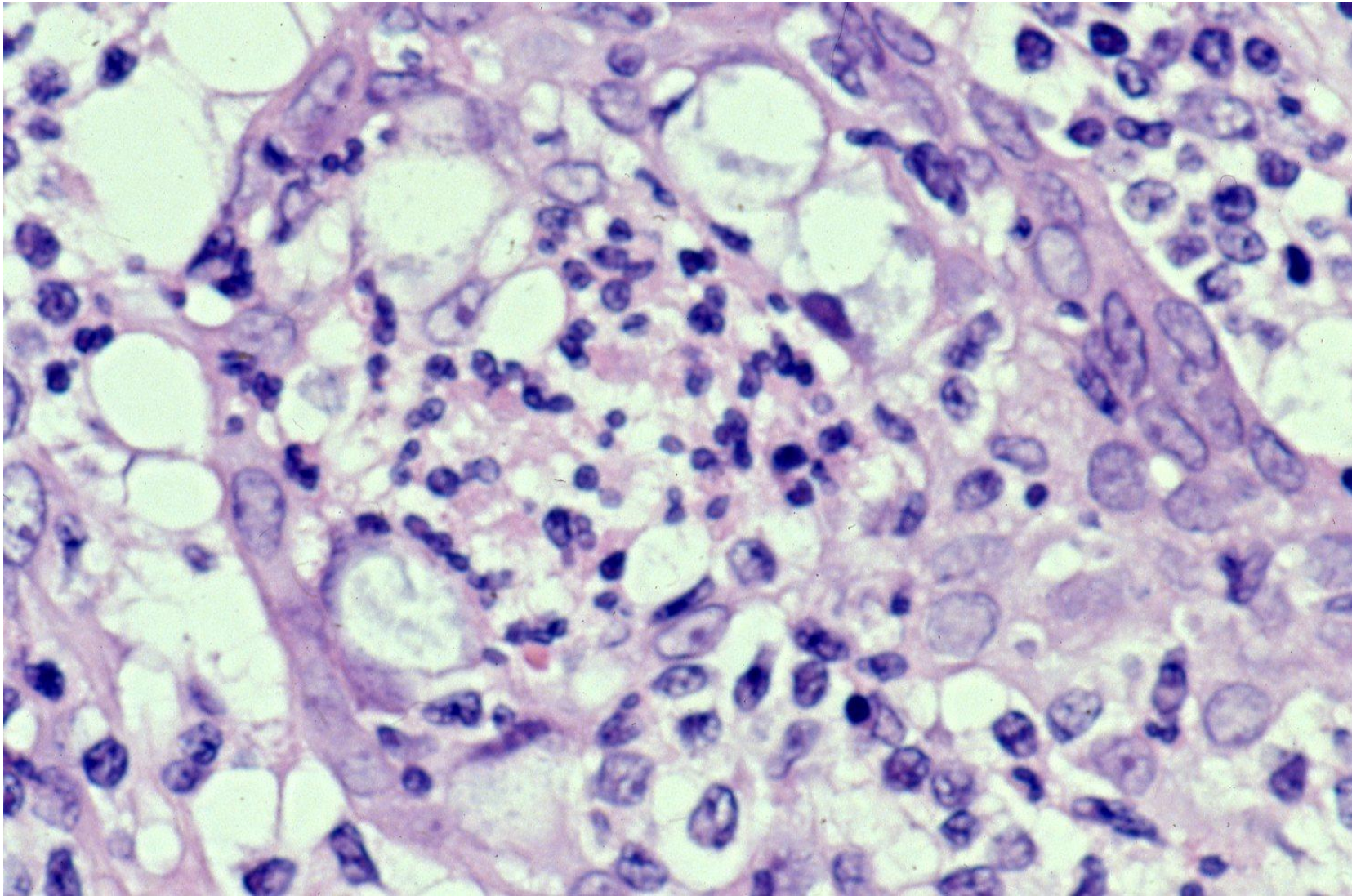
No. 34: *Bdelloid rotifer*, a type of zooplankton, incidentally found in the urine cytology (Papanicolaou). *Bdelloidea* is a class of rotifer found in freshwater habitats all over the world. It commonly grows in the flower vase and fish tank. Bdelloid rotifer has a broad head (blue arrowhead), ulceolate-shaped symmetrical trunk and elongated foot (red arrowhead), measuring 100-500 μm in length. The purple arrow indicates a mastication organ, and the ovary is shown by the yellow arrow. The green arrow demonstrates *Chlamydomonas*, a unicellular flagellated green algae and the food of the rotifer. The aged male patient must have added water of the flower vase or fish tank to his urine for laboratory examination.



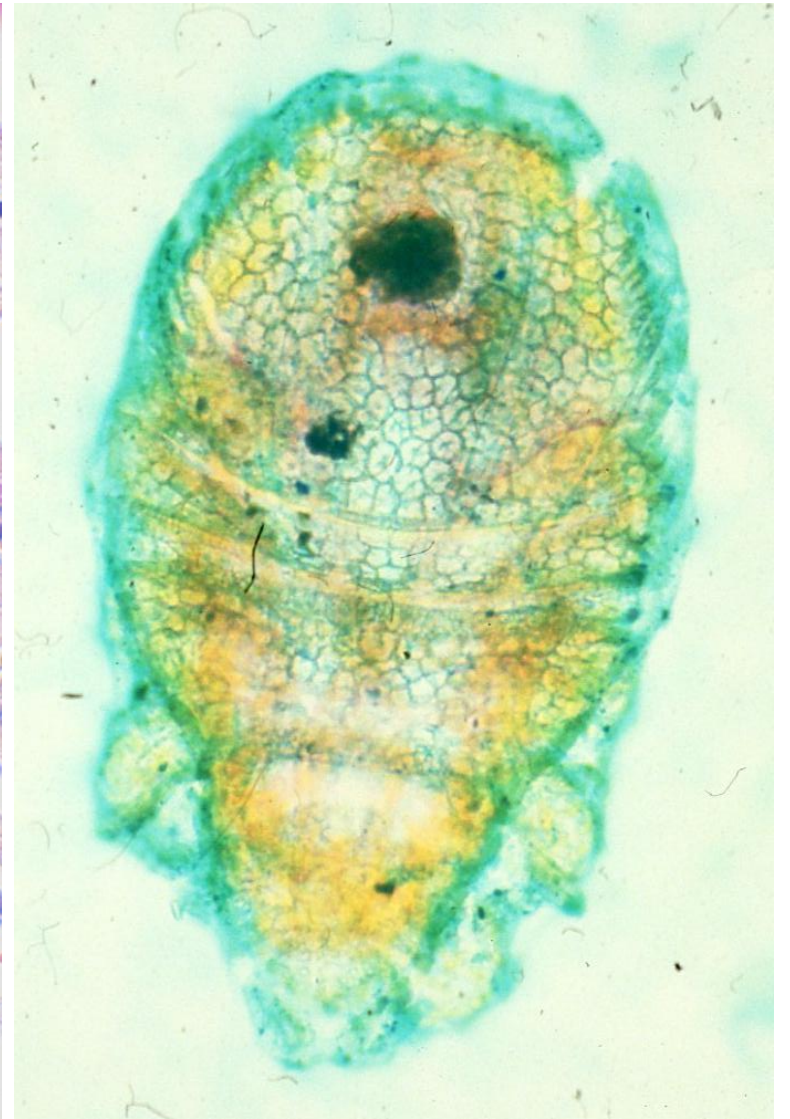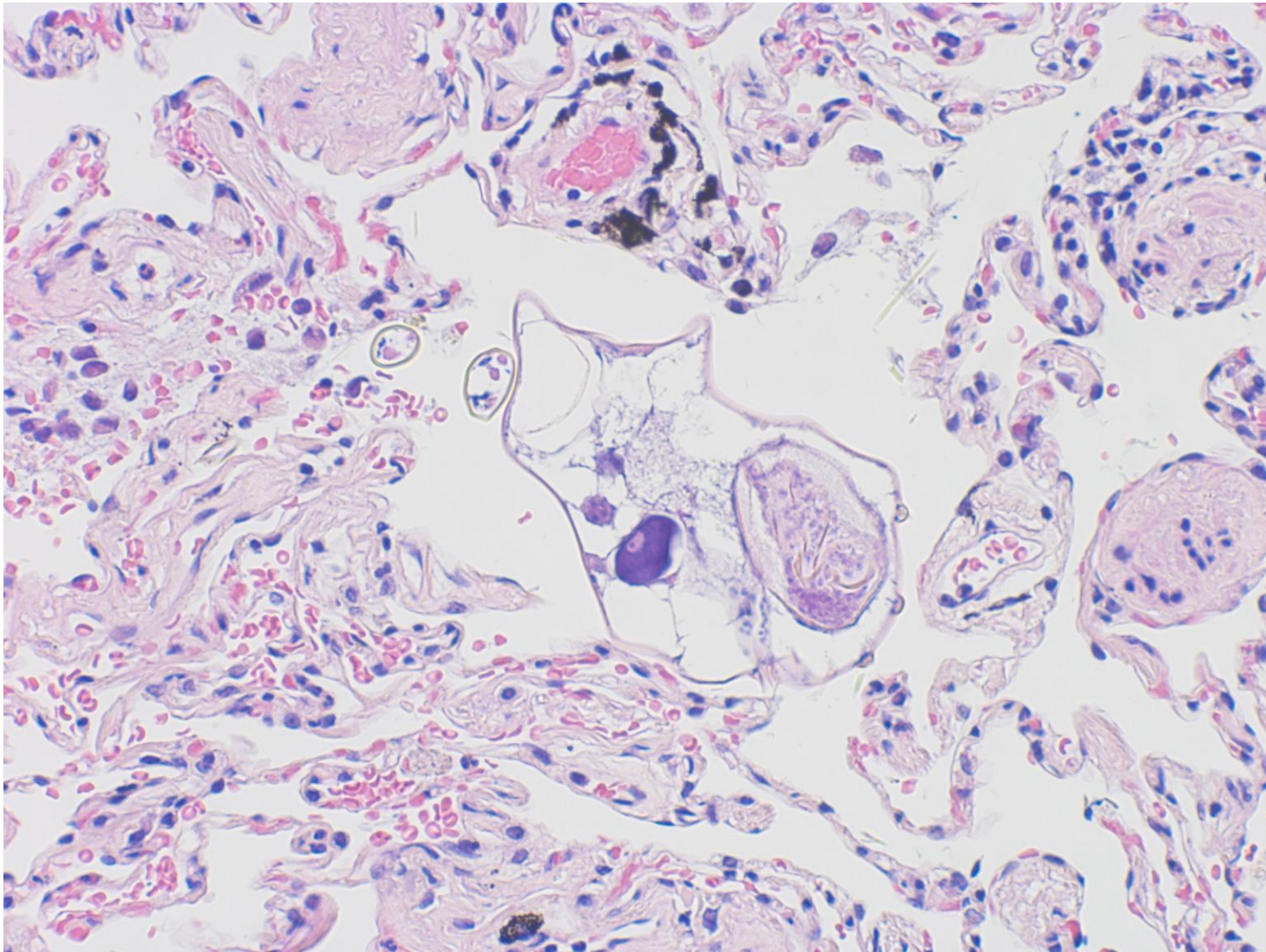
No. 35: A **fruit seed** attached to the colonic mucosa endoscopically sampled as a colonic polyp. A whole 3 mm-long seed is shown in the right panel (H&E). Two round-shaped and segmented germs (embryos) are embedded in the endosperm, storing reserve food. Each vegetable cell contains numerous eosinophilic coarse granules, representing chlorophylls. The seed is covered with hairy projections on the brown-colored seed coat. The hairy projections may assist at anchoring the seed on the colonic mucosa. Unheated fruit seed can resist against digestive enzymes in the gut lumen.



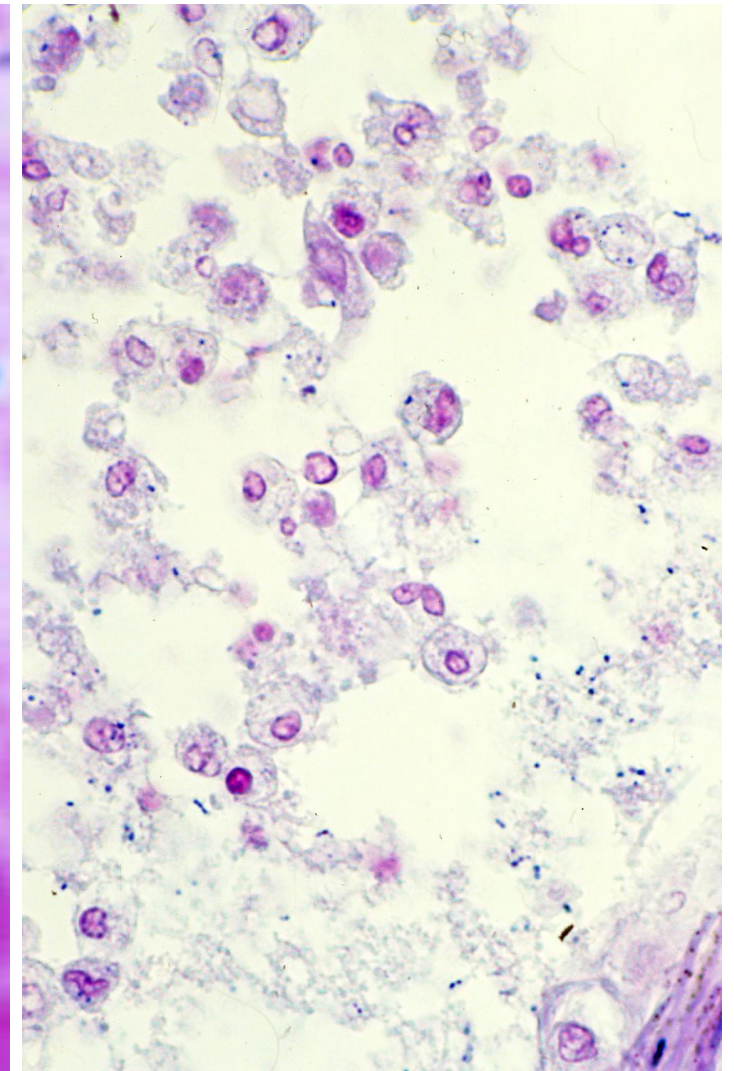
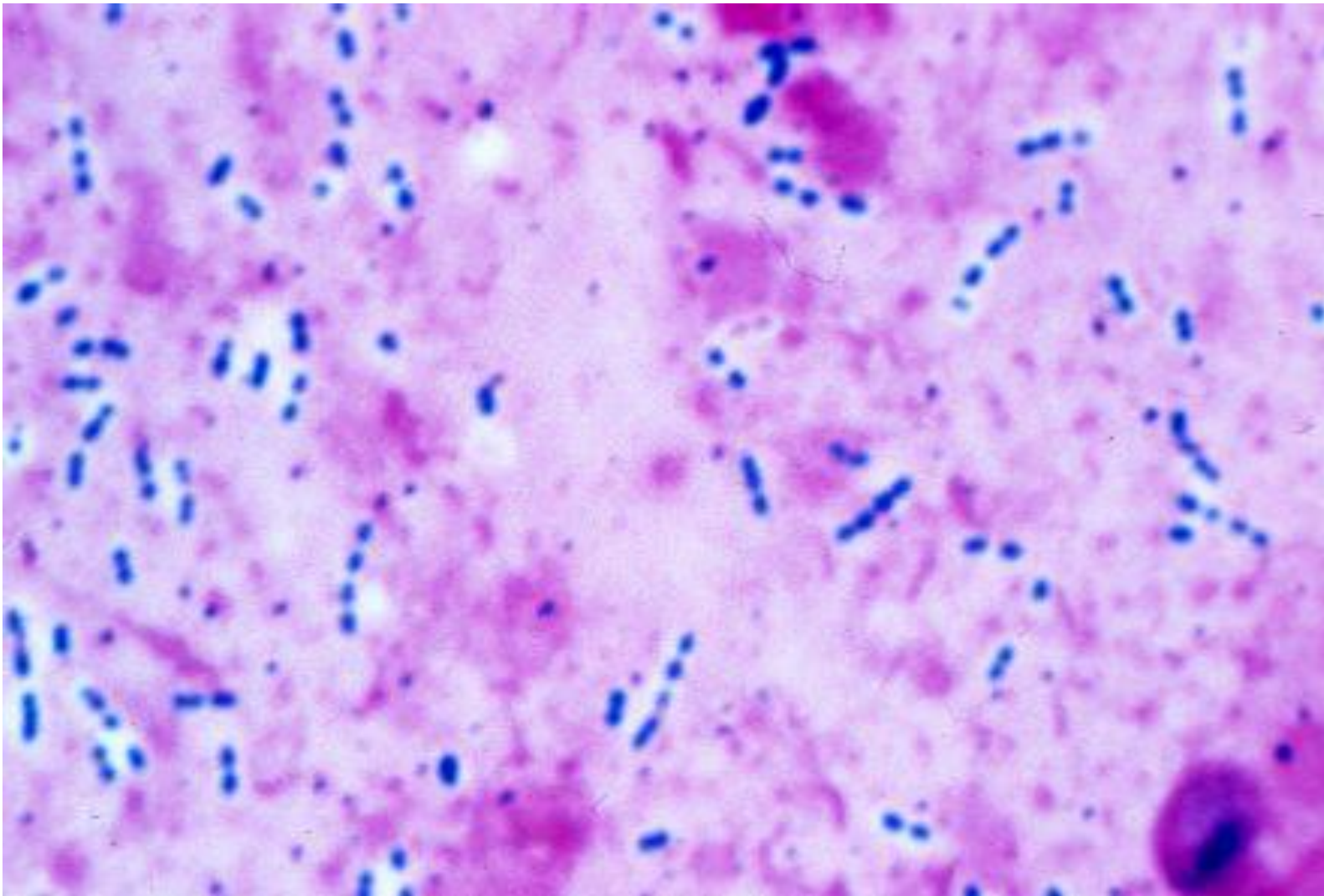
No. 36: Gastric syphilis (immunostaining for *Treponema pallidum* antigens). The gastric mucosa is often involved in the second stage of illness. Numerous brown-stained long spiral bacteria are seen among the columnar epithelial cells and around capillary vessels. Right: a tongue lesion in the second stage syphilis. The immunostained pathogens are clustered among the squamous epithelial cells.



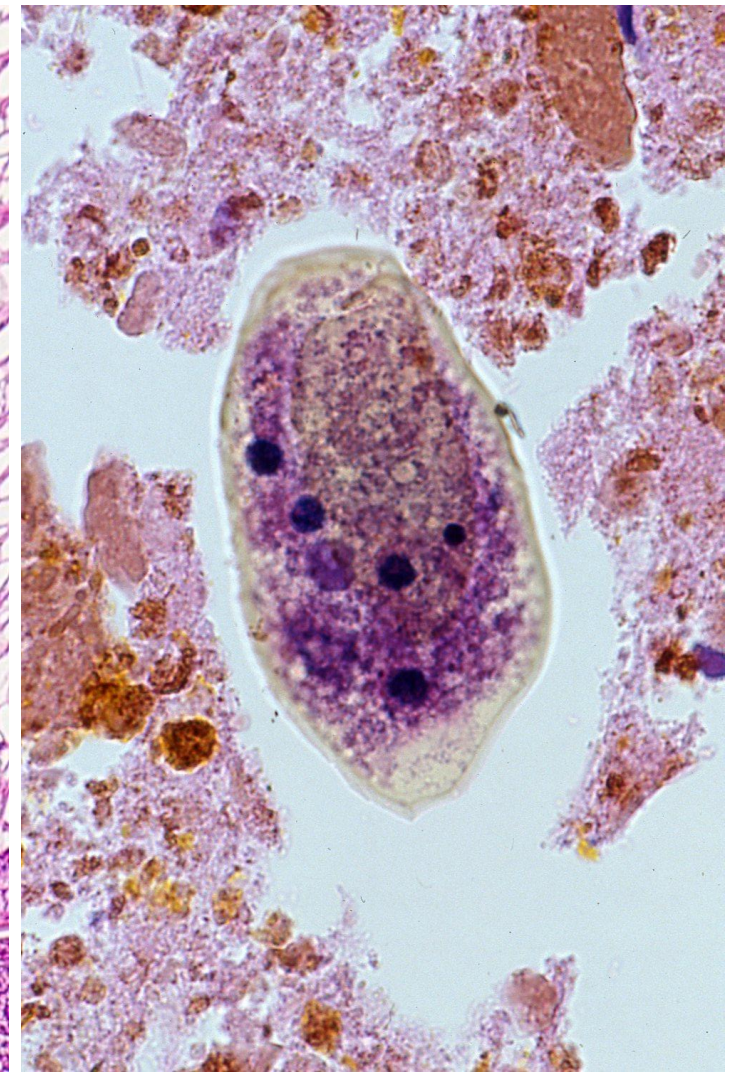
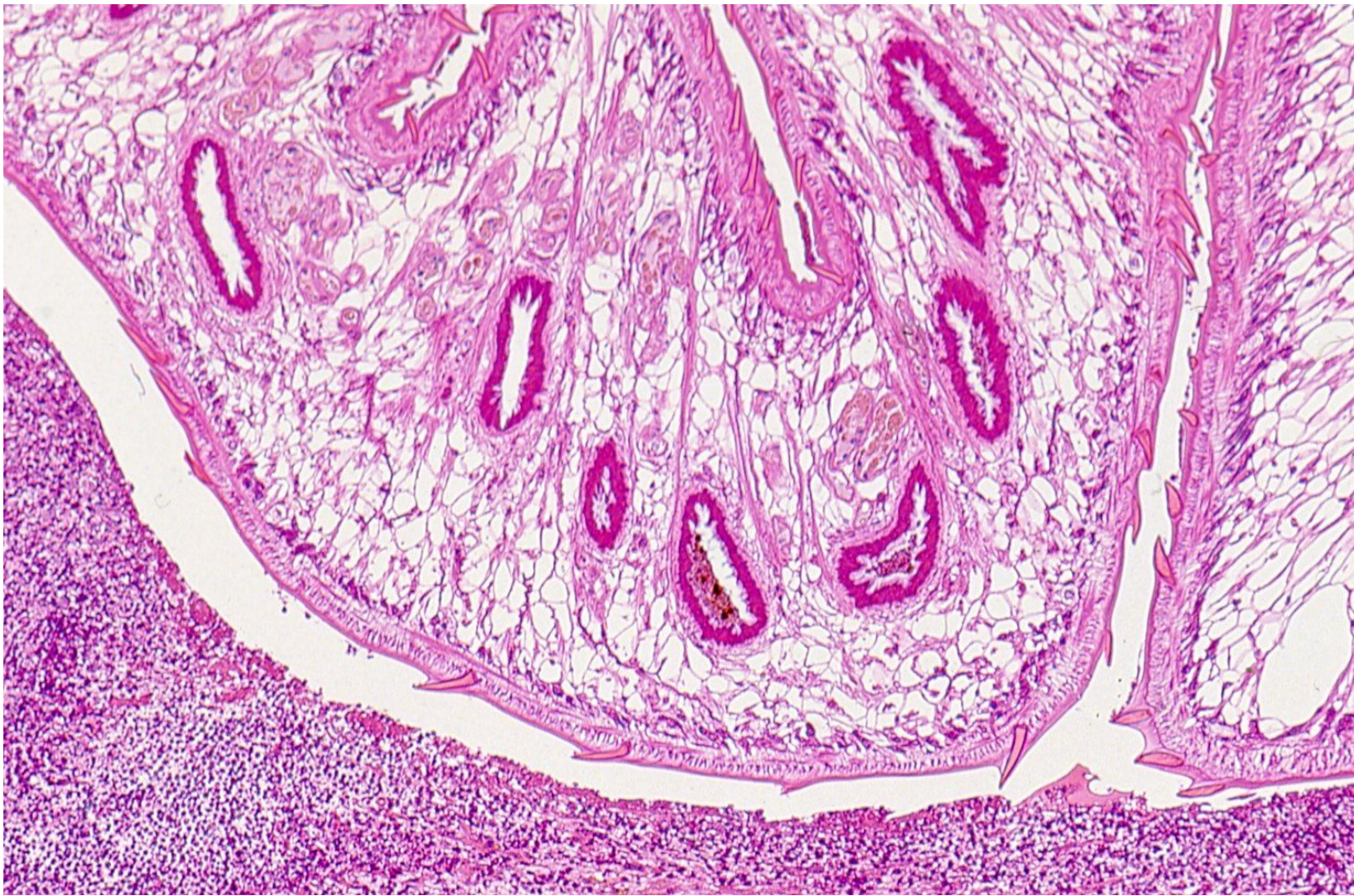
No. 37: Chlamydial epididymitis (H&E). *Chlamydia trachomatis* causes chronic epididymitis, forming a non-tender intrascrotal tumor. The ductal epithelial cells are infiltrated by neutrophils, and show large intracytoplasmic vacuolar inclusions. Right: Immunostaining for *C. trachomatis* antigen discloses positive brown-colored signals in the intracytoplasmic inclusion bodies.



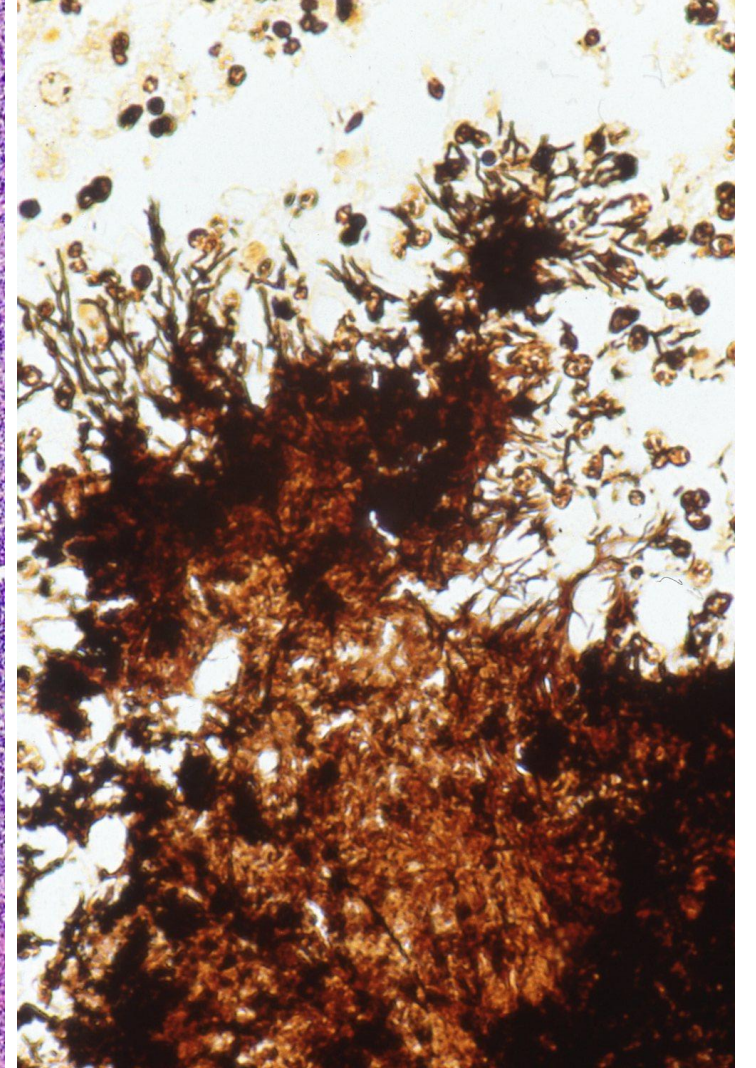
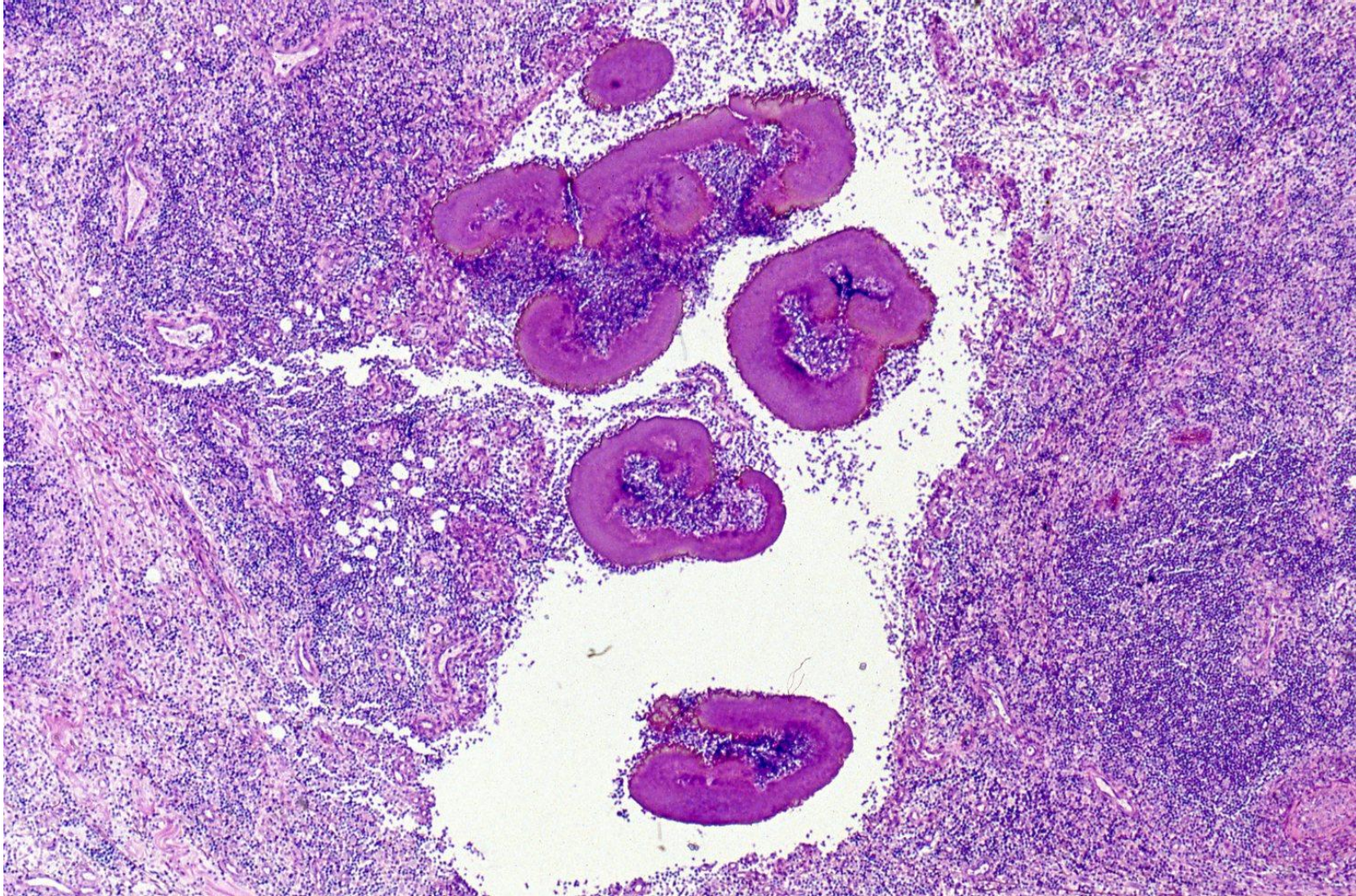
No. 38: Mite contamination in the lung (H&E). The surgically resected lung contains 200-400 μm -sized mites with short legs in the alveolar space just beneath the pleura. This is an artificial contamination of house dust mites (*Dermatophagoides* spp.) by putting the resected lung onto the contaminated towel or floor. Right: Artificial contamination of the mite with pairs of short legs onto the cervical smear preparation (Papanicolaou).



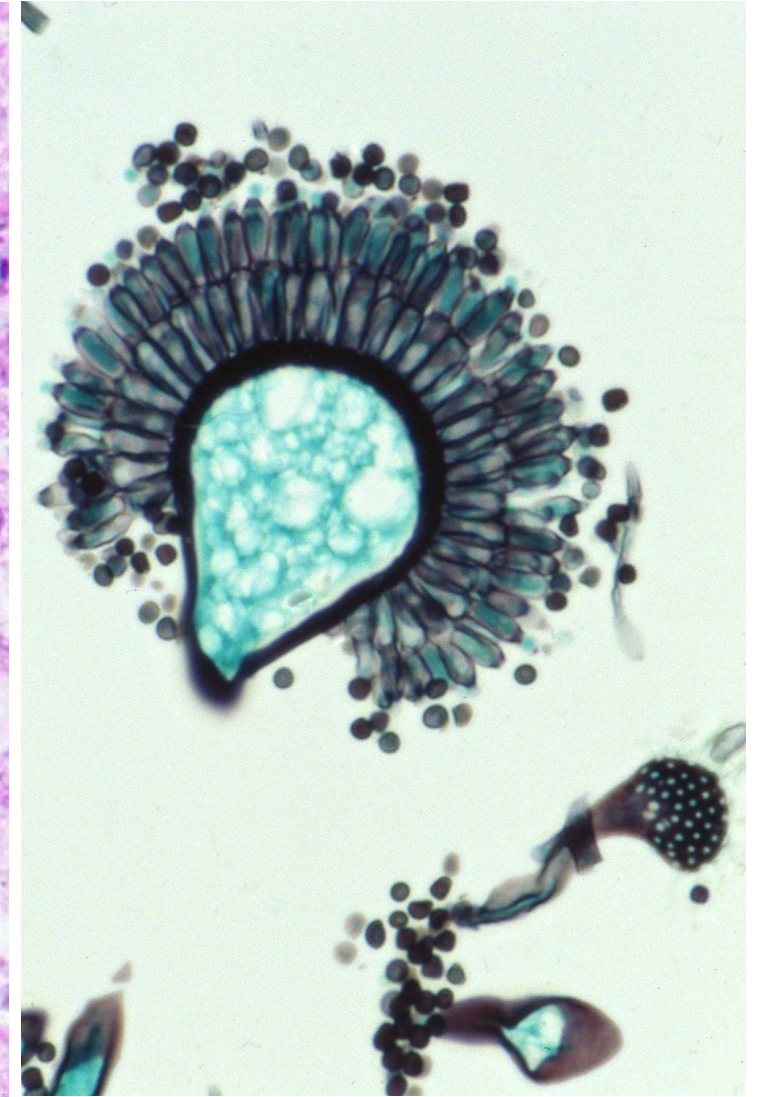
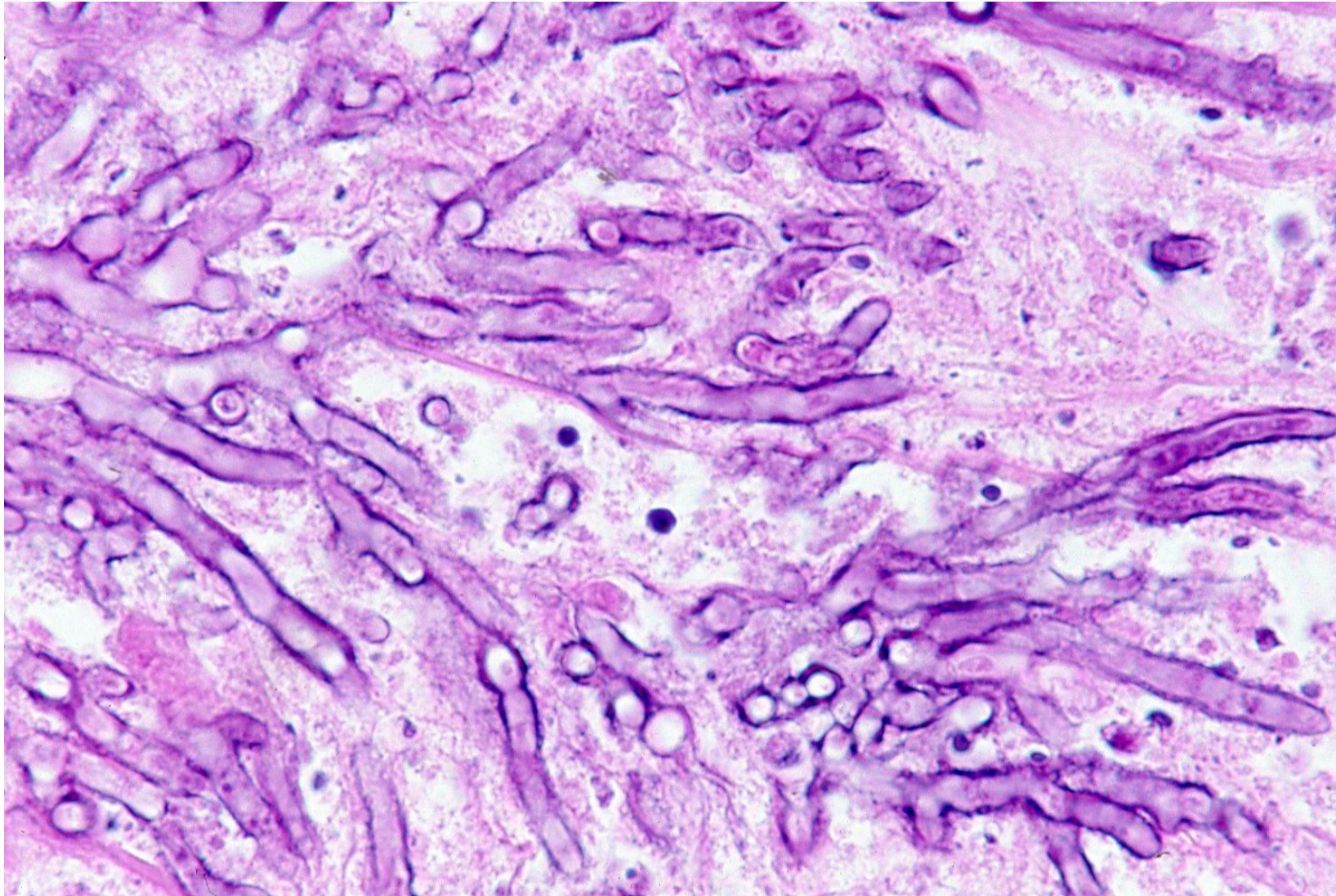
No. 39: Pneumococcal lobar pneumonia (sputum smear, Gram stain). *Streptococcus pneumoniae* is a Gram-positive coccus with formation of chains or pairs. The presence of the capsule around the cell body (recognized as a translucent zone) is characteristic, escaping phagocytosis by neutrophils. Right: the autopsied lung showing intra-alveolar neutrophilic infiltration and scattered Gram-positive diplococci, not phagocytized by neutrophils (Gram).



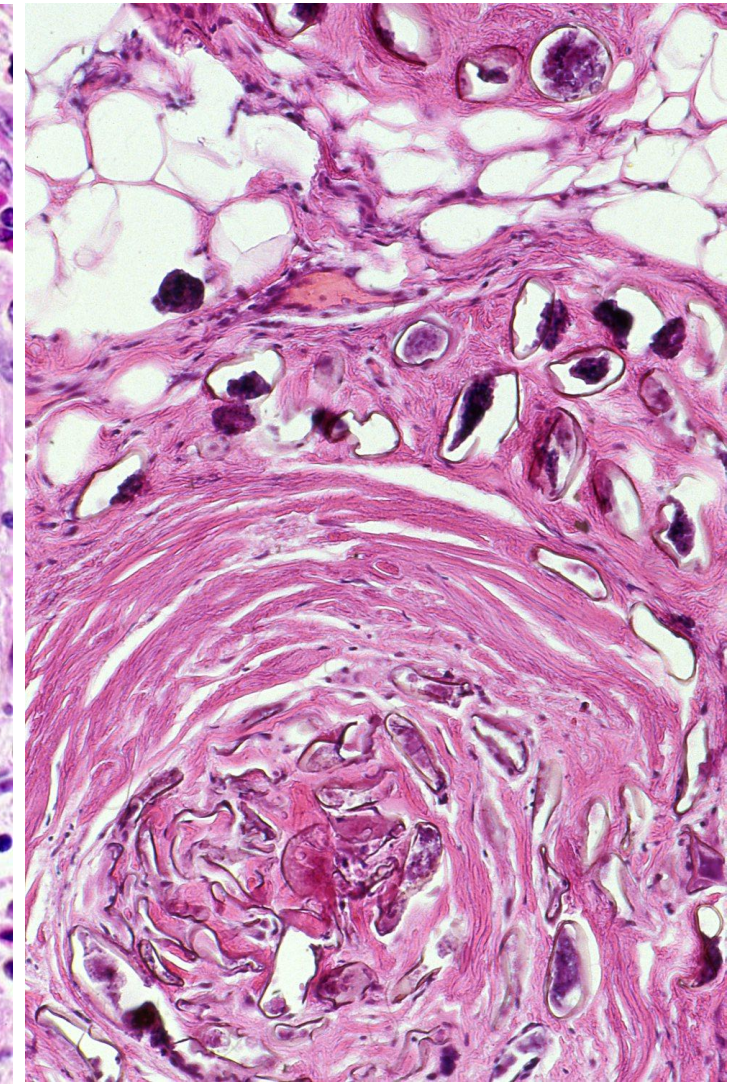
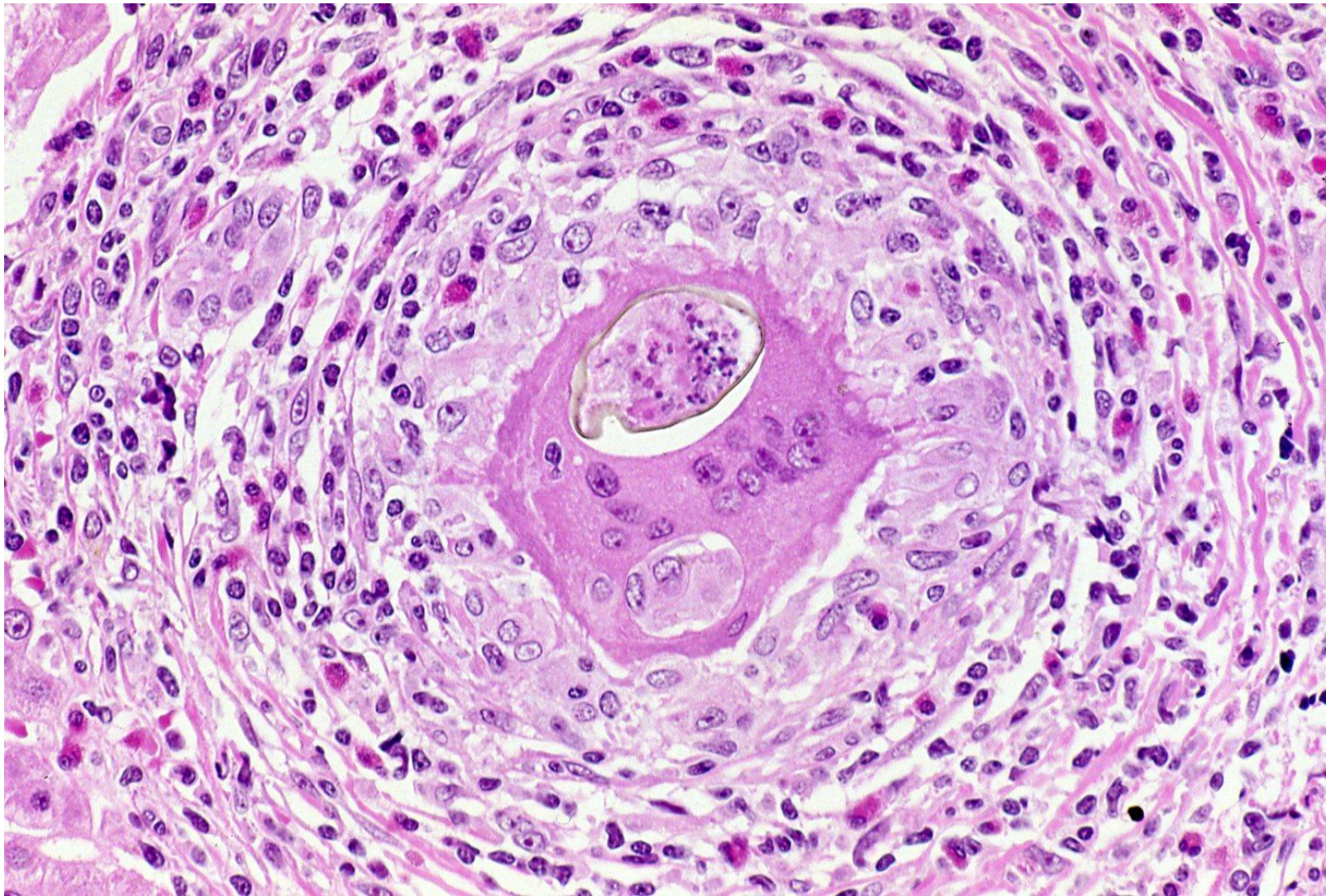
No. 40: *Fasciola hepatica* infestation in the liver (H&E). The surgical specimen contains an immature adult fluke. Infestation of *F. hepatica* is common among the cow, goat and sheep. Infective metacercariae (larvae) are attached to the leaves of water plants. The ingested larva penetrates the duodenal wall to reach the peritoneum, and the maturing fluke then invades the liver capsule. Eventually, the adult fluke stays in the bile duct. The spiked cuticle, subcuticular muscle cells and the gut but without gonads are observed. Eosinophilic reaction is associated around the fluke. Right: A large-sized (130 μm -sized) ovum of *F. hepatica* contains yolk cells (bile cytology, May-Giemsa).



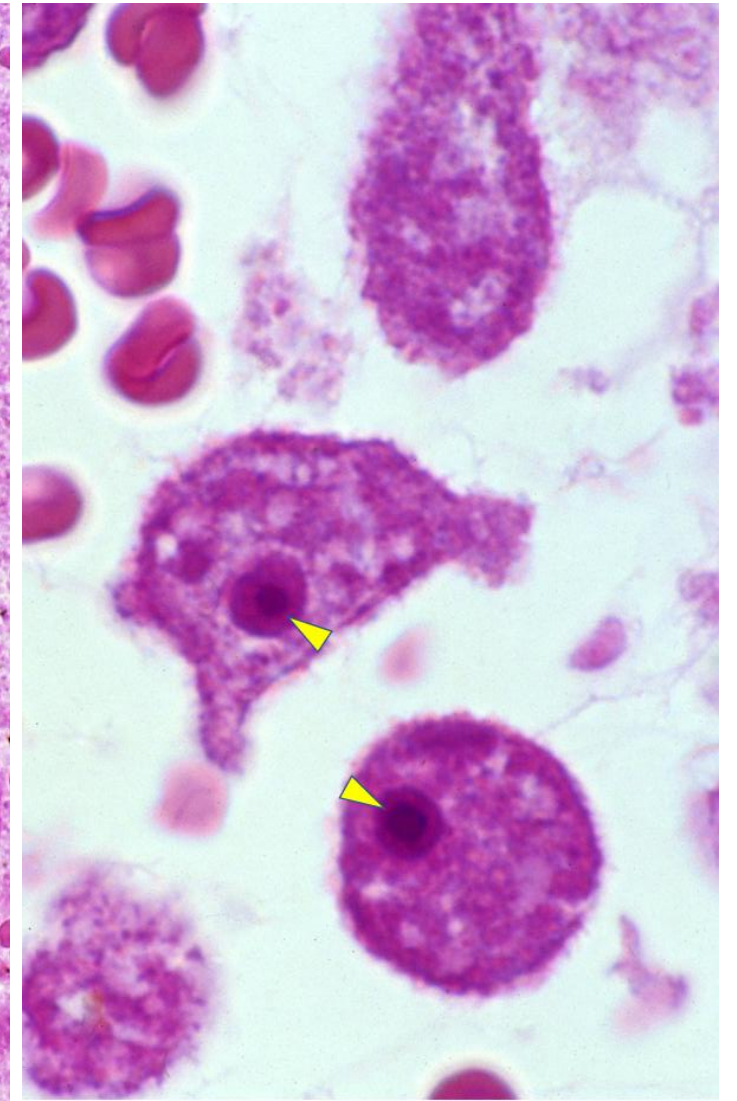
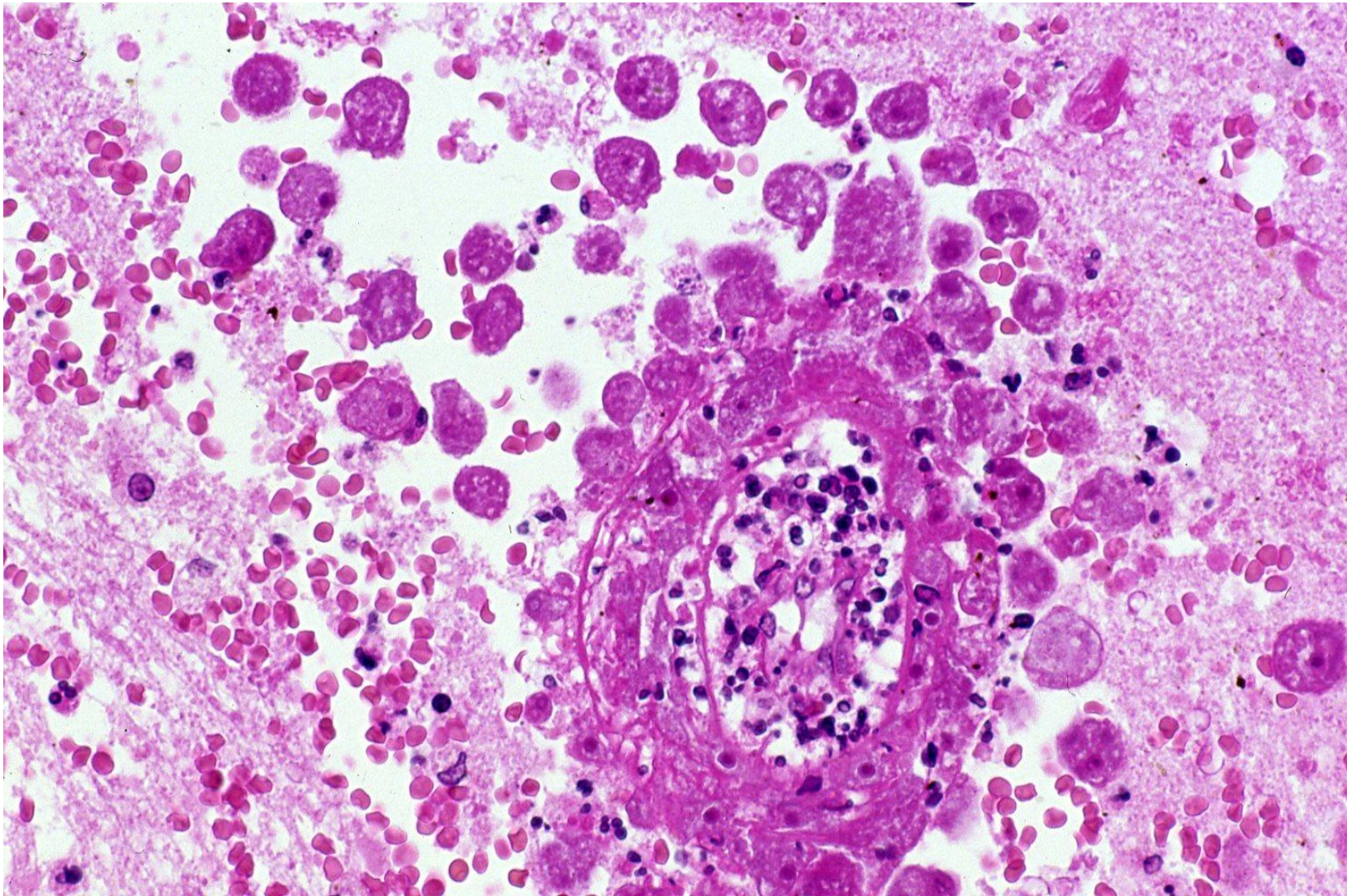
No. 41: Pulmonary actinomycosis (H&E). Actinomycotic grains (yellowish-colored sulfur granules) are clustered in the eroded and actively inflamed bronchial lumen (H&E). They are positively stained with Gram and PAS stains. Right: The sulfur grain consists of argyrophilic long filamentous and branching bacteria (Warthin-Starry's silver).



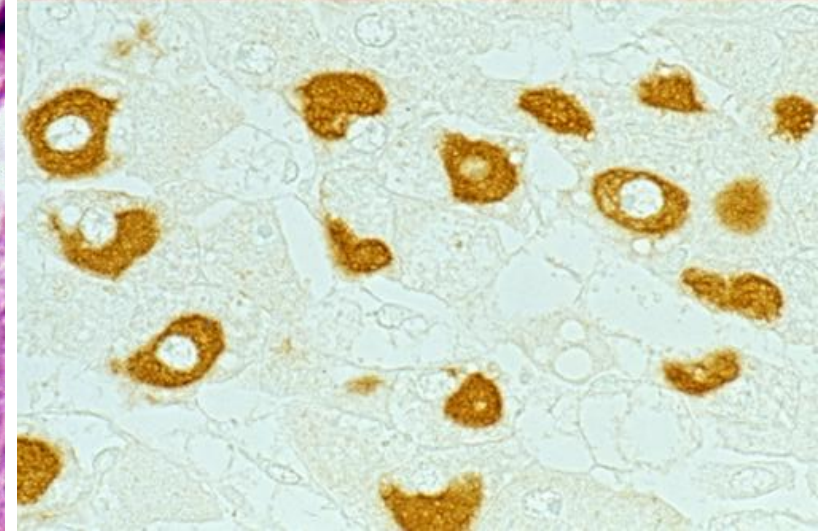
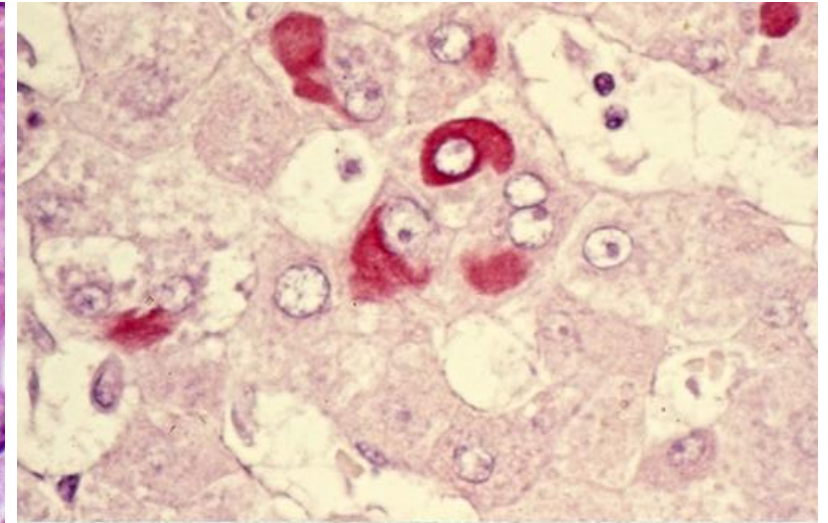
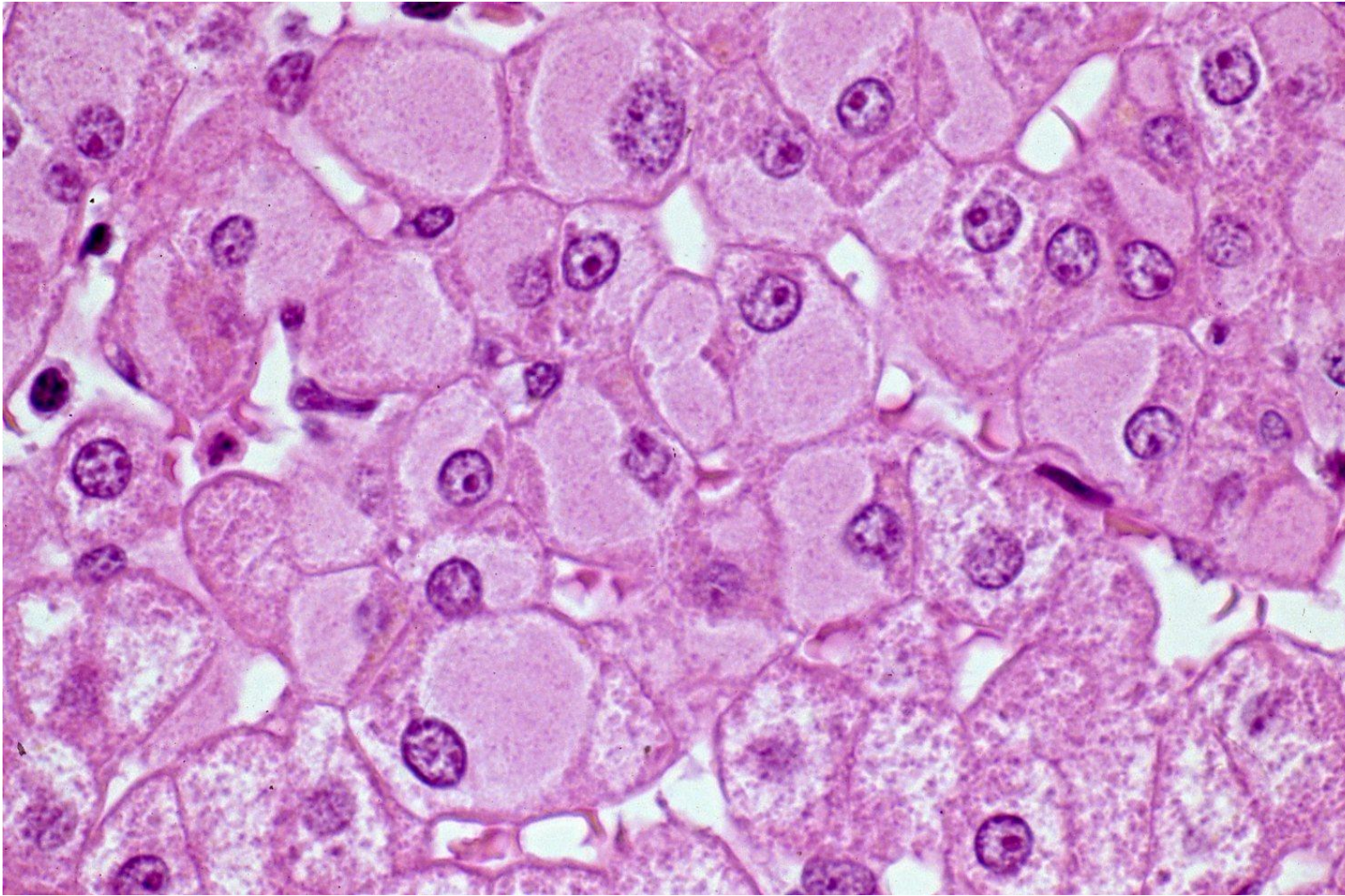
No. 42: Aspergillosis of the lung (H&E). Y-shaped branching, basophilic hyphae actively grow in the lung. Septum formation is observed in the mycelium. Right: Conidial heads (fruiting bodies) seen in cultured *Aspergillus flavus*. Spore formation is associated on the conidial head (Grocott).



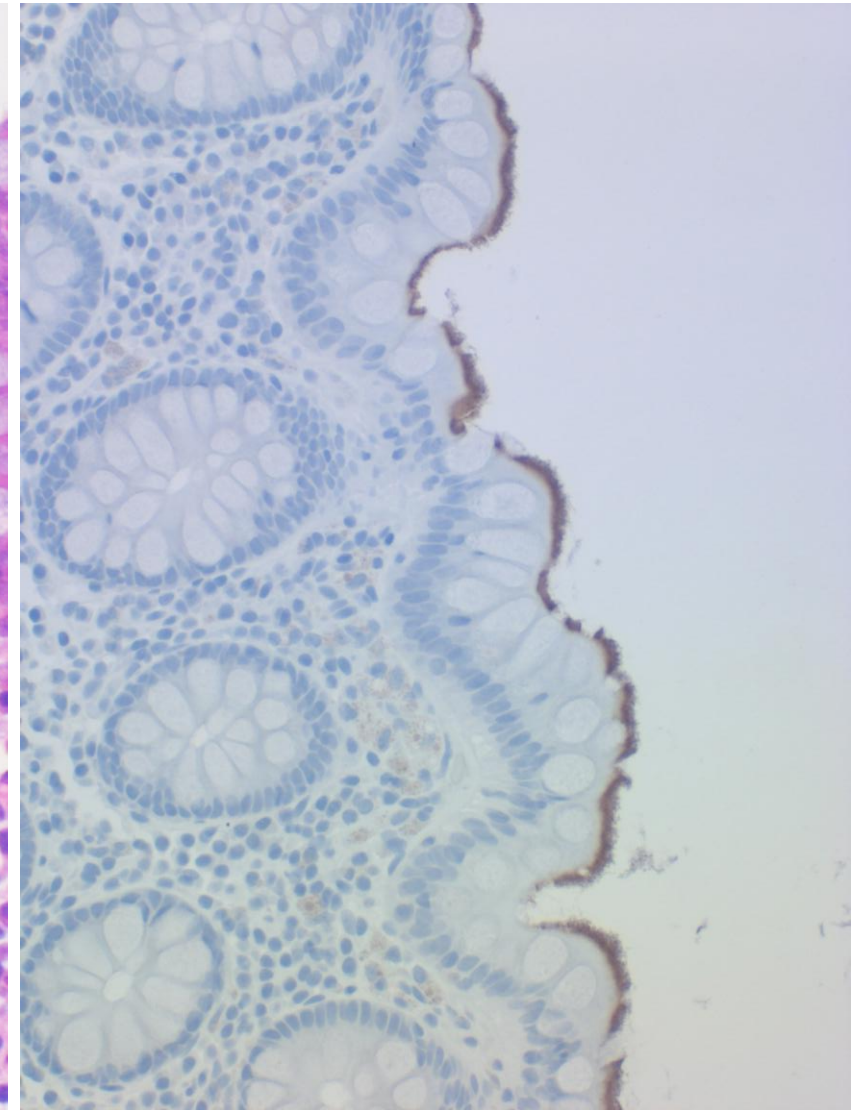
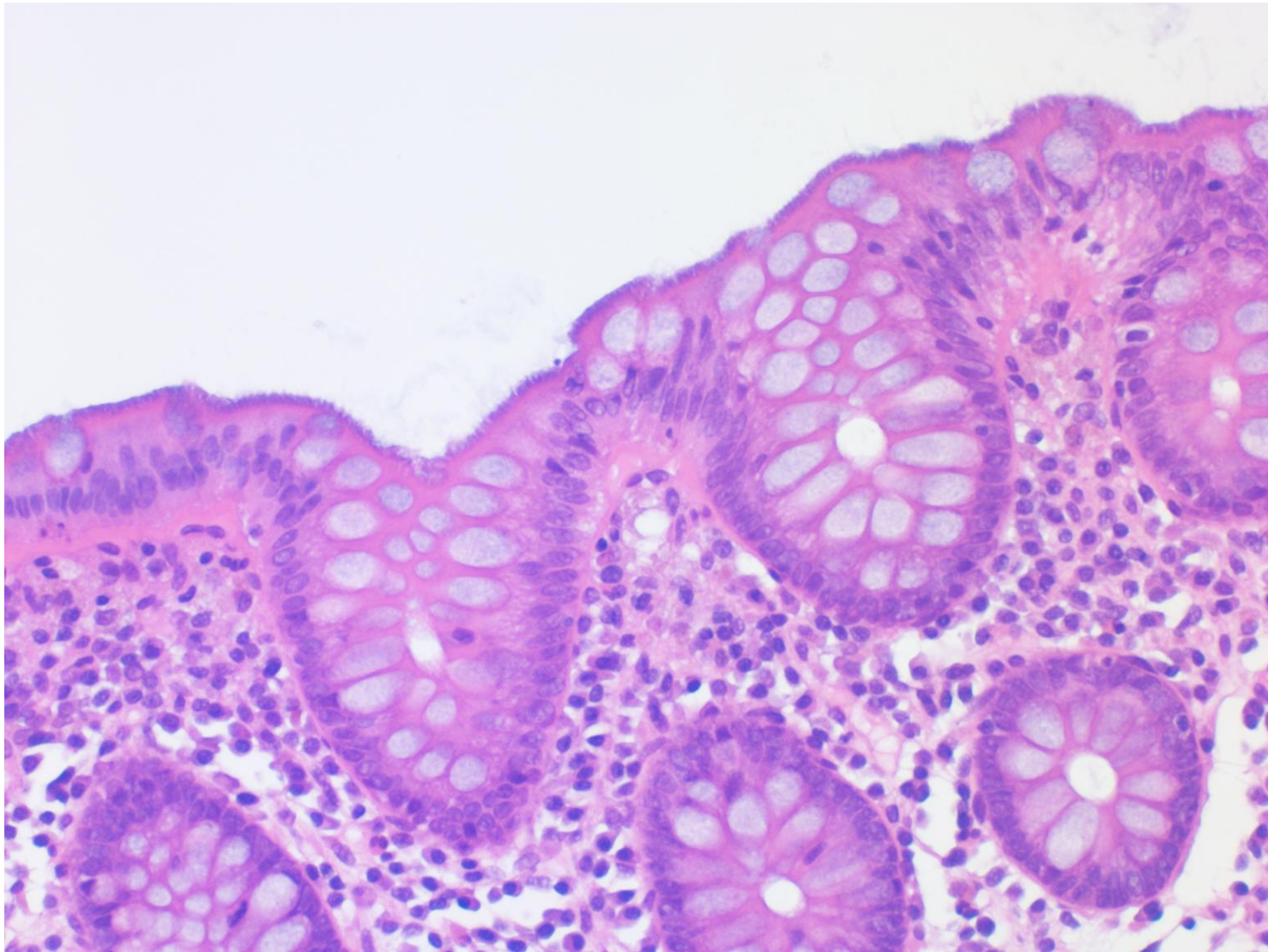
No. 43: Liver **egg tubercle** of *Schistosoma japonicum* (H&E). In the liver biopsy specimen taken from a Laotian boy, an egg tubercle is formed in the portal triad. A viable egg with miracidium formation is phagocytized by a multinucleated giant cell, and epithelioid granulomatous reaction is associated. Right: Clustered calcified (dead) ova of *S. japonicum* seen in the surgical specimen of acute appendicitis (H&E). In Japan, new cases of schistosomiasis are no longer seen.



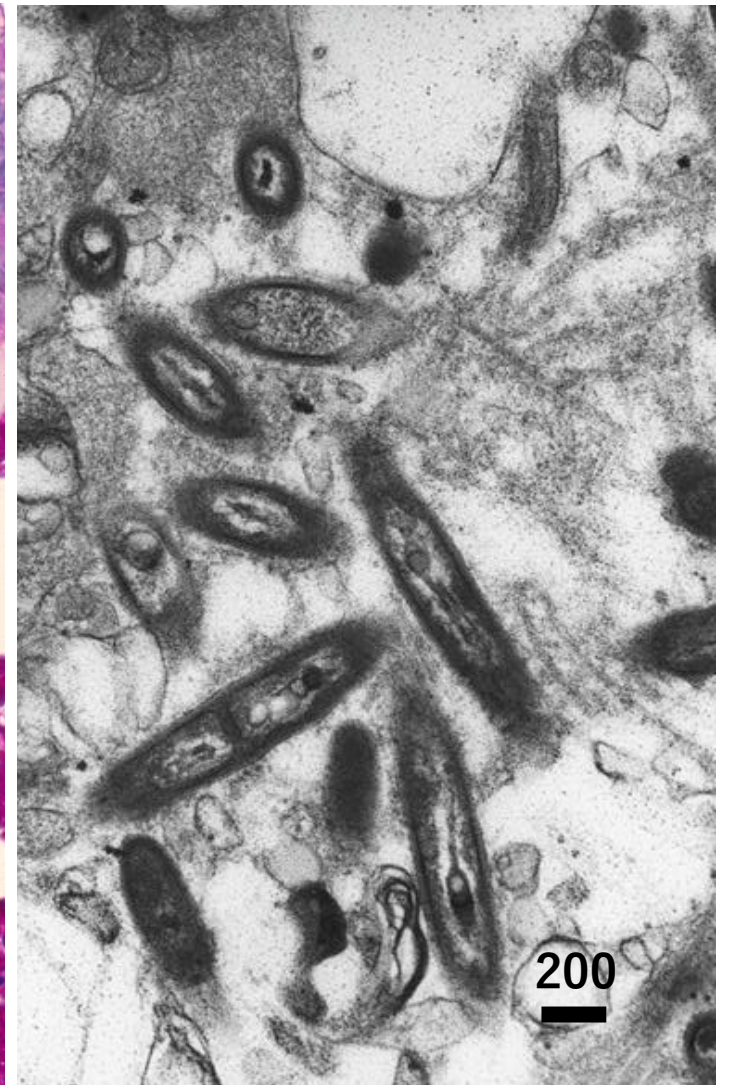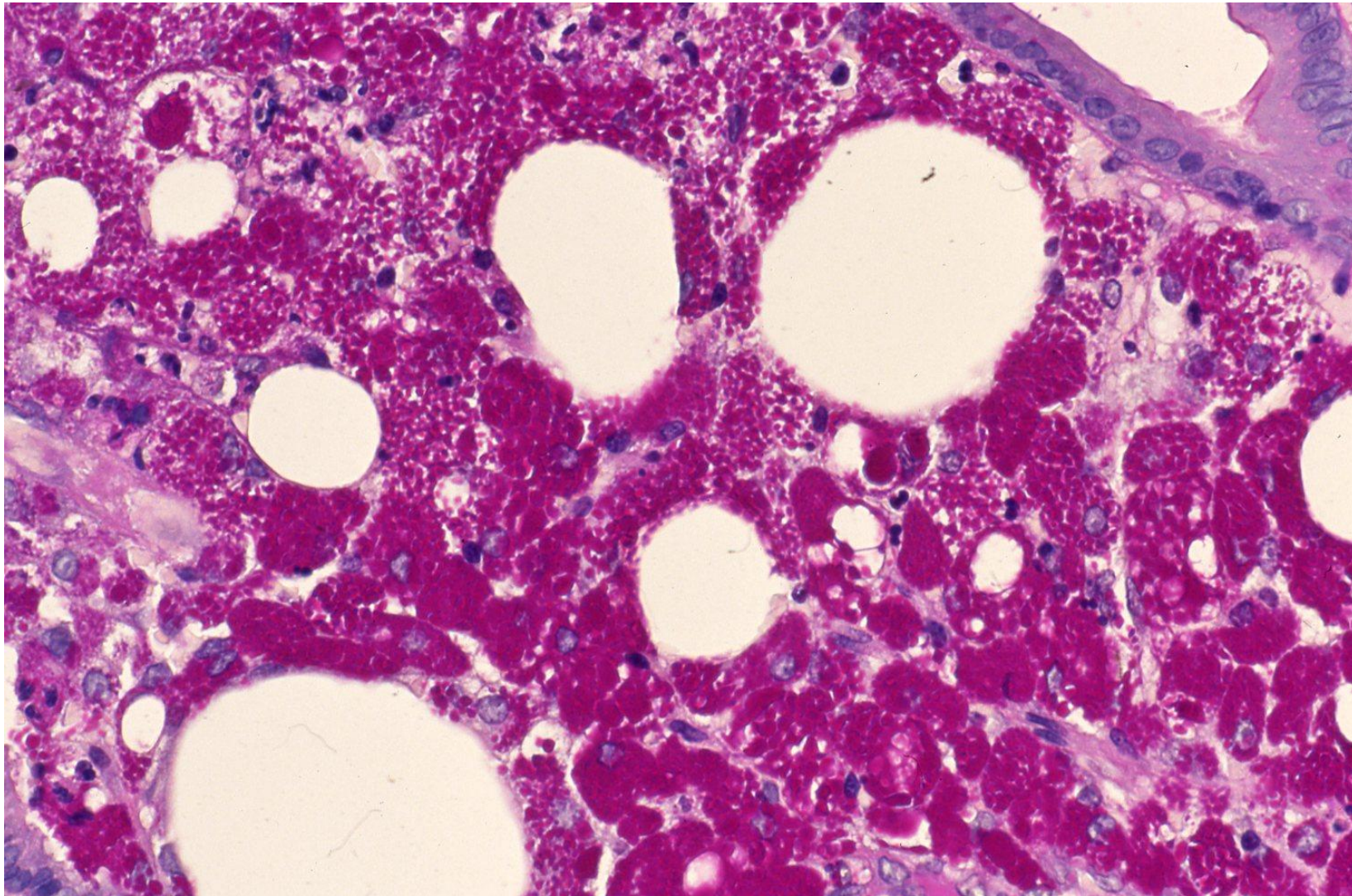
No. 44: Primary amebic meningoencephalitis caused by *Naegleria fowleri* infection (H&E). *N. fowleri* is a free-living amoeba commonly seen in water in the tropical and subtropical areas. Diving into the lake or water pool allows the lethal pathogen to invade from the nasal cavity to the meningeal space. Amebic trophozoites are clustered around small vessels in the Virchow-Robin space. Right: High-powered view demonstrates a distinct karyosome in the center of the nucleus (arrowheads), a common feature of protozoan cells.



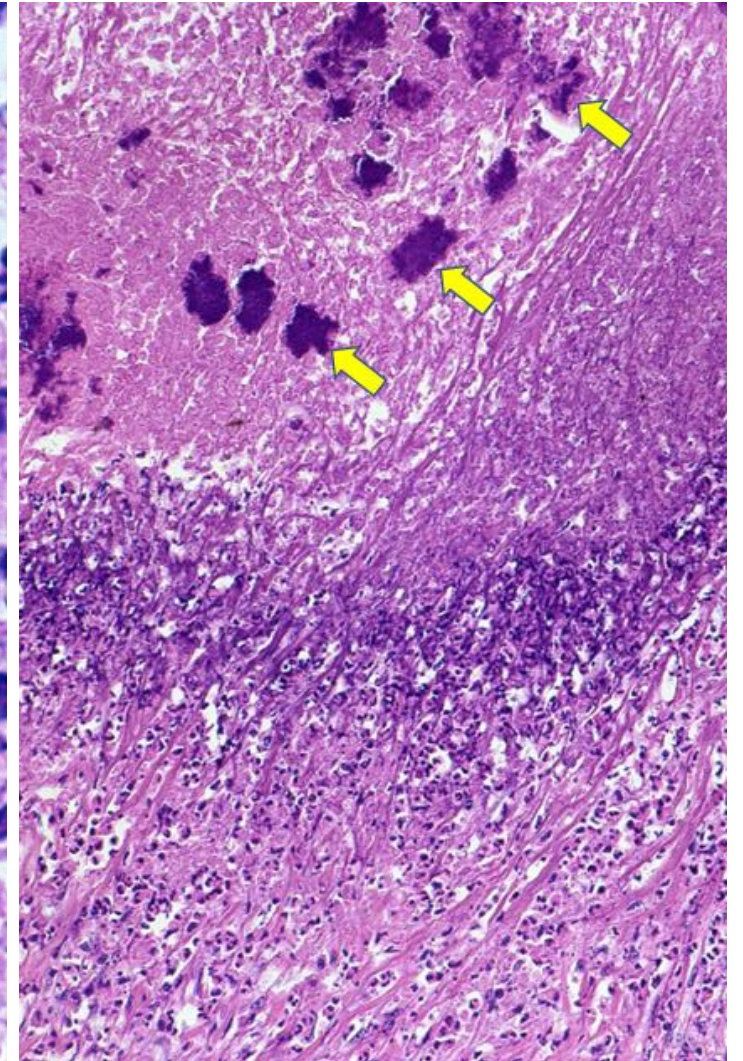
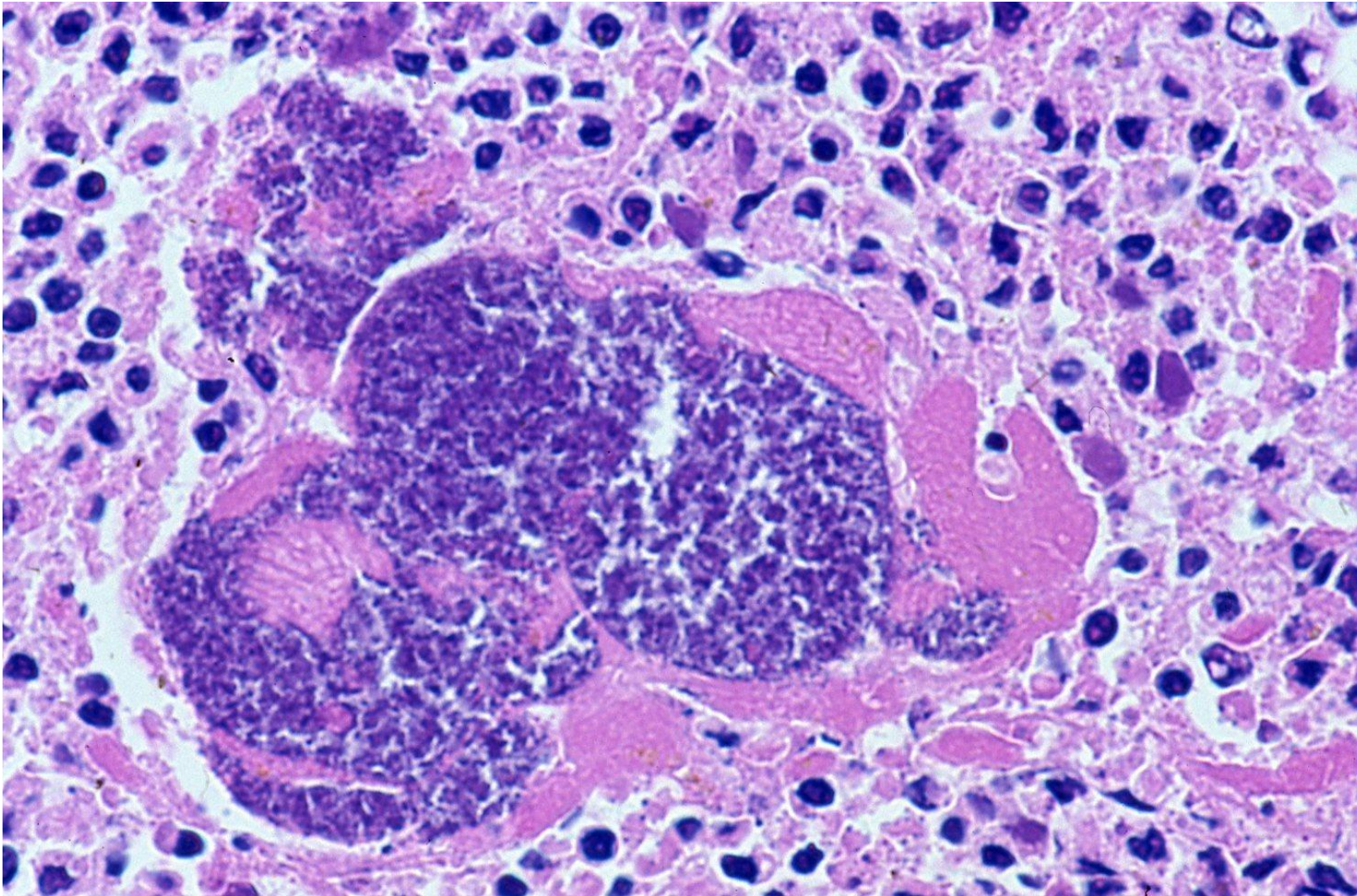
No. 45: Healthy carrier of HBs antigen (H&E). The cytoplasm of the hepatocytes shows ground-glass appearance, representing a non-replicative carrier. Hepatic function is normal and no inflammatory reaction is observed in the liver. The presence of HBs antigen is proven with Orcein stain (right top) and immunostaining for HBs antigen (right bottom).



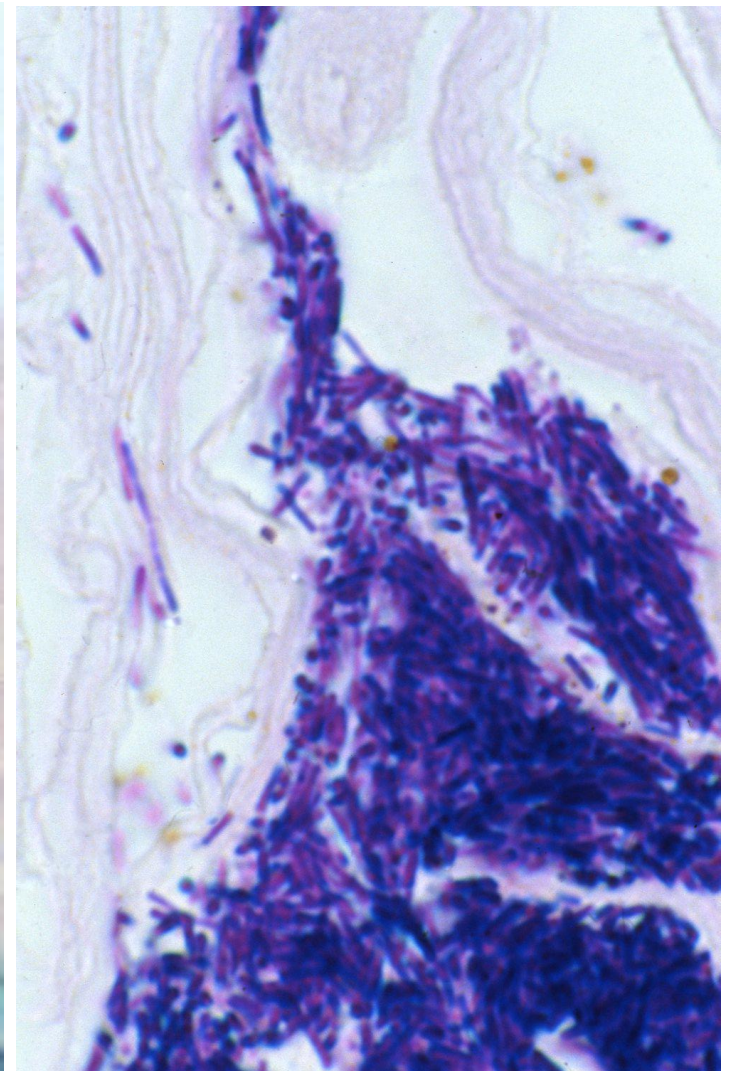
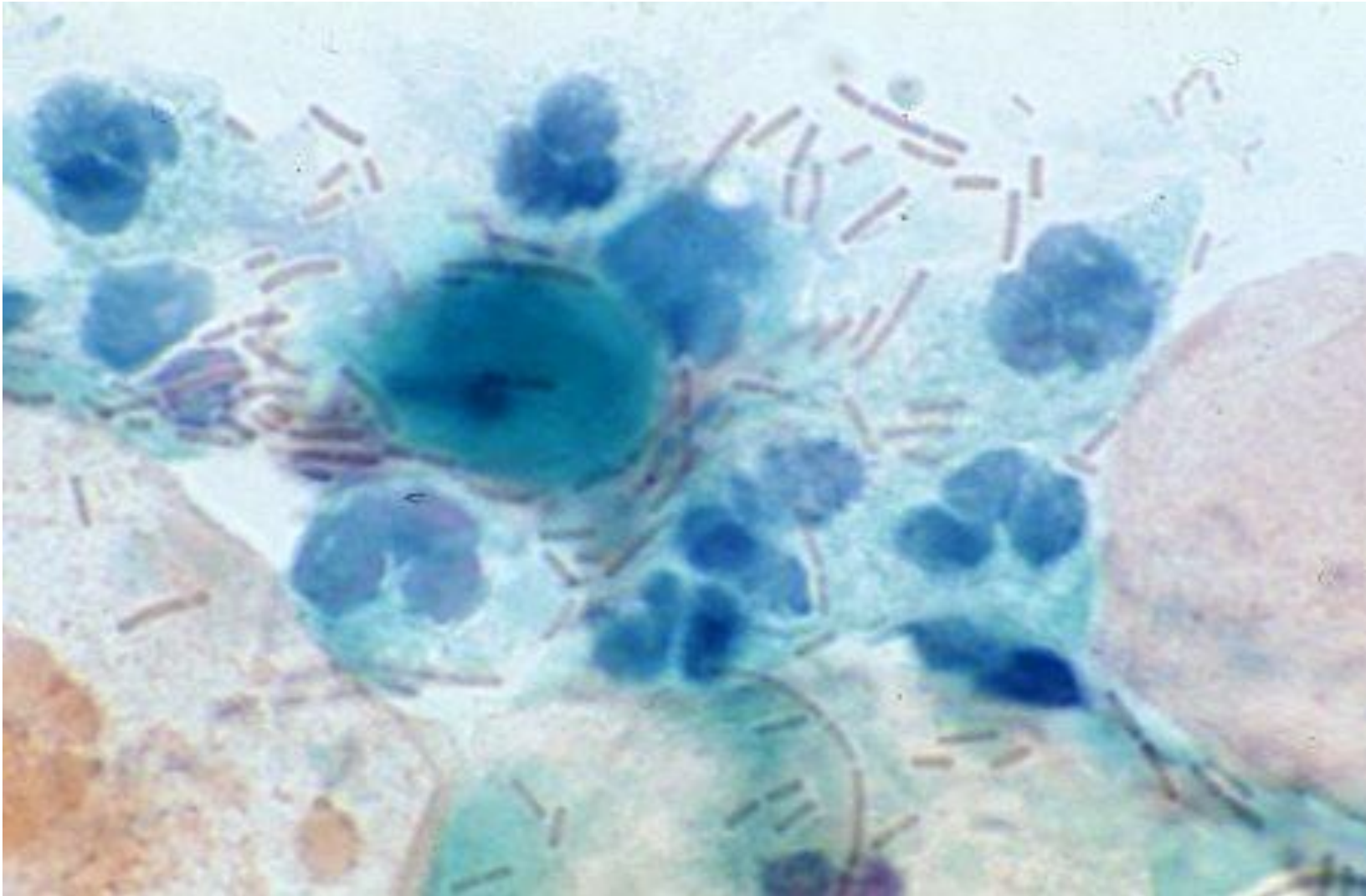
No. 46: Intestinal spirochetosis (H&E). The surface of the colonic mucosa is diffusely covered with feathery basophilic structures. Right: The abnormal structures are immunoreactive with a monoclonal antibody against *Treponema pallidum*, representing the infection of *Brachyspira aalborgi*. The infection is often asymptomatic, and may be associated with AIDS.



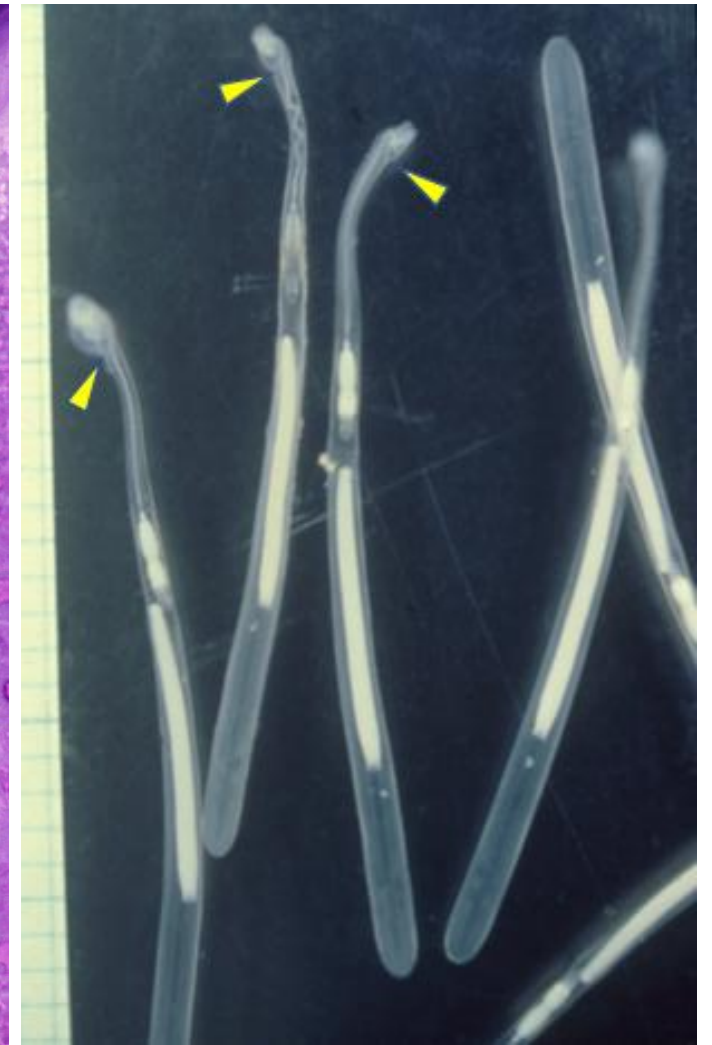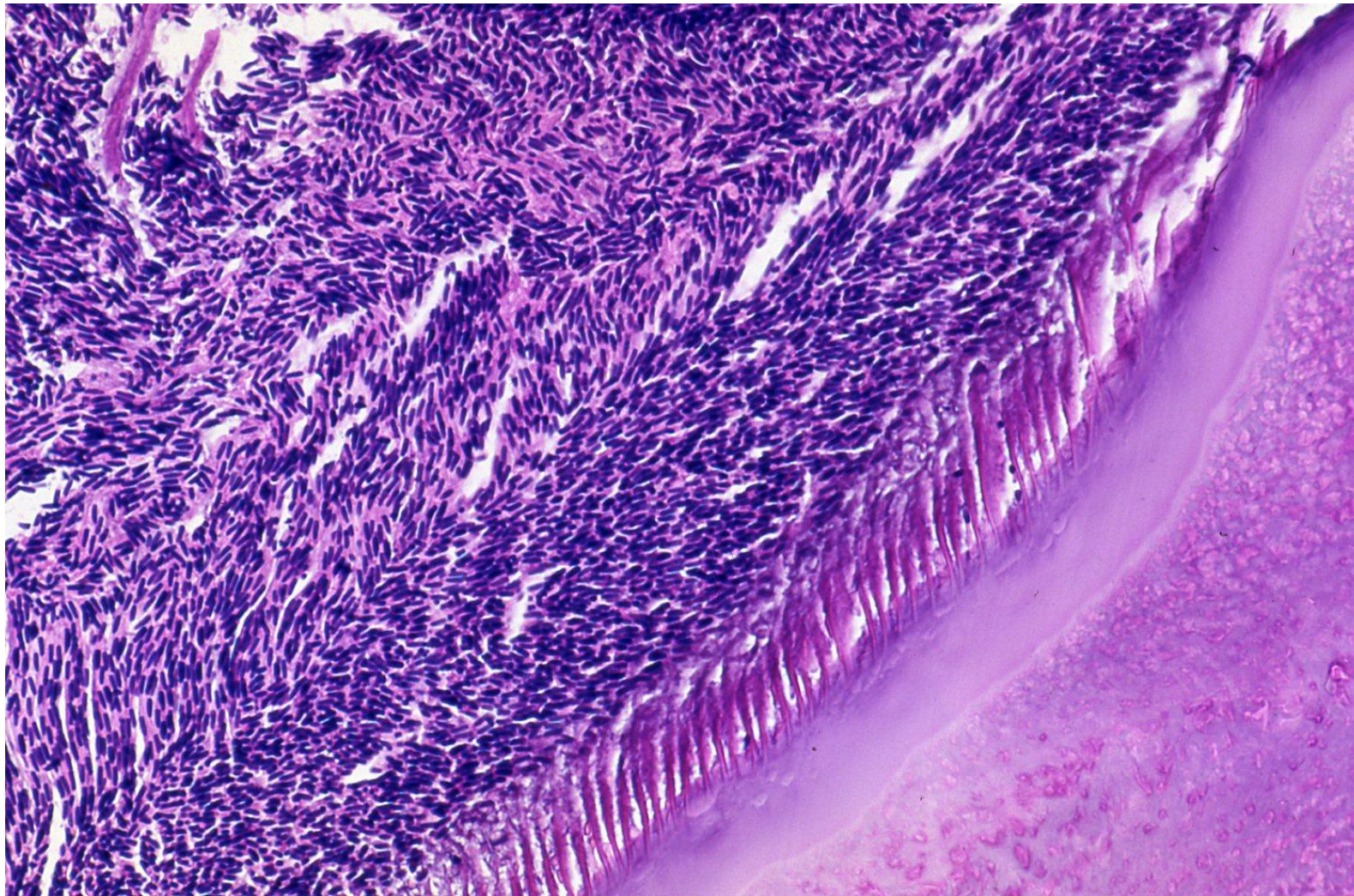
No. 47: Whipple's disease (PAS reaction). Duodenal biopsy reveals marked accumulation of PAS-reactive macrophages in the lamina propria mucosae. Fat droplets are also scattered in the lesion. Whipple's disease is a chronic infection of *Tropheryma whipplei*, causing persistent diarrhea, abdominal pain and weight loss. Right: Ultrastructurally, thick-walled bacilli are seen both inside and outside of the infiltrating macrophages.



No. 48: Methicillin-resistant *Staphylococcus aureus* (MRSA) septicemia-induced microabscess in the heart (H&E). MRSA is a notorious pathogen of hospital-acquired infection. Septicemic spread of MRSA causes microabscesses in various organs and bacterial endocarditis. The coccal colony is densely surrounded by neutrophils. Right: MRSA-induced purulent lymphadenitis in a domestic cat (H&E). MRSA colonies are arrowed. Of note is that the owner of the cat is often a medical personnel.



No. 49: Döderlein bacilli in the cervical cytology (Papanicolaou). Döderlein bacilli are physiological residents in the vaginal lumen, maintaining the acidity of the vaginal mucosa by producing lactic acid. Right: Squams excreted from a pregnant lady (Gram). Döderlein bacilli, clustered on the keratinocytes, are Gram-positive bacilli categorized in *Lactobacillus*. Döderlein bacilli disappear after menopause or when vaginitis happens.



No. 50: Tongue insertion of the **sperm bag of the squid** (H&E). A middle-aged man ate Sashimi of raw squid bought from the market place for supper. A white material was stuck into the tongue. The removed material consists of numbers of sperms in the capsule. The diagnosis should be incidental insertion of **spermatophore** (sperm bag) of the squid. Right: Gross appearance of spermatophores, 2 cm in length. They contain white-colored sperm clusters. Actin filaments are condensed at the basal part of the sperm bag (arrowheads), functioning as a firing machine on touch stimulation. In the present case, the sperm bag was stuck into the tongue, instead of insertion into the insided body wall of the female squid.