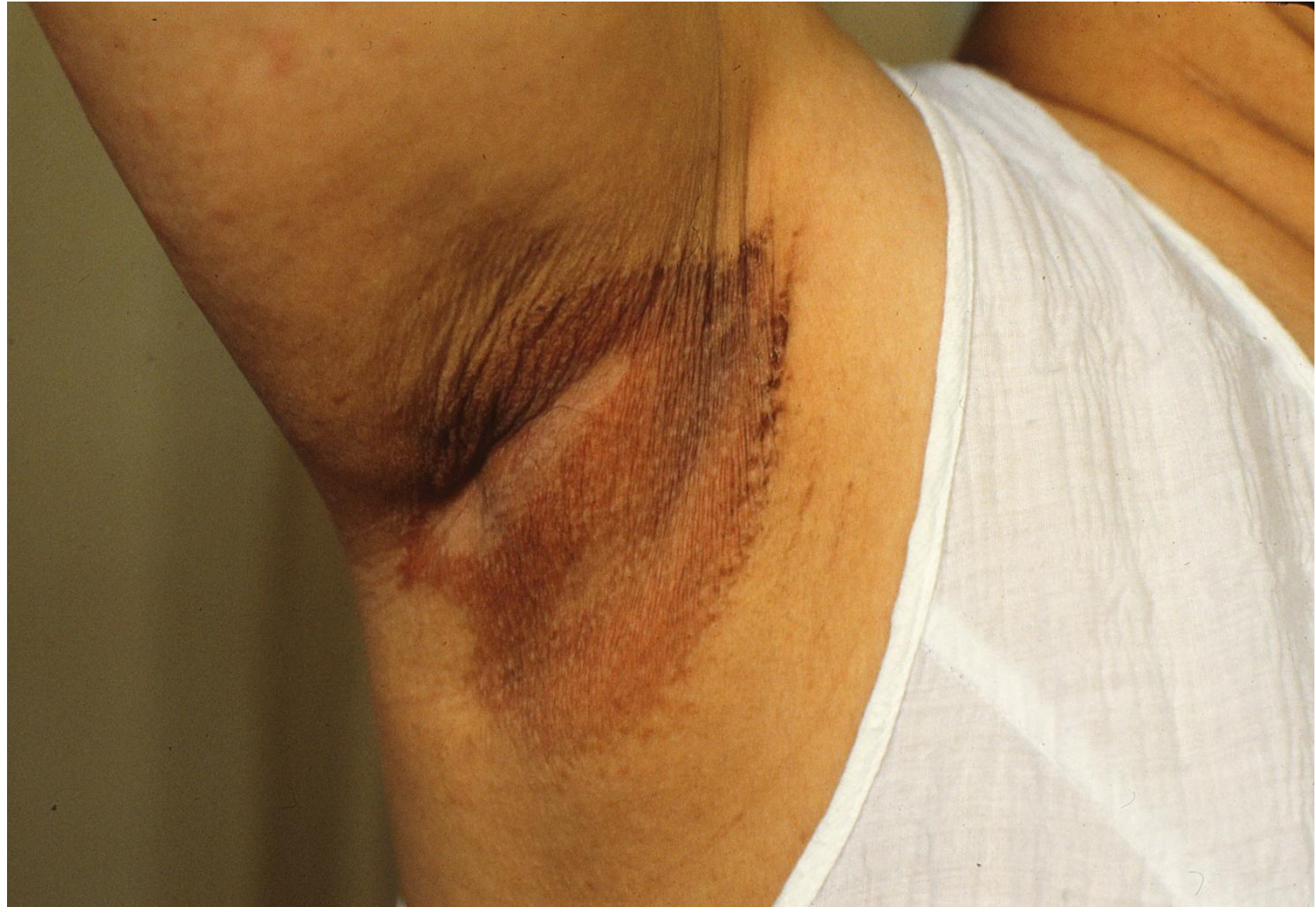

Corynebacterial skin infections

Bacterial skin infections caused by corynebacteria (diphtheroid bacteria) include erythrasma, pitted keratolysis and trichomycosis.

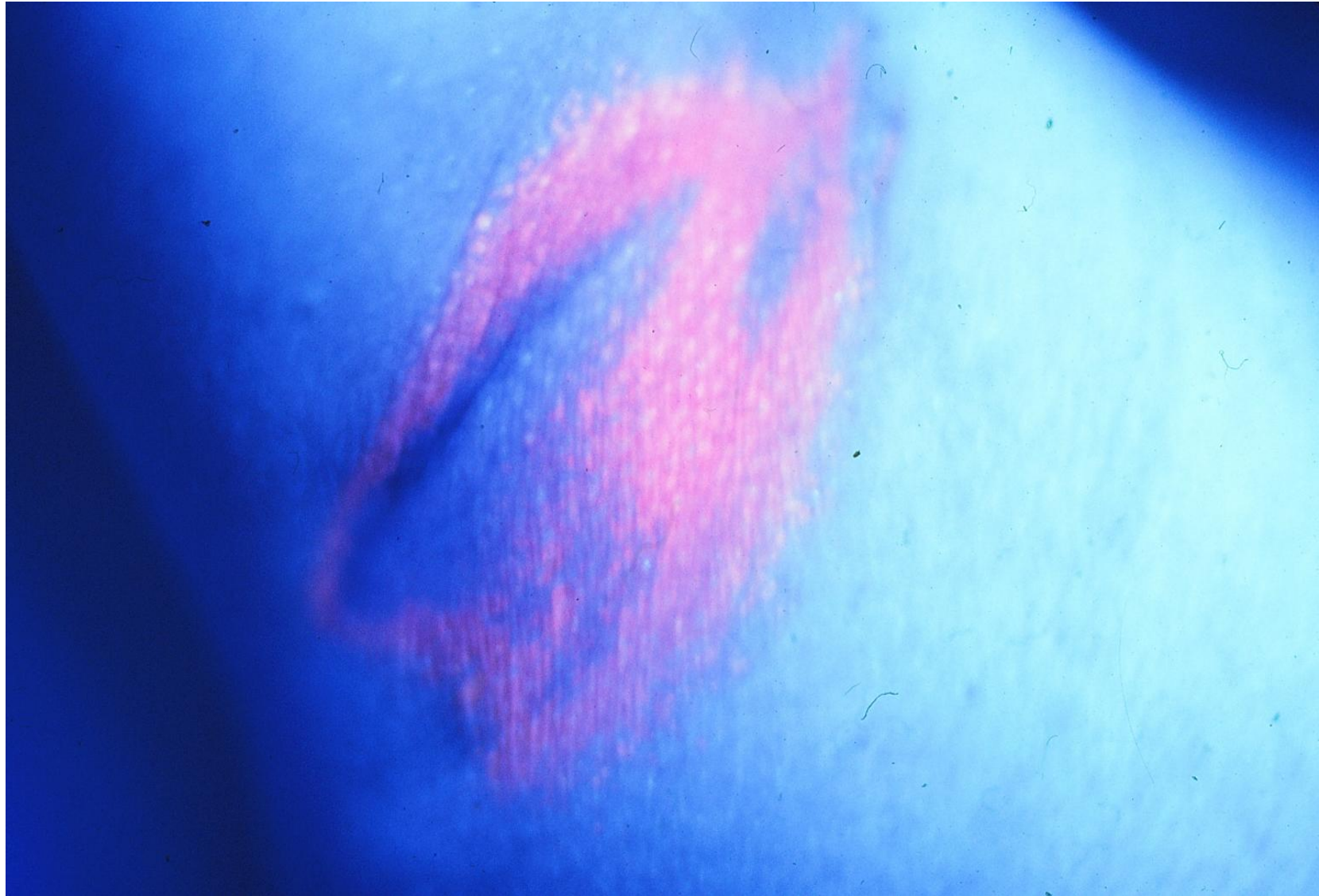Erythrasma (*Corynebacterium minutissimum* skin infection) presents as well-defined pink or brown patches with fine scaling and superficial fissures in the armpit. Mild itching may be present. Pitted keratolysis (keratolysis plantare sulcatum or ringed keratolysis) is superficial corynebacterial skin infection, characterized by crater-like pits, hyperhidrosis and malodor (unpleasant smell). It typically affects pressure-bearing areas on the sole, particularly in young male patients wearing protective shoes for professional reasons, inducing a moist and warm environment. Trichomycosis axillaris is superficial corynebacterial infection of underarm hair. The disease is characterized by concretions sticking to the hair shaft.

Corynebacterial skin
infection-I
Erythrasma-1



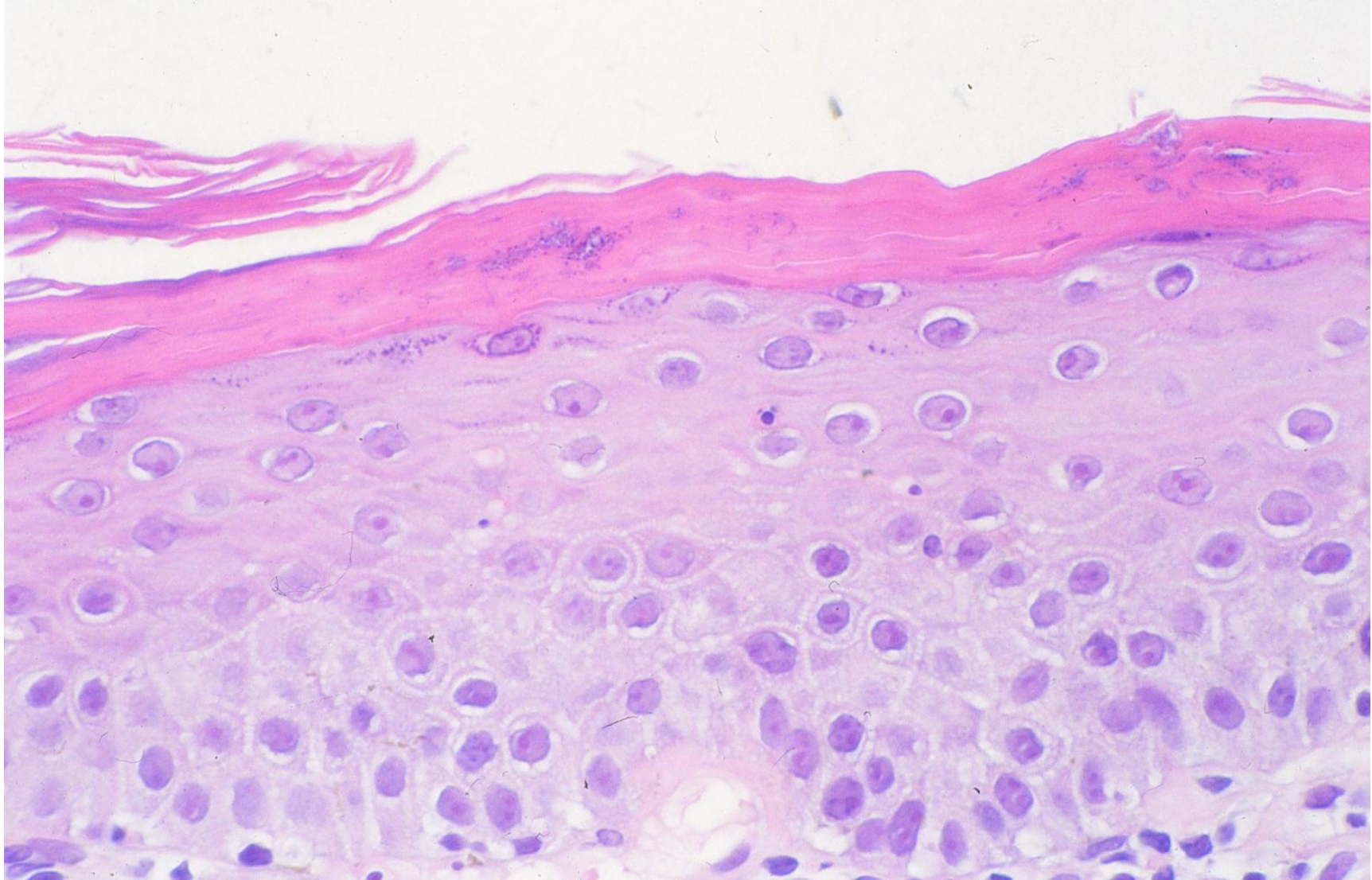
Erythrasma in the armpit (adult male): *Corynebacterium minutissimum* skin infection. Erythrasma presents as well-defined pink or brown patches with fine scaling and superficial fissures. Mild itching may be present.

Corynebacterial skin
infection-1
Erythrasma-2



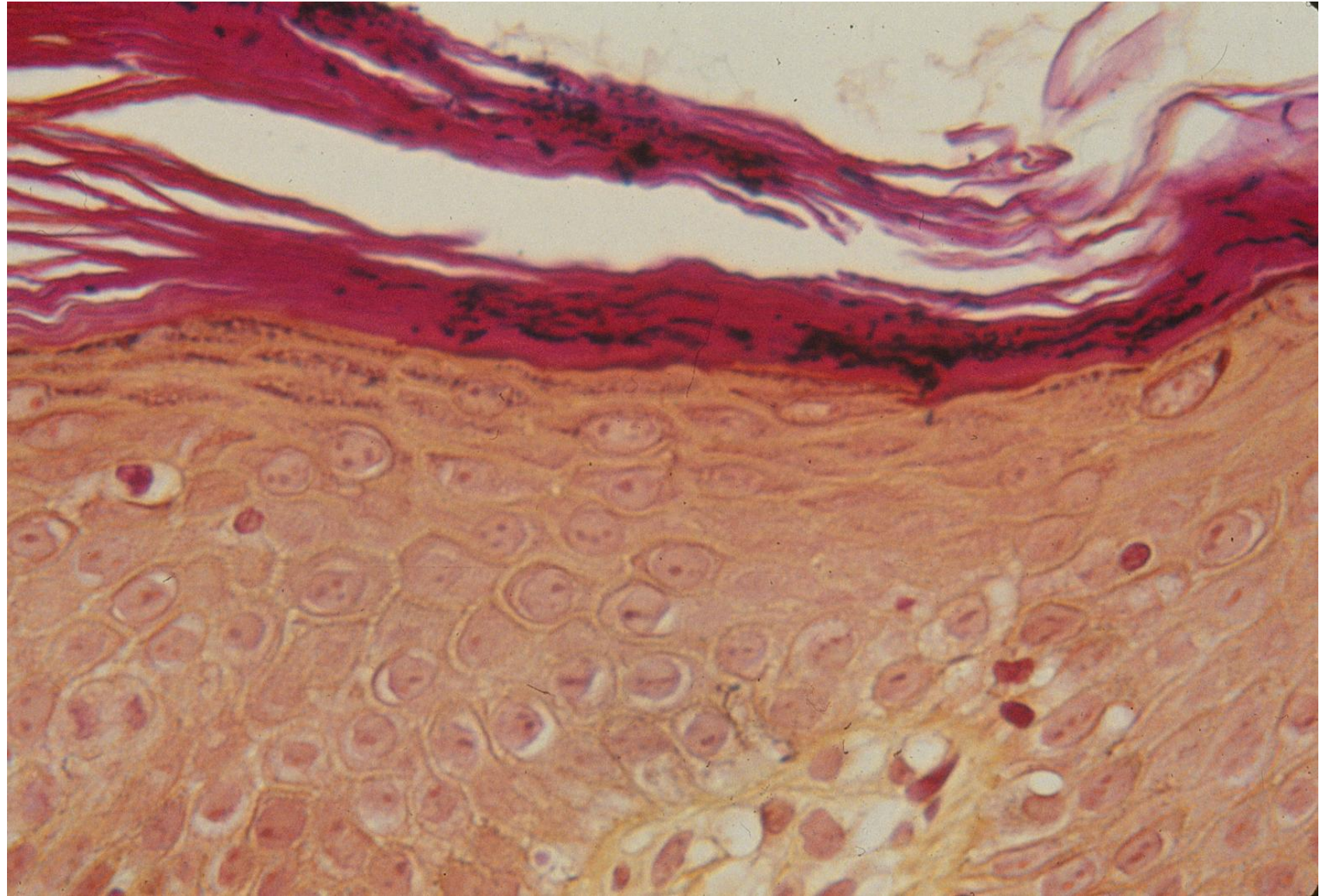
Erythrasma in the armpit (adult male): *Corynebacterium minutissimum* skin infection. With Wood lamp examination, long wavelength ultraviolet radiation causes erythrasma to fluoresce a coral-pink color due to coproporphyrin III released by the bacteria.

Corynebacterial skin
infection-I
Erythrasma-3



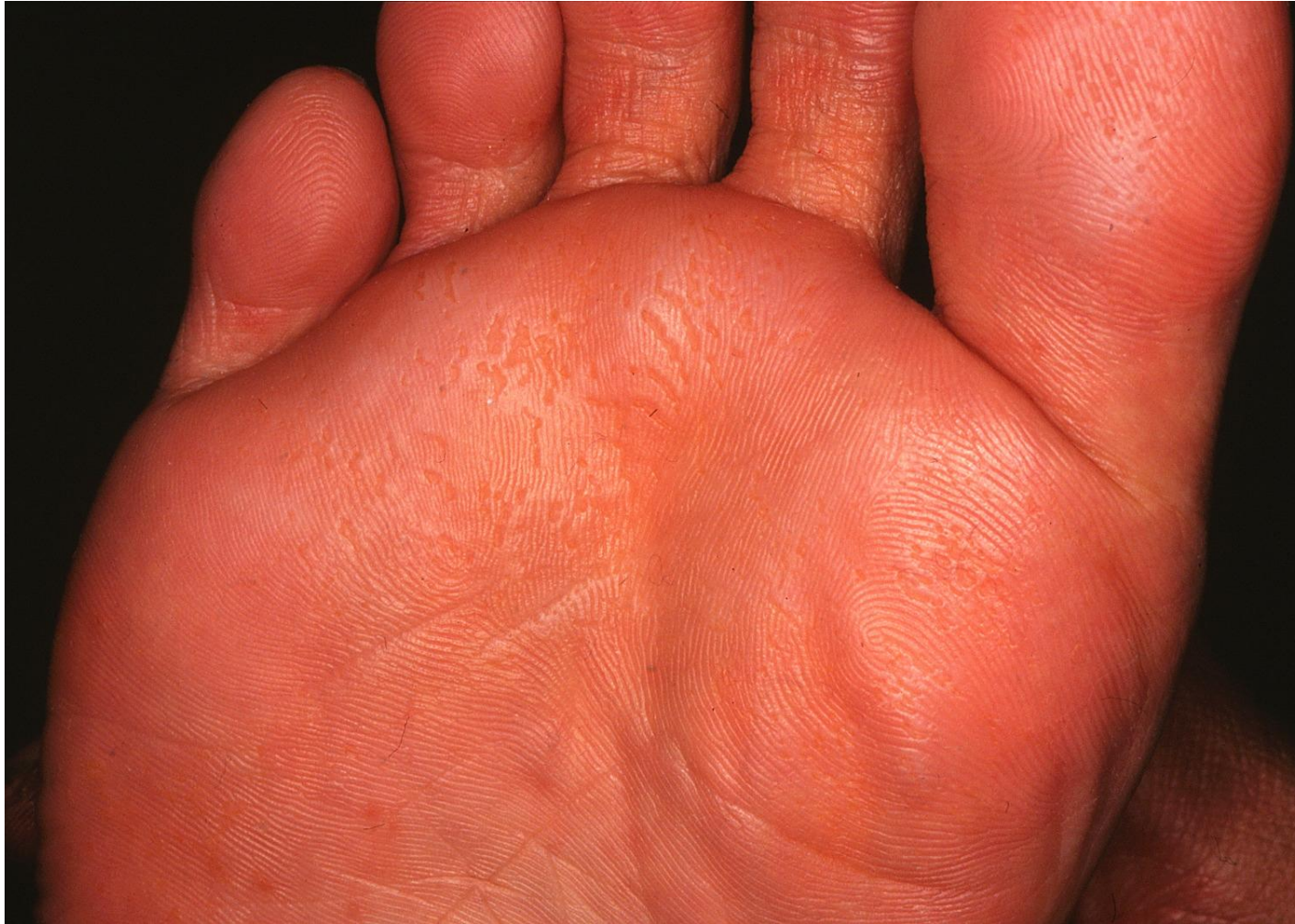Erythrasma in the armpit (adult male, HE): *Corynebacterium minutissimum* skin infection
Small rods are colonized in the hyperkeratotic cornified layer.

Corynebacterial skin
infection-I
Erythrasma-4



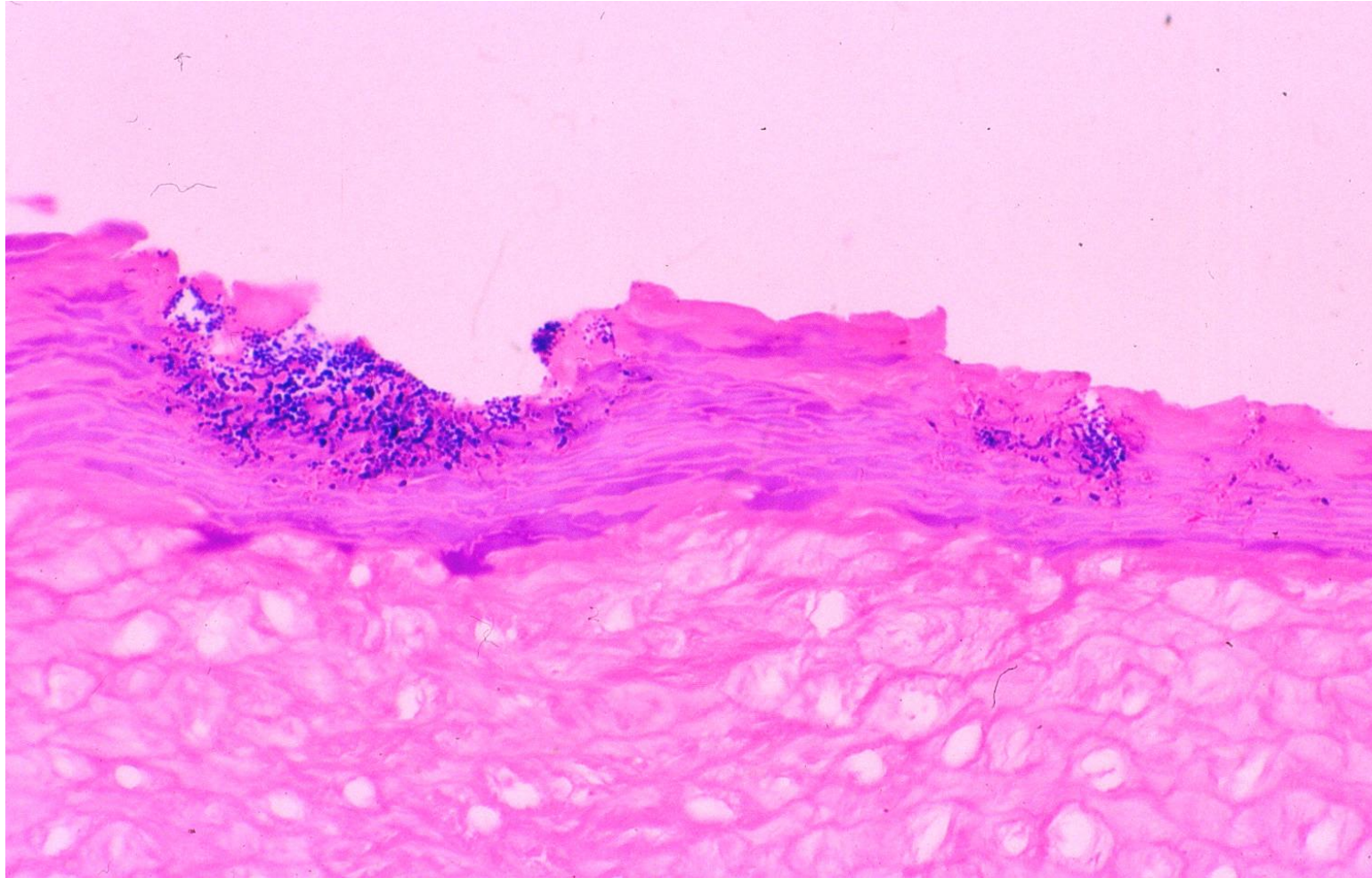
Erythrasma in the armpit (adult male, Gram): *Corynebacterium minutissimum* skin infection
Small rods in the hyperkeratotic cornified layer are Gram-positive.

Corynebacterial
skin infection-II
Pitted keratolysis-1



Pitted keratolysis (keratolysis plantare sulcatum or ringed keratolysis) (young adult M): Pitted keratolysis is superficial corynebacterial skin infection, characterized by crater-like pits, hyperhidrosis and malodor (unpleasant smell). It typically affects pressure-bearing areas on the sole, particularly in young male patients wearing protective shoes for professional reasons, inducing a moist and warm environment.

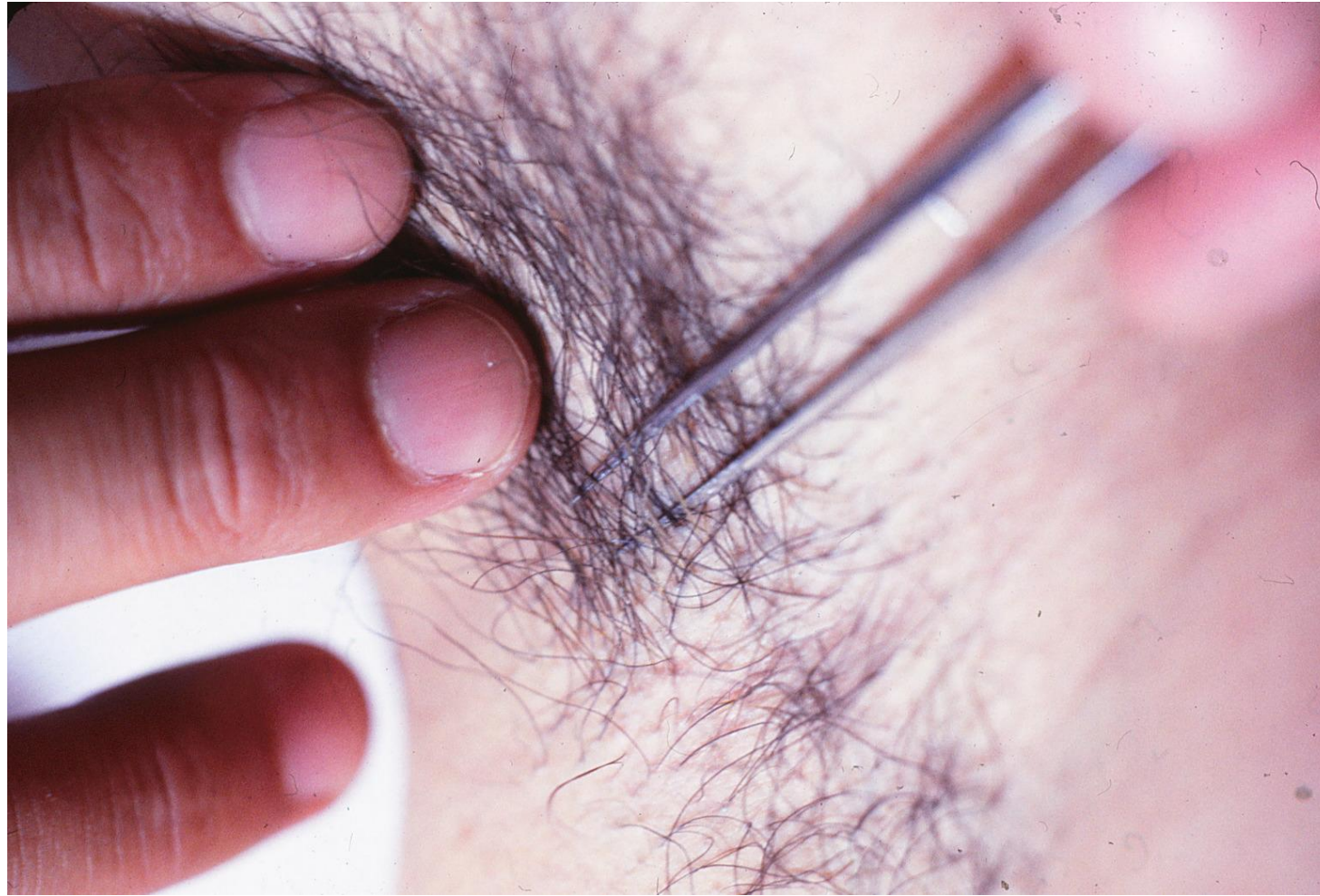
Corynebacterial
skin infection-II
Pitted keratolysis-2



Pitted keratolysis (Gram stain):


Pits are formed in the cornified layer. Gram stain visualizes Gram-positive coccoid or Filamentous bacilli in the eroded (pitted) cornified layer.

Corynebacterial skin
infection-III
Trichomycosis axillaris-1



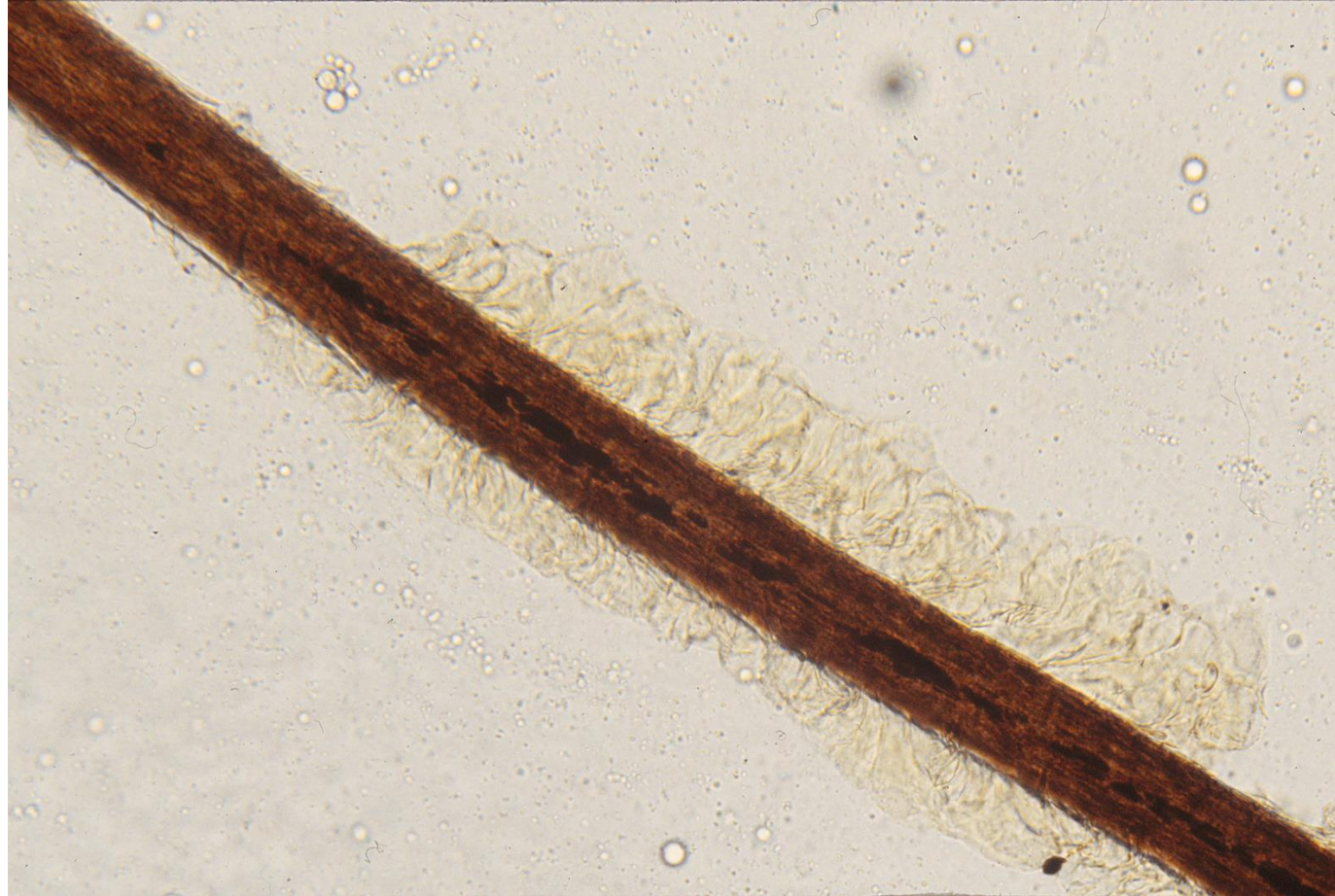Trichomycosis axillaris:
Trichomycosis axillaris is superficial corynebacterial infection of underarm hair. The disease is characterized by concretions sticking to the hair shaft.

Corynebacterial skin
infection-III
Trichomycosis axillaris-2



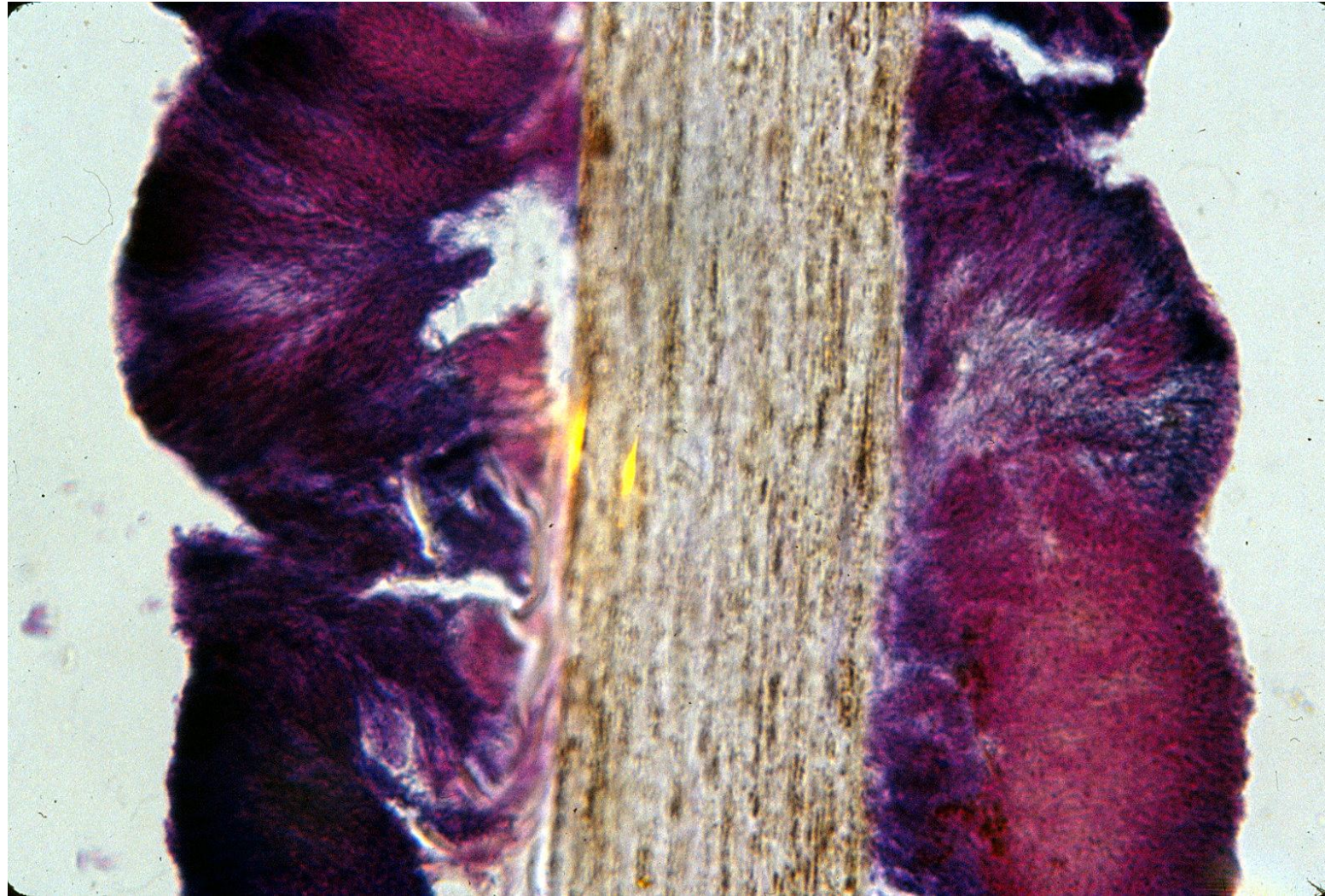
Trichomycosis axillaris:
Wood lamp examination shows pale-yellow fluorescence on the axillary hair.

Corynebacterial skin
infection-III
Trichomycosis axillaris-3



Trichomycosis axillaris:
Scanning microscopy identifies long rods colonizing the surface of the axillary hair,
forming a concretion.

Corynebacterial skin
infection-III
Trichomycosis axillaris-4



Trichomycosis axillaris:

Gram staining visualizes the concretion where long rods colonize the surface of the axillary hair. *Corynebacterium tenuis*, *C. propinquum* or *C. flavescentes* are the causative bacteria. *Serratia marcescens* may also be a pathogen.