

Norwegian scabies (crusted scabies)

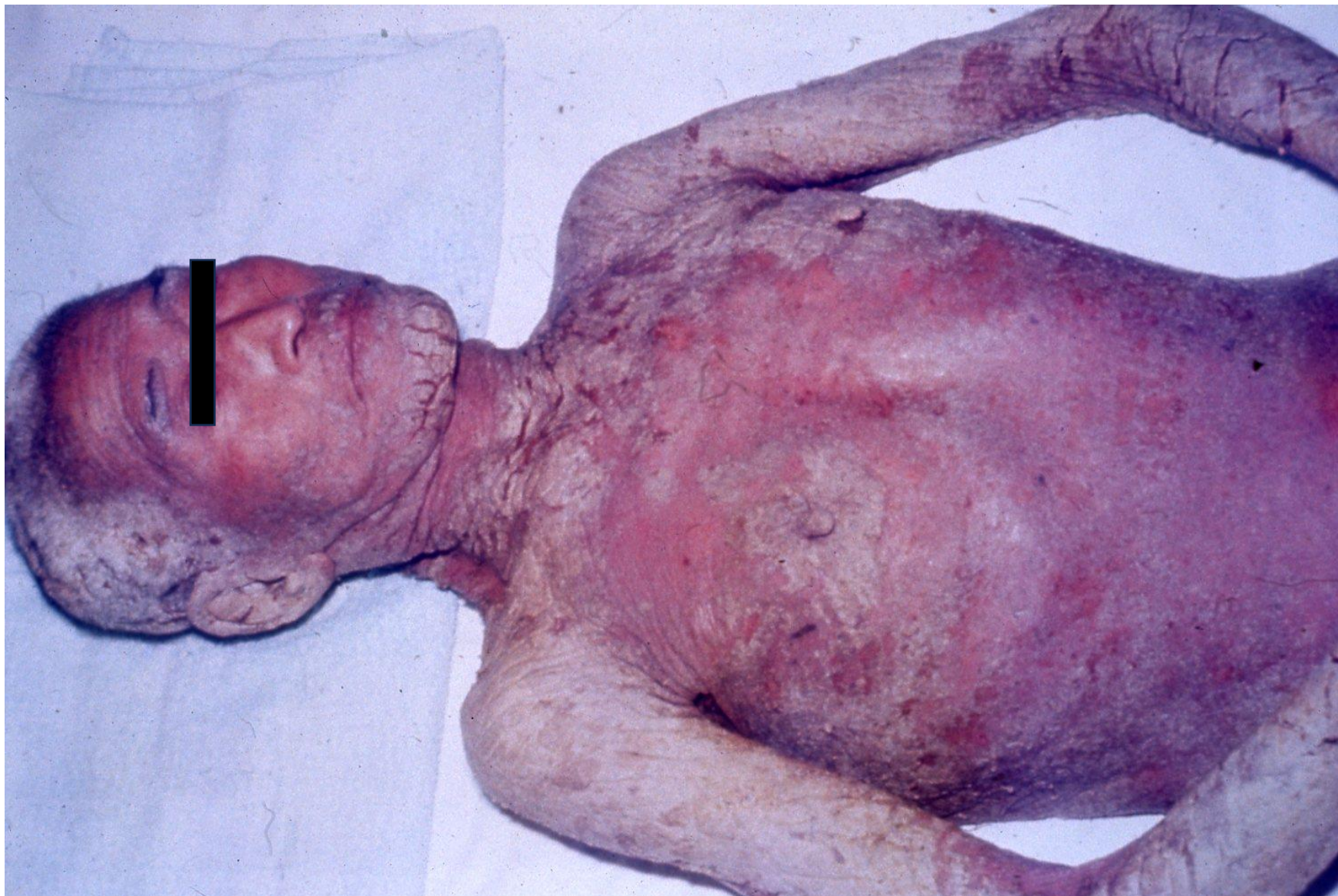Scabies is a contagious skin infestation by the mite *Sarcoptes scabiei*. The most common symptoms are severe itchiness and pimple-like rash. Tiny burrows (mite burrows) may appear on the skin.

The elderly, disabled and people with impaired immune systems, such as those with HIV/AIDS or those on immunosuppressive medications, are susceptible to Norwegian scabies (crusted scabies). The mites spread over the host's body, except the face. Norwegian scabies reveals scaly rashes, slight itching and thick crusts of skin containing numerous scabies mites. Norwegian scabies is thus very contagious to cause nosocomial infection.

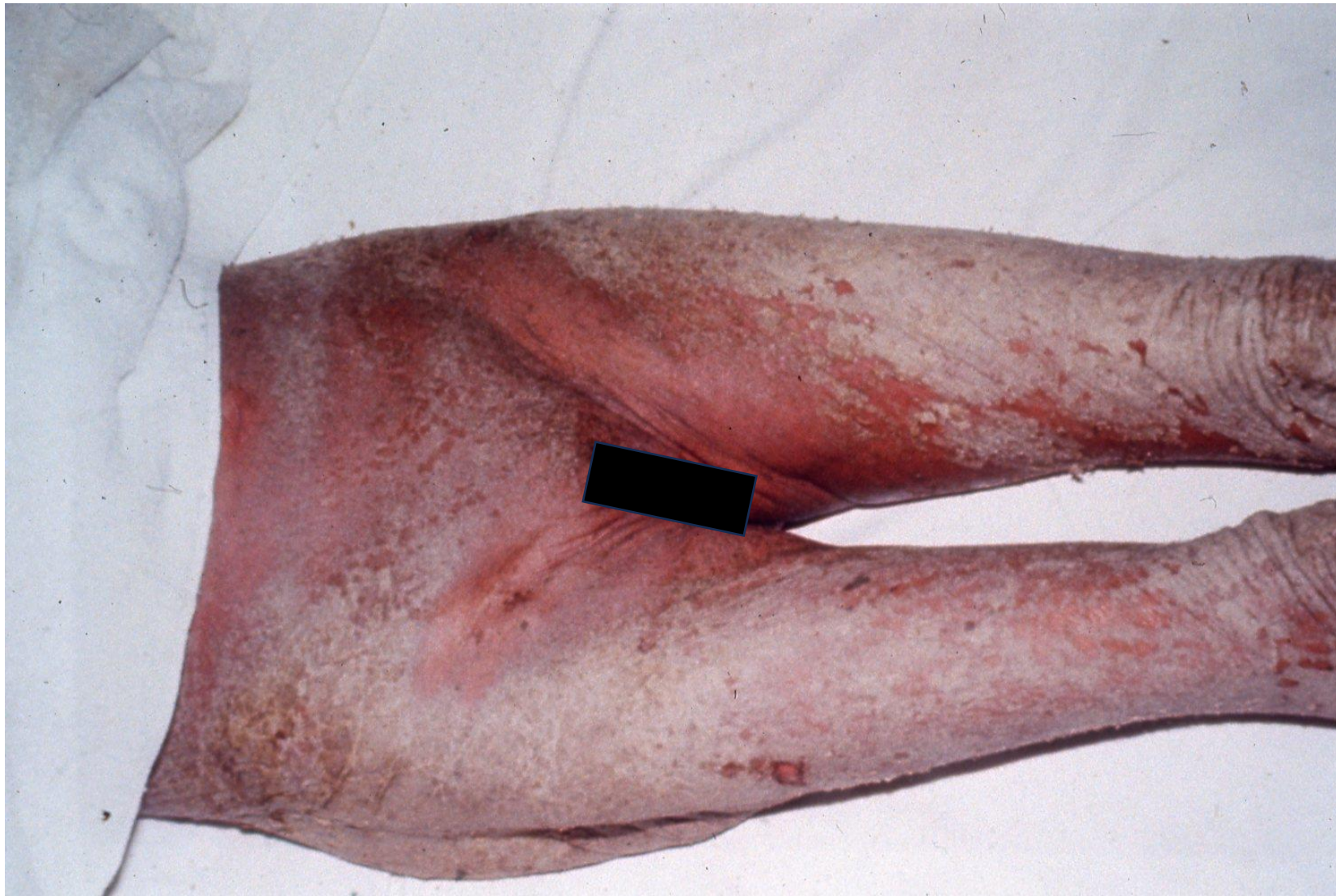Case presentation: Norwegian scabies (79F)

A 79-year-old female farmer had skin eruptions on her hands and head for years. The eruptions became spread on the arms and chin, and general erythroderma followed. Because of dehydration state, she became unable to walk to be hospitalized.

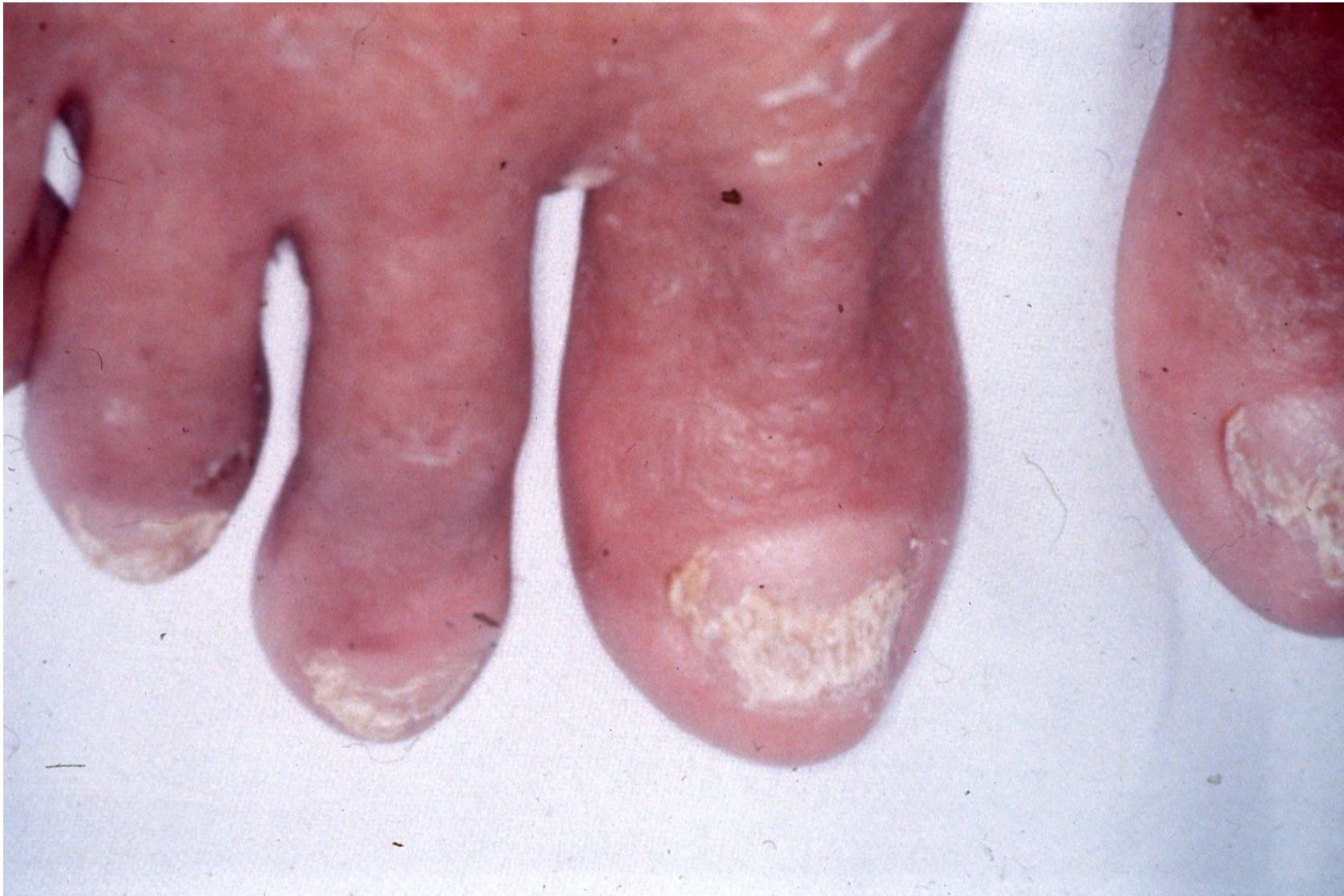The dermatological diagnosis of crusted or Norwegian scabies was delayed for several days, principally because of the rarity of the disease. Nosocomial infection occurred. Plural residents and nurses were infected with the mites.



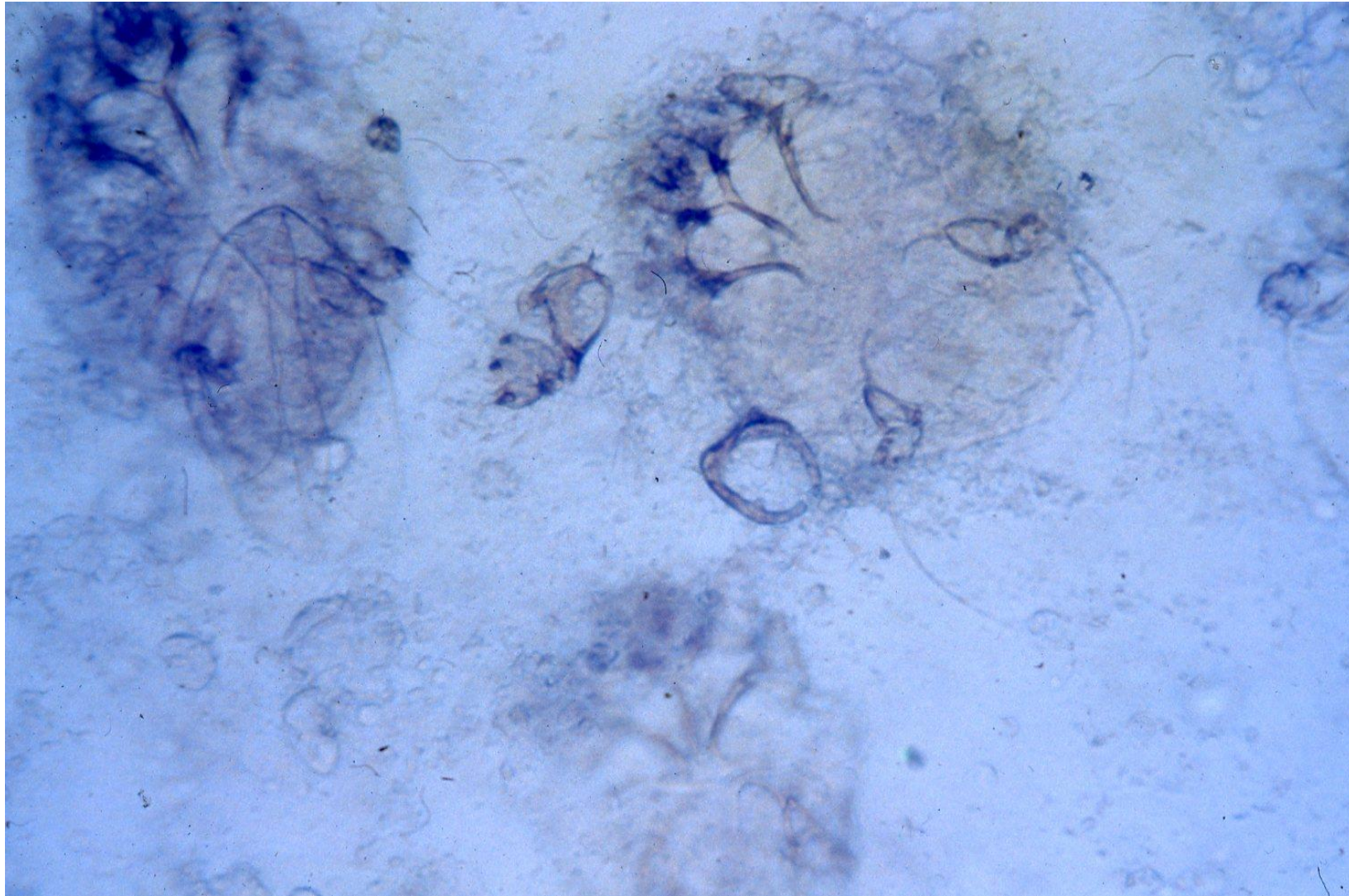
Gross appearance of the upper body of the female farmer with crusted scabies. Skin encrustation is extensive.



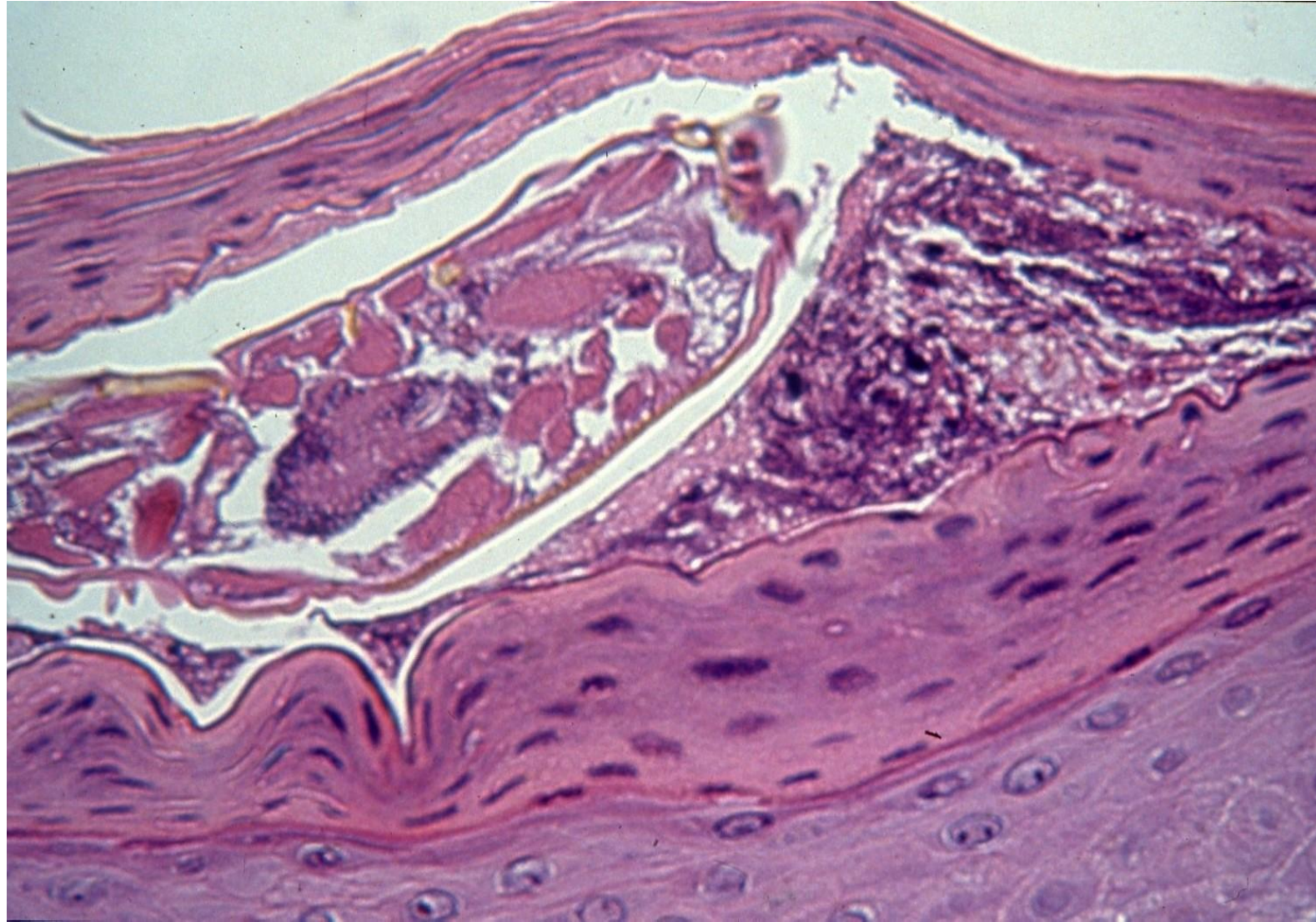
Gross appearance of the lower body of the female farmer with crusted scabies. Skin encrustation is extensive.



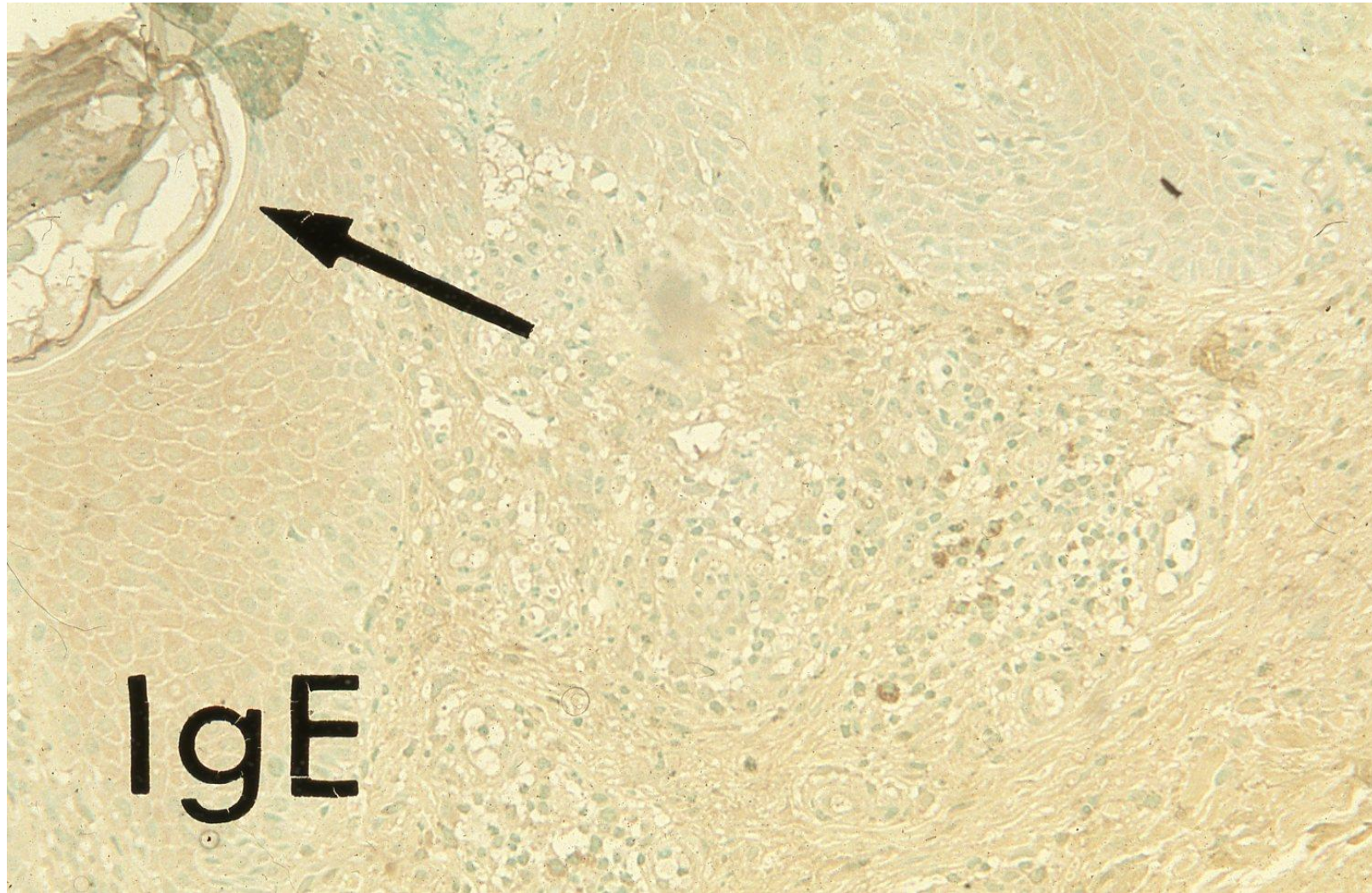
Gross appearance of the toes of the female farmer with crusted scabies. Mites collect in nail beds, causing irregular nail thickening.



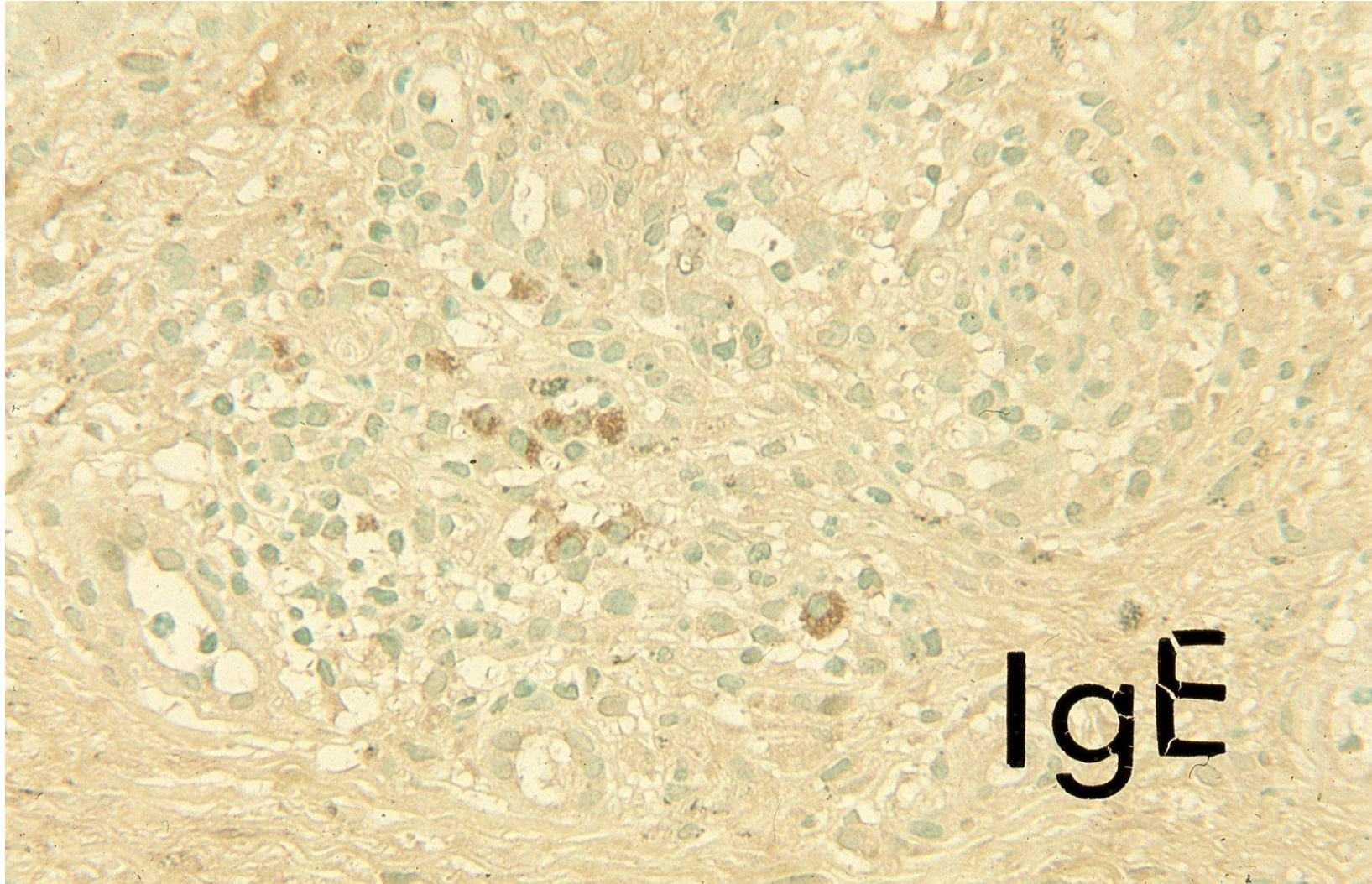
Skin scraping preparation reveals numerous adult mites under a microscope.



Skin biopsy from the crusted skin reveals a cut surface of the mite in the hyperparakeratotic layer of the epidermis. H&E



Immunostaining for IgE for the skin biopsy specimen. IgE is demonstrated on the mite body (arrow). IgG, IgA, IgM and IgD are unreactive. Allergic reaction to the mite Ag is indicated. Immunostaining for IgE



Immunostaining for IgE in the skin biopsy specimen. IgE-type plasma cells are scattered in the dermis with crusted scabies. Serum IgE level was significantly elevated to 6,400 IU/mL (normal range <170 IU/mL). Immunostaining for IgE